10th World Veterinary Dental Congress

Guarujá, SP, Brazil
April 25-27, 2007

www.wvdc2007.com.br

Contributions presented at the Congress

Pesquisa Veterinária Brasileira 27(Supl.) 2007,
a Brazilian Journal of Veterinary Research

10th WVDC and 2nd Brazilian Veterinary Dental Congress (COBOV), hosted by ABOV

ORGANIZING COMMITTEE
President: Marco A. Gioso
Secretary: Claudia Youle
President of Scientific Committee: Michèle Venturini
Treasurer: Herbert Corrêa
Travel and Social Programme Coordinator: Vanessa Carvalho

Representatives
North America: Colin Harvey, Steve Holmstrom, Bob Wiggs
Europe: Cecilia Gorrel, Margherita Gracis, Phillipe Hennet, Fidel San Roman, Alex Reiter
Asia and Australia: David Clarke, Ayako Okuda
Scientific Committee: Daniel Ferro, Rogério A. Miranda, Mariana Ramos, Marcos Nogueira, Jussara Zani Maia, Paulo Juliani, Marcello Roza, José Ricardo Pachaly, Moacir dos Santos Lacerda, Léslie Domingues Falqueiro, Vanessa Carvalho
Auxiliary Committee: Luiz Cláudio Sofal, Mariana Lage Marques, Marco Antonio Leon Roman, Juliana Kowalesky, Fernanda Leirião Riva, Cristina Albuquerque, João L. Rossi Jr, Carla Omura, Maria Izabel R. Valduga

Papers and Posters presented at the

10th World Veterinary Dental Congress

Guarujá, SP, Brazil
April 25-27, 2007

www.wvdc2007.com.br

Pesquisa Veterinária Brasileira 27(Supl.) 2007,
on Compact Disc

Papers presented at the

10th World Veterinary Dental Congress

001. Amasaki H.[1], Amasaki T.[2], Ichihara N.[2], Tsukamoto A.[2], Nishita T.[3], Murakami M.[4] & Asari M.[2] 2007. **Detection of mRNA RT-PCR signals of Type 6 Carbonic Anhydrase Isozymes in striated ducts of canine salivary glands using Laser-Microdissection (LMD) System.** *Pesquisa Veterinária Brasileira 27 (Supl.).* [1]Laboratories of Veterinary Anatomy, Nippon Veterinary Life Sience University, 1-7-1 Kyonan-cho, Musashino-shi, 182-8602, Japan; [2]Laboratories of Anatomy I; [3]Physiology I; [4]Molecular Biology, Azabu University School of Veterinary Medicine, Fuchinobe 1-17-71, Sagamihara, Kanagawa, 229-8501, Japan. E-mail: hamasaki@nvlu.ac.jp

Introduction: Carbonic anhydrase (CA) 6 is the secretion form isozyme, and firstly found in the sheep saliva. CA6 is mainly thought to enhance buffering capacity of oral cavity and might be involved in regulation of salivary pH and in protection of upper alimentary canal against excess acidity. It is known that CA6 is secreted by acinar serous cells of parotid gland and serous demilune cells of submandibular gland in many mammals (Kivela et al. 1999, Kaseda et al. 2006). Moreover, in situ hybridization technique showed that CA6 mRNA was described to express in only serous acinar cells of the sheep parotid and submandibular glands (Murakami et al. 2003). However, previous our immunohistolocal study in the canine salivary gland indicates that CA6 was detected in serous acinar cells and some striated duct cells (Asari et al. 2007). Secretory ability of CA6 of striated duct cells in canine salivary glands has never been unclear. Present study examined protein level synthesize ability of CA6 and mRNA expression ability of CA6 in serous acinar cells and striated duct cells using of the laser microdissection method (LMD) and RT-PCR for a limited harvest and detection of mRNA.

Materials and Methods: Anti-canine CA6 antibody was arisen from our original purified canine CA6 isozyme for the protein level histological detection (Asari et al. 2007). Parotid and submandibular glands were obtained from three adult male beagles under anesthesia for the immunohistochemistry. Seven ìm cryo-sections of salivary gland were made and mounted on glass slides covered with PEN foil for the microdissection system (Leica Laser Microdissection System, Leica Microsystems). The mRNA of CA6 was analyzed by RT-PCR method routinely.

Results: Canine CA6 strongly reacted to serous acinar cells of parotid gland (Fig.1) and serous demilune of submandibular gland, while weak immuno-reactions were seen in striated duct cells in ductal regions of parotid (Fig.1) and submandibular glands. Total RNA extracted from tissue samples harvested by LMD was then subjected to RT-PCR, and agarose electrophoresis of RT-PCR products showed the target band at 441 bp for serous acinar cells, striated duct cells of parotid gland, and serous demilune, striated duct cells of submandibular gland. The band was the strongest for serous acinar cells of parotid gland. The band for striated duct cells of parotid and submandibular glands was weaker than that for acinar cells, but was very well defined (Fig.2).

Discussion: CA in serous acinar and ductal epithelial cells is involved with saliva formation. Mucous acinar cells were not found to be reactive for any cytosolic CA (Asari et al. 2000b). In many mammals, including humans, secretory CA6 in mainly salivary gland is detected in acinar cells (Fernley et al. 1979, Kadoya et al. 1987, Ogawa et al. 1990, Parkkila et al. 1990, Ogawa et al. 1993, Parkkila et al. 1997) suggesting that CA6 present in whole saliva. When CA6 is secreted from cells in the lumen, it may mix with water that is passively transported into the lumen through transportation of Na+ and Cl- into the lumen, and it then flows inside the excretory duct towards the oral cavity. Immunohistochemical studies have shown that ductal contents exhibit strong reactions to CA6 antibody (Kadoya et al.1987, Parkkila et al.1990, Ogawa

et al.1993). Immunohistochemical studies investigating the localization of cytosolic CA1, CA2 and CA3, and secretory CA6 in salivary glands have clarified the differences in localization among animal species and salivary glands. These studies show that cytosolic CA isozymes are present in either acinar or ductal epithelial cells, while CA6 isozymes are found in acinar cells of the parotid gland and serous demilune of the submandibular gland. For example, in the bovine parotid gland, serous acinar cells contain highly active cytosolic and secretory CA2 and CA6, but striated duct cells only contain CA2 not CA6 (Asari et al. 2000a). This is also true in rats and humans. In rat or human parotid glands, while serous acinar cells contain CA6 striated duct cells only contain cytosolic CA1 and CA2 (Kadoya et al. 1987, Parkkila et al. 1990). However, a recent immunohistochemical study on the localization of secretory CA6 in the canine parotid gland found that, although much weaker, reactions were also seen in striated duct cells (Asari et al. 2007). Secretory CA6 protein in canine ductal epithelia detected by immunohistochemical analysis might have been CA6 originating from serous acinar cells, subsequently absorbed by ductal epithelial cells during the process of saliva formation. The reaction could also have been nonspecific or could have represented artificial products formed during the process of sample preparation. Present study was conducted to determine secretory CA6 in the canine salivary gland and ductal epithelia. In order to clarify this point, LMD were used to harvest target tissues. In other words, serous acinar cells and striated duct cells in parotid and submandibular glands were separately dissected, and the gene expression of CA6 in each cell type was closely investigated at the tissue level. Our results confirmed mRNA encoding CA6 in serous acinar cells and striated duct cells, and as a result, CA6 is synthesized in both cells in dogs. Present results confirmed mRNA encoding CA6 and anti canine CA6 antibody positive reactions in serous acinar cells and some striated duct cells. CA6 secreted by some canine striated ducts cells might have the role of saliva formation.

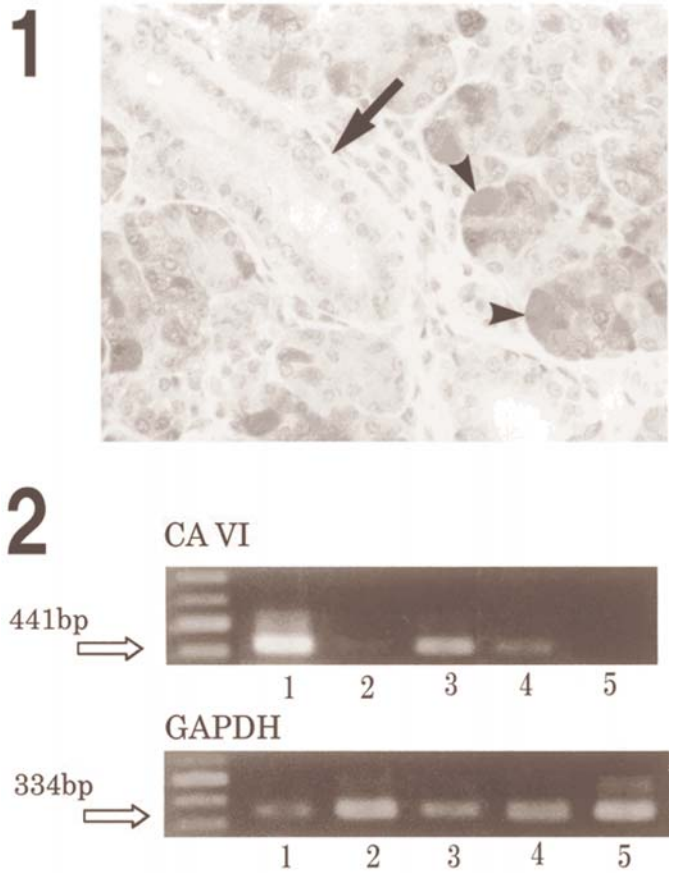

Fig.1. Serous acinar cells in the canine parotid gland. (arrow heads) and striated duct cells (arrow) show immuno-reactions for anti-CA6. The scale in figures is 100 ìm.

Fig.2. After the LMD, total RNA extracted from tissue samples was subjected to RT-PCR, and agarose electrophoresis of RT-PCR products showed the target band at 441 bp for serous acinar cells (Lane 1) and striated duct cells (Lane 2) of the parotid gland, serous demilune (Lane 3) and striated duct cells (Lane 4) of the submandibular gland. The band was strongest for the serous acinar cells of the parotid gland. The band for the striated duct cells of the parotid and submandibular glands was weaker than that for the acinar cells, but was well defined. Lane 5 was negative control; skeletal muscle. Furthermore, the internal standard (canine GAPDH: 334 bp) was amplified in all tissue samples.

References: Asari M., Kasuya T., Shibata S., Kaseda M., Ichihara N., Nishita T. & Murakami M. 2007. Immuno-histolocalization and gene expression of the secretory carbonic anhydrase isozymes (CA-VI) in canine oral mucosa, salivary glands and esophagus. Anat. Histol. Embryo (In publication). - Asari M., Kimura H., Ichihara N., Kasuya T. & Nishita T. 2000a. Immunohistochemistry of carbonic anhydrase isozymes (CA-I, II and III) in canine salivary glands: a distributional and comparative assessment. Anat. Histol. Embryo. 29:9-12. - Asari M., Miura K., Ichihara N., Nishita T. & Amasaki H. 2000b. Distribution of carbonic anhydrase isozyme VI in the developing bovine parotid gland. Cells Tissues Organs 167:18-24. - Fernley R.T., Wright R.D. & Coghlan J.P. 1979. A novel carbonic anhydrase from the ovine parotid gland. FEBS Lett. 105:299-302. - Kadoya Y., Kuwahara H., Shimazaki M., Ogawa Y. & Yagi T. 1987. Isolation of a novel carbonic anhydrase from human saliva and immunohistochemical demonstration of its related isozymes in salivary gland. Osaka City Med. J. 33:99-109. - Kaseda M., Ichihara N., Nishita T., Amasaki H. & Asari M. 2006. Immunohistochemistry of the bovine secretory carbonic anhydrase isozyme (CA-VI) in bovine alimentary canal and major salivary glands. J. Vet. Med. Sci. 68:131-135. - Kivela J., Parkkila S., Parkkila A.K., Leinonen J. & Rajaniemi H. 1999. Salivary carbonic anhydrase isoenzyme VI. J. Physiol. 520:315-320. - Murakami M., Kasuya T., Matsuba C. et al. 2003. Nucleotide sequence and expression of a cDNA encoding canine carbonic anhydrase VI (CA-VI). DNA Seq. 14:195-198. - Ogawa Y., Chang C.K. & Yagi T. 1990. Immunoelectron microscopy of carbonic anhydrase isozyme VI in rat submandibular gland: comparison with isozymes I and II. J. Histochem. Cytochem. 40:807-817. - Ogawa Y., Hong S.S., Toyosawa S., Kuwahara H., Shimazaki M. & Yagi T. 1993. Immunoelectron microscopy of carbonic anhydrase isozyme VI in human submandibular gland: comparison with isozymes I and II. J. Histochem. Cytochem. 41:343-351. - Parkkila S., Kaunisto K., Rajaniemi L., Kumpulainen T., Jokinen K. & Rajaniemi H. 1990. Immunohistochemical localization of carbonic anhydrase isoenzymes VI, II, and I in human parotid and submandibular glands. J. Histochem. Cytochem. 38:941-947. - Parkkila S., Parkkila A.K., Lehtola J. et al. 1997. Salivary carbonic anhydrase protects gastroesophageal mucosa from acid injury. Dig. Dis. Sci. 42:1013-1019.

INDEX TERMS: mRNA, RT-PCR, Type 6 Carbonic anhydrase isozymes, Canine salivary gland, Laser-microdissection.

002. Aramburú Junior J.S., Severo Cunha C.M. & Anjos Lopes S.T. 2007. **Is it enough being a family physician in order to act on the odontologic health of dogs and cats?** *Pesquisa Veterinária Brasileira 27(Supl.).* Departamento de Pequenos Animais, UFSM, Santa Maria, RS 97000-000, Brazil. E-mail: aramburu@mail.ufsm.br

Introduction: Veterinary Dentistry is a specialization whose purpose is solving the oral illnesses or with oral appearances in animals. Such specialization, respected as scientific discipline, is adding specialists all over the world due to the importance of the oral health of animals and of the complex relations between their oral and systemic health. The present study shows a questioning reflection around the veterinary physician acting as an interventor on dogs and cats oral health given their peculiar particularities. The referred study uses a bibliographic research compared to the results of a quantitative nature field research which verifies the services rendered on veterinary dentistry among the veterinary clinics of the city of Santa Maria, RS.

Materials and Methods: The field research accomplished from June 17, 2006 to July 19, 2006 had 23 veterinary clinics of the city of Santa Maria, RS, as samples. It has been composed by the application of a questionnaire containing the following four questions: a) is there any odontologic attendance on that clinic? b) Which is the odontologic service rendered by this clinic? c) Which is the information source applied by the professional (s) in order to use their knowledge regarding the theme? d) Do the professional (s) have master's degree on the Veterinary Dentistry area? The applied questions were of the closed type, that is, they already had questions choices to be indicated by the interviewees. It is important to consider that some of the questions have allowed assimilating more than one answer.

Results: Starting from the achieved answers we have observed that 21 clinics in the city offer services on veterinary dentistry while only two do not do that. Now regarding the rendered odontologic services, 15 clinics carry out prophylaxes; 20 act on periodontal interventions; 1 renders endodontic services; 10 carry out exodontias, and 1 accomplishes orthodontic interventions. None of the researched clinics accomplishes restorations. In relation to the updating of odontologic knowledge there have been 12 answers for the magazines usage; 12 for the books usage, 12 for courses on the area; 10 for internet consultations, and 5 for congresses. None of the professionals of the 23 clinics researched affirmed to have been in any courses of master's degree on Veterinary Dentistry in a level of specialization, master's degree or doctorate.

Discussion: The periodontal diseases affect a high percentile of accompanying animals, mainly dogs (Cox & Lepine 2003). Most of the veterinary clinics of Santa Maria states to treat periodontal diseases. For the accomplishment of the endodontic treatment is fundamental to have the basic knowledge on endodontic, the physiology, the pathology, the diagnosis, the equipments, the tools, and the filling techniques, besides the postoperative processes (Leon-Roman & Gioso 2002). However, in Santa Maria, this kind of intervention is carried out by professional (s) without qualification in level of post-graduation. In spite of the complexity of the prophylactic process (Cox & Lepine 2003), professionals of a large number of veterinary clinics researched states to carry out the procedure even without having academic qualification for that. Even though they believe in Veterinary Dentistry as being a specific area of the veterinary physicists (Correa & Venturini 2005), the own authors affirm that those professionals do not have technical bases for this kind of attendance. Nevertheless, most of the veterinary clinics of Santa Maria act on the area.

Conclusion: The importance of the professional understanding and of the development of the odontologic specialty in the treatment of dogs and cats has fundamental importance for these animals health. Though, is notorious the establishment of an impasse and of a conflict of interests characterized by the following situation: veterinary physicians do not accept the dentists to act on odontologic treatment of dogs and cats but they also do not consider themselves as being able to act on this specialty once that their basic curriculum of formation does not embrace this knowledge. In Santa Maria, the veterinary professionals acting on the area of Veterinary Dentistry occurs in a large scale and in an empiric way even without academic qualification, which is necessary in face of the importance involving the procedures. Such situation indicates urgency in the sense that the local high teaching institutions plan and perform courses to make veterinary physicians able to practice Veterinary Dentistry for the technical and ethical responsibility around the thematic.

References: Brazilian Association of Veterinary Dentistry, Brazilian Association of Veterinarian Dentistry - São Paulo, 2006: Available in: <http://www.abov.org.br/>. Access in: February 12, 2006. - Correa H.L. & Venturini M. 2005. Veterinary Dentistry: Veterinarian x Dentist. Bichoonline, São Paulo. Available in: <http://www.bichoonline.com.br/artigos/Xhc0002.htm>. Access on February 12, 2007. - Cox E.R. & Lepine A.J. 2003. New techno-logies for the investigation of dental issues. 8th Electronic Annals World Vet. Dental Congr., Kyoto, Japan. Available in:<http://www.eukanubascienceonline.com/download/symposia/2/World_Dental_Congress_2003.pdf>. Access on February 7, 2007. - Domingues L.M. 2002. Histological, histomicrobiological and radiological analysis of dogs' teeth with experimentally induced pulpar necrosis submitted to different dental stuff. Thesis (Doctorate in Veterinary Surgery), Universidade Estadual Paulista, Jaboticabal, SP. 124p. - Harvey C.E. & Emily P.P. 1993. Small Animal Dentistry. Mosby-Year Book Inc., St Louis. - Holmstrom S.E., Frost P. & Eisner E.R. 1998. Veterinary Dental Techniques for the Small Animal Practitioner. W.B. Saunders, Philadelphia. - Leon-Roman M.A. & Gioso M.A. 2002. Conventional canal treatment: option to the extraction of endodontically affected teeth, a review. Vet. Clin. 40:32-44. - Polivet 2006. Cardiology and Veterinary Dentistry. Veterinary Dentistry: a private activity of the veterinary physician. Polivet, Itapetininga. Available in: <http://www.polivet-itapetininga.vet.br/Txt_Odonto.htm>. Access on January 26, 2007. - Odonto's researcher invents toothbrush for cats and dogs. USP's Electronic Newspaper, Ribeirão Preto no.. 734, november 2001. Available in: <http://www.pcarp.usp.br/acsi/anterior/734/mat4.htm>. Access on February 5, 2007.

INDEX TERMS: Veterinary dentistry, odontology, veterinary.

003. Borges J.I.M. 2007. **The use of the enamel matrix derivative proteins in periodontal regeneration.** *Pesquisa Veterinária Brasileira 27(Supl.).* Médica Veterinária Autônoma, Bucalvet-odontologia Veterinária, Florianópolis, Santa Catarina (www.bucalvet.com.br). E-mail: josaine@newsite.com.br

Introduction: The periodontal disease is the most commum illness in dogs and cats, characterized by a destruction of teeth supporting tissues. One of the main objectives of periodontal therapy is the morphologic and functional reconstruction of the lost tissues of support periodontal. The enamel matrix derivative proteins (EMDP) has been introduced in the periodontal field impelling the studies about the periodontal regeneration to a new stage, because they act as biological modifiers, which present stimulate properties of periodontal tissue.

Case Report: The implications of the enamel matrix proteins derivative (EMPD) using in the periodontal regeneration, illustrating in practice its use in a 10 year-old dog, of Pinscher breed, which was submitted to EMD application in infra-bony lesion between the fourth premolar and first molar left inferior. After accomplishment of mucoperiostal flap, the enamel matrix proteins were applied onto the surface of the exposed root. Six months after the procedure, increased bone radiographic level and decrease of the probing depth were observed.

Discussion and Conclusion: The enamel's proteic matrix was verified in animals and in humans and it seems to stimulate a new cementum formation, which allows a periodontal ligament and alveolar bone formation, mimicking what happens during tooth development and promoting the periodontal regeneration. These enamel proteins, mainly the amelogenin, are present in the odontogenesis during the root formation. When produced and secreted by Hertwig's epithelial root sheath, they stimulate the differentiation of the mesenquimal cells in cementoblasts, wich form acellular cementum on the root surface. Therefore, through a sequence of procedures, there is the formation of support periodontal. Clinical studies demonstrated that Emdogain®, a commercial formula of EMDP of swine origin, associated to periodontals surgeries, showed significant clinical attachment gain, probing depth reduction and alveolar bone gain. EMPD may be effective in the induction of periodontal regeneration.

References: Araújo M.G. & Lindhe J. 1998. GTR treatment of degree III furcation defects following application of enamel matrix proteins: an experimental study in dogs. J. Clin. Periodontol. 25:524–530. - Froum S., Weinberg M., Novak J., Mailhot J., Mellonig J. et al. 2004. A multicenter study evaluating the sensitization potential of enamel matrix derivative after treatment of two infrabony defects. J. Periodontol. 75(7):1001-1008. - Francetti L., Trombelli L., Lombarco G., Guida L., Cafiero C., Roccuzzo M., CarusiI G. & Del Fabbro M. 2005. Evaluation of efficacy of enamel matrix derivative in the treatment of intrabony defects: a 24-month multicenter study. Int. J. Periodontics, Restorative Dent., 25(5):461-473. - Hammastrom L. 1997 Enamel matrix, cementum development and regeneration. J. Clin. Periodontol. 24:658–668. - Hammarström L., Heijl L. & Gestrelius S. 1997 Periodontal regeneration in a buccal dehiscence model in monkeys after application of enamel matrix proteins. J. Clin. Periodontol. 24:669-677. - Heijl L., Heden G., Svardström G. & Ostgren A. 1997 Enamel matrix derivative (Emdogain) in the treatment of intrabony periodontal defects. J. Clin. Periodontol. 24:705-714. - Sakallioglu U., Acikgoz G., Ayas B., Kirtiloglu T. & Sakallioglu E. 2004. Healing of periodontal defects treated with enamel matrix proteins and root surface conditioning-an experimental study in dogs: Biomaterials 25(10):1831-1840. - Venezia E., Goldestein M., Boyan B.D. & Schwartz Z. 2004 The use of enamel matrix derivative in the treatment of periodontal defects: a literature review and meta-analysis. Crit. Rev. Oral Biol. Med.15(6):382-402. - Watanabe K. et al. 2003. Protein applied to spontaneous periodontal disease in two dogs. J. Vet. Med. Sci. 65(9):1007-1010. - Watanabe K., Kiruchi M., Okumura M., Kadosawa T. & Fujinaga T. 2001. Efficacy of enamel matrix proteins on apical periodontal regeneration after experimental apicoectomy in dogs. J. Vet. Med. Sci. 63(8):889-894. - Zetterström O., Andersson C., Eriksson L., Fredriksson A., Friskopp J., Heden G. et al. 1997. Clinical safety of enamel matrix derivative (Emdogain) in the treatment of periodontal defects. J. Clin. Periodontol. 24:697-704.

INDEX TERMS: Periodontal disease, enamel matrix derivative proteins, periodontal regeneration.

004. Caiafa A.M. 2007. **Implant surgical technique and osseointegration.** *Pesquisa Veterinária Brasileira 27(Supl.).* Department of Veterinary Dentistry, University of Melbourne, Veterinary Clinic and Hospital, Werribee 3030, Australia. E-mail: toothdoc@tpg.com.au

Introduction: Implantology is a rapidly growing discipline in dentistry. Implants offer a solution for tooth replacement in an edentulous space. In dogs and cats, the main causes of tooth loss are due to either periodontal disease or trauma.

Literature Review: There is very little veterinary literature available on dental implants in dogs or cats. However, a number of implant studies were performed with the use of dogs as a study model. A medline and CAB abstracts search was carried out exclusively for this abstract.

Discussion: There are three types of implants available: subperiosteal, transosseous and endosseous. The most common form of implant used today is the endosseous implant. There are a number of endosseous implant systems in the market place, with each system offering varying levels of simplicity of use with different implant surface treatments to speed up osseointegration (direct bone to implant contact-BIC) with a subsequent shorter treatment times and a quicker return to function for the patient. Only a few of the implant systems available today, have sufficient evidence offering long term success to support their use in patients. The success of implant placement and BIC depends on a number of factors including case selection and planning, the quality and density of bone at the implant site and the surgical skills of the implantologist to position the implant in the optimal position for osseointegration and finally the placement of the definitive restoration. *Factors affecting implant surgery: Patient factors*: Any

systemic factor that affects bone healing may be detrimental to implant placement and osseointegration. Factors may include systemic illnesses such as diabetes mellitus, malnutrition, vitamin or mineral deficiencies. Patients should have an undisturbed wound healing capacity and implants should not be used before jaw growth is complete except in orthodontic patients (Buser et al. 2000). *Surgeon factors*: The training and skill of the surgeon, knowledge of the anatomy of the implant site including vital structures such as blood vessels, sinus cavities and nerves. Drilling technique to avoid excessive heat production and possible bone necrosis. *Local factors - Host site:* Local factors including bone quality and density, hard or soft tissue deficits, local pathology including periodontal disease and infection. Bone quality can be assesed at the time of surgery. Cutting resistance relates well to bone density during surgery. The use of bone taps may not be required and may even be contraindicated when placing implants into poor quality bone sites. Healing with osseointegration is achieved more frequently in the mandible than the maxilla (Ellegaard et al. 1997). The height and orofacial dimensions of the alveolar ridge are also very important to the success or failure of the implant placement and osseointegration. Tooth loss due to periodontal disease often involves marked aveolar bone loss both in height and width. Uncontrolled periodontitis would be a contraindication for implant placement. *Implant design:* Endosseous implants are usually made of commercially pure titanium. Titanium is a reactive metal that on exposure to air forms titanium oxide on its surface. Titanium oxide offers a corrosion resistant surface. Most implant systems used today are solid screw type implants made of titanium. The threaded portion of the implant offers a larger surface area for engaging the bone to provide initial stability of the implant. Secondary stability is achieved by osseointegration in which bone directly contacts the implant surface. Treatment of the implant surface (with sand blasting and/or acid etching) within a surface roughness range of 1–2μm has been shown to increase the rate of osseointegration thereby improving early stability of the implant. This improvement is thought to be due to a combination of factors, incuding increasing the surface area of the implant for integration to occur, modulating cellular activity to promote migration and differentiation of osteoblasts, and to improve fibrin adhesions and stabilisation of the blood clot. Alterations in surface morphology through acid etching provides a bioactive surface with good wettability through increased surface area and protein absorption. There is increased adsorption of fibrinogen and concentration of complement factor 3. There is early bone apposition onto its surface with increased bone to implant contact (Abrahamsson et al. 2004). Further improvements to the rate of osseointegration may be obtained by altering the surface chemistry of the implant surface (Buser et al. 2000), either by minimizing contaminants in the titainum oxide layer or by the addition of fluoride ions which can stimulate osteoblasts to form new bone (Stanford 2006). Implants can have either an external hex, internal hex or morse taper connection (ITI-Straumann) to the abutment. The morse taper internal screw retained abutment offers the least microgap between the implant and the abutment, therefore reducing biofilm growth. The morse taper also distributes stress away from the abutment screw, thus minimising screw loosening or fracture. Abutments can be either machined or custom made out of titanium or porcelain. The definitive crown can either be screw retained or cement retained to the abutment. Screw retained crowns may be lost due to screw loosening or screw fracture but are better suited when the implant is surrounded by a high gingival cuff. Cement retained crowns are usually easier to manufacture in the laboratory and it is easier to achieve a passive fit on the abutment when compared to screw retained abutments. However cement may extrude into the gingival soft tissues and may be difficult to remove. In the past, implant failure was partly a result of the placement of implants that were too short. With the advent of textured implant surfaces and increased rate of osseointegration, the survival rates for short and for wide-diameter implants has been found to be comparable to those obtained with longer implants and those of standard diameter. The use of a short or wide implant may be considered for use in sites thought unfavourable for implant success, such as those associated with bone resorption, or previous injury and trauma (Renouard & Nisand 2006). *Timing of implant placement:* Studies have shown that the timing of implant placement is very important to a successful outcome. A study in dogs (Arauja & Lindhe, 2005) showed marked dimensional changes occurred in the bone after extraction of mandibular premolars. There can be marked loss of crestal bone height as well as buccal wall resorption post extraction. These changes will affect the choice of implant length and width and may compromise osseointegration with the possible need for bone regenerating materials. *Equipment requirements:* Intraoral radiography (preferably digital). Variable speed implant motor with contra angle hand piece with external sterile fluid delivery.Surgical implant kit including solid screw implants, healing caps, cortical round burs, pilot and twist drills, depth gauges, drill taps, screw drivers, tightening wrench and torquing tool. *Implant placement and definitive restoration procedure - 1st visit, Site assessment:* Maxillary/mand-dibular impressions and study models, intraoral photos, periapical radio-graph of implant site, site assessment including bone map-ping, interocclusal space, mesio-distal space, bucco-lingual width, root an-gulation of neigh-bouring teeth. Treatment planning including choice of implant system, length and width of implant and healing cap. Submerged vs. non-submerged implants. *2nd visit, implant placement:* Flap design: Preservation of keratinised mucosa: placement of implant: correct angulation, depth; possible need for bone augmentation and resorbable collagen membrane; healing cap placement: one stage, non submerged (healing cap) versus two stage submerged (cover screw) implant surgery. *3rd visit, impression taking for definitive restoration:* Assess implant stability and osseointegration with periapical radiograph. An accurate PVS impression (closed or open tray impression) is taken of the implant using a preformed impression coping to give the laboratory technician the exact position of the implant head/shoulder. A periapical radiograph should be

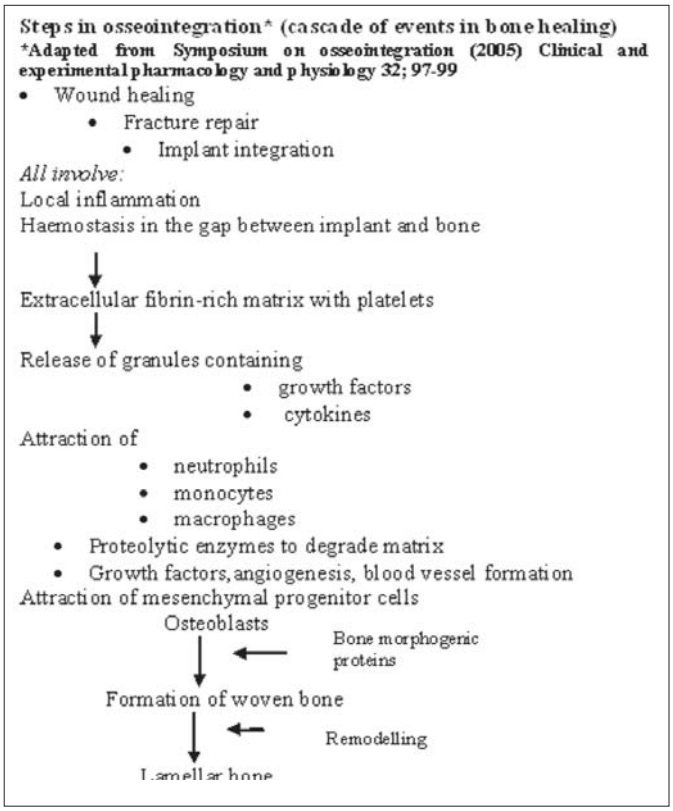

taken to confirm correct postioning of the impression coping before taking the impression. *Bite registration* of the incisor/canine region so that the maxillary and mandibular models can be mounted accurately. *Shade selection*: a good quality intraoral photograph with a closest match shade guide next to a neighbouring tooth. This allows the laboratory technician to get an accurate shade match for the definitive crown. Crown should be manufactured so that it is out of the occlusion. *4th visit, abutment and definitive crown placement:* A customised or machined abutment is screw retained to the implant fixture and torqued to manufacturer's recommendations. A periapical radiograph is taken to confirm the correct seating of the abutment before torquing it. The crown is then trial fitted and occlusion checked. If it seats well it is either then screw retained (screw retained crown) or cemented (cement retained crown) into place. The occlusion is checked again and excess cement (cement retained crown) removed as necessary. Meticulous homecare should be performed at all stages of the implant procedure. The use of chemical plaque retardants, antimicrobials and analgaesics is warranted. *Implant failure:* Implant failure occurs due to poor planning prior to surgery, infection at the time of and post surgery, mechanical stresses on the implant fixture and abutment screw which may lead to fracture of the implant or the abutment. Perimplant mucositis and periimplantitis can be seen post implant placement if plaque control is not optimal. The microbiota involved in periimplantitis are very similar to that seen in advanced periodontitis (Mombelli et al. 1987).

Conclusions: The osseointegration of implant fixtures in dogs is highly predictable. Case selection and appropriate treatment planning are imperative in obtaining a successful outcome. It cannot be stressed enough that for restored implant cases, a high level of plaque control through homecare is needed to maintain the restoration and the endosseous implant.

Veterinary dentistry tends to mimic the human dental field and although early days, the use of implants in dogs and cats may be another area of growth in the discipline of veterinary dentistry.

References: Abrahamsson I., Berglundh T., Linder E., Lang N. & Lindhe J. 2004. Early bone formation adjacent to rough and turned endosseous implant surfaces: an experimental study in the dog. Clin. Oral Impl. Res. 15:381-392. - Araujo M. & Lindhe J. 2005. Dimensional ridge alterations followitng tooth extraction: an experimental study in the dog. J. Clin. Periodontol. 32:212-218. - Buser D., Arx T., Bruggenkate C. ten & Weingart D. 2000. Basic surgical prinicples with ITI implants. Clin. Oral Impl. Res. (Suppl.):59-68. - Ellegaard B., Baelum V. & Karring T. 1997. Implant therapy in periodontally compromised patients. Clin. Oral Impl. Res. 8:180-88. - Mombelli A., Van Oosten M., Schurch E. & Lang N. 1987. The microbiota associated with successful or failing osseointegrated titanium implants. Oral Microbiol. Immunol. 2:145-151. - Renouard F. & Nisand D. 2006. Impact of implant length and diameter on survival rates. Clin. Oral Imp. Res. 17 (Suppl.2): 35-51. - Stanford C. 2006. Advancements in implant surface technology for predictable long-term results. US Dentistry:30-32remodelling

INDEX TERMS: Implant, oseointegration, dog, cat.

005. Caiafa A. M. 2007. **Periodontitis and its association with systemic disease.** *Pesquisa Veterinária Brasileira (Supl.).* Department of Veterinary Dentistry, University of Melbourne, Veterinary Clinic and Hospital, Werribee 3030, Australia. E-mail: toothdoc@tpg.com.au

Introduction: Periodontal disease (PD) is an inflammatory disease involving the supporting structures of the teeth. The primary cause is plaque with the predominant bacteria in periodontitis being anaerobic in origin. Researchers now hypothesise that PD is a risk factor for other organ disease.

Literature Review: The veterinary literature on this subject is patchy at best. The dental literature in man is more comprehensive and a lot of the discussion in this paper will be taken from research done in man. Medline and CAB abstracts was used exclusively to perform the literature review.

Discussion: Links between PD and systemic illnesses have been discussed for many years, but with no real proof of such links. In the late 1800's, the concept of "focus of infection" (Miller 1891) held that transient bacteraemias occurred from oral infections. It has been shown in veterinary medicine, that bacteraemias do occur following insults such as intestinal obstruction and GDV syndrome (Winkler et al. 2003). It is accepted that dental (Harari 1993) or oral surgery procedures, periodontal probing, toothbrushing and mastication cause transient bacteraemias, that, in the healthy patient, are quickly

cleared by the reticulo-endothelial system. Furthermore, the possible contribution of oral bacteria in periodontal pockets to bacterial endocarditis has been suggested for decades. But it wasn't until Offenbacher and co-workers commenced their research in the 1990s, that links between PD and other organ disease were considered possible. The two-way relationship between PD and systemic health has now termed the phrase *periodontal medicine* (Offenbacher 1996). Recent research has shown a link between PD and cardiovascular disease, as well as pre-term/low birth weight babies in man. *Pathways linkingPD to systemic diseases: Three* pathways linking PD to systemic effects have been proposed. *Infection theory*: It has been reported that in patients with periodontal inflammation, a Streptococcus sanguis protein associated with platelet aggregation and bacteraemia associated with Porphyromonas gingivalis may contribute to some acute thromboembolic events (Meyer et al. 1998). *Distant injury*: Distant injury may occur directly from circulating oral microbial toxins or indirectly through the elevation of the acute-phase response, including C-reactive protein, haptoglobin, alpha 1-antitrypsin and fibrinogen. The liver, in response to the systemic challenge of organisms, secretes acute-phase proteins. This acute-phase response is triggered by blood-borne oral lipopolysaccharide, and oral bacteria which elicit the release of the cytokines interleukin-6 and tumour necrosis factor alpha. These mediators act in the liver to induce the acute-phase proteins. Acute phase proteins especially C-reactive protein appear to be associated with increased risk of myocardial infarction in "apparently healthy" individuals. (Ridker et al. 1998, Scannapieco 1998). *Distant inflammation*: PD can induce changes in immune functions that result in metabolic dysregulation of serum lipid metabolism through the proinflammatory cytokines. Locally produced proinflammatory cytokines and tumour necrosis factor alpha may exert systemic effects by predisposing the patient to a systemic disorder such as atherosclerosis. *Periodontitis and Cardiovascular Disease.* It has been hypothesized that one or more infectious agents may play a role in atherogenesis (leading to atherosclerosis), either through a direct pro-inflammatory effect on the vessel wall or through a less specific, long-distance pro-inflammatory effect. In this context, it has been suggested that PD may be one such inflammatory foci (Honda et al. 2005). Periopathogens have been considered to be triggers of a systemic inflammatory response. Furthermore, it has been proposed that patients with PD may have elevated circulating levels of some of these inflammatory markers (Page 1998). In addition, low levels of endotoxaemia in apparently healthy subjects might result from chronic infection associated with the breaching of epithelial barrier function such as seen in PD (Rice et al. 2005). In the veterinary literature, a recent report (Tou et al. 2005) showed a possible link between dental prophylaxis and infective endocarditis in a dog with existing mitral regurgitation. The dog became ill and feverish soon after the dental prophylaxis, and it was suspected that a bacteraemia associated with the dental treatment induced infective endocarditis in this case. Blood cultures in this dog grew a heavy growth of Streptococcus bovis. *Preterm/low birth weight babies:* PD is currently being investigated as a risk factor for premature and low birth weight babies. Pregnant women who have periodontal disease may be seven times more likely to have a baby that is born too early and too small. It appears that PD triggers increased levels of biological fluids that induce labour. Furthermore, data suggests that women whose periodontal condition worsens during pregnancy have an even higher risk of having a premature baby (Oral health information for the public: Preterm low birth weight babies, 2004). A study by Constanza (2005) and others showed that PD may be a potential independent risk factor for preterm low birth weight (PLBW) after adjusting for several known risk factors. A number of biologically active mediators such as prostaglandin E2 (PGE2) and tumour necrosis factor alpha (TNF alpha) are also involved in normal parturition. These mediators are raised to artificially high levels during infections and thus may foster premature labour (Gibbs et al. 1992). Lipopolysaccharides from gram-negative anaerobes found in periodontal pockets trigger release of PGE2 and TNF alpha, which may, in turn, affect the course of pregnancy. Evidence to support this hypothesis has been obtained in rodent models. In addition, a recent study of mothers of PLBW infants (Offenbacher, 1996), with otherwise low risk, had significantly more PD than a similar group of women with normal weight infants at birth. *Diabetes mellitus:* People with diabetes mellitus are 15 times more likely to be edentulous than people without the disease. Both type 1 (insulin controlled) and type 2 (non-insulin controlled) diabetes have the same effect. The likelihood of PD increases when diabetes is poorly controlled (Seppala & Ainamo 1994). People with well-controlled diabetes, with good oral hygiene and on a regular maintenance schedule have the same chance of developing severe periodontitis as people without diabetes. The mechanism is multi-factorial. The small blood vessels of people with diabetes have thickened basement membranes, leading to a reduction in transport across the vessel walls. There is a reduction in collagen production by gingival and periodontal fibroblasts. There is also an acquired neutrophil dysfunction associated with diabetes mellitus, leading to impaired host defence against bacterial assault. In addition, high levels of pro-inflammatory mediators responding to endotoxin from gram- negative bacteria lead to an increase in collagen breakdown (Matthews 2000). There appears to be a relationship between insulin resistance and active inflammatory connective tissue disease and acute infections. Tumour necrosis factor alpha and other inflammatory cytokines found to be associated with periodontitis have been reported to interfere with insulin's actions and lead to metabolic alterations during infection (Hotarnisligil et al. 1993, Flier 1993). Diabetes mellitus in dogs and cats is often associated with PD. It is common practice that in those animals that show poor glycaemic control of their diabetes, periodontal management is seen as an essential component in restoring control of blood glucose levels and for the reduction in insulin dosage. This would therefore strenghthen the recommendation to incorporate a thorough oral examination and appropriate periodontal care in the

management of dogs and cats with diabetes mellitus. *Periodontitis and pulmonary disease:* Bacterial respiratory infections are thought to be acquired through aspiration (inhaling) of fine droplets from the mouth and throat into the lungs. These droplets contain organisms that can breed and multiply within the lungs to cause damage. Recent research suggests that bacteria found in the throat, as well as bacteria found in the mouth, can be drawn into the lower respiratory tract. Scientists have found that bacteria that grow in the oral cavity can be aspirated into the lung to cause respiratory diseases such as pneumonia, especially in people with PD. *Periodontitis and systemic disease in dogs:* Numerous studies have shown that a transient bacteraemia occurs in dogs after a dental procedure (Harari et al. 1993, Nieves et al. 1997). It is also accepted that during episodes of active periodontitis, periopathogens and their toxins enter the bloodstream. However, very few studies have been undertaken, looking at the association of PD and organ involvement in dogs and cats. DeBowes et al. (1996) showed an association between PD and morphologic changes in renal glomeruli and interstitium, myocardium and hepatic parenchyma. However, there was no significant association between PD scores and lung histopathology scores. The authors concluded that their results supported the hypothesis that PD can have systemic effects on other organs. A recent study conducted in thirty-eight client owned dogs (Rawlinson et al. 2005) looked at the association between the concentration of systemic inflammatory parameters (including serum C-reactive protein, urine protein:creatinine ratio, blood pressure, microalbuminuria), and severity of PD and then, after appropriate treatment of PD, the changes in these systemic parameters. The study showed that increases in concentrations of systemic inflammatory markers were positively related to the severity of PD. After periodontal therapy, there was a significant decrease in the concentrations of some of these inflammatory markers. The study showed that PD leads to systemic inflammation that is significantly reduced with appropriate periodontal therapy. The authors concluded that further research was required to fully understand the significance of these changes.

Conclusion: Proving the link between cause and effect of chronic diseases, such as PD, is not an easy task. As PD is generally slowly progressing, people/animals studied over a long period may be exposed to a multitude of potential causes making determination of a cause–effect link more difficult. However, there seems to be a growing body of evidence to suggest the PD is a true risk factor for other systemic diseases such as cardiovascular disease.

References: Constanza M., Segura-Egea J., Martínez-Sahuquillo A. & Bullon P. 2005. Correlation between infant birth weight and mother's periodontal status. J. Clin. Periodontol. 32(3):299-304. - DeBowes L., Mosier D., Logan E., Harvey C., Lowry S. & Richardson D. 1996. Association of periodontal disease and histologic lesions in multiple organs from 45 dogs. J. Vet. Dent. 13(2):57-60. - Flier J. 1993. An overview of insulin resistance, p.1-8. In: Moller D.E. (ed.), Insulin Resistance. Wiley, New York. 1-8. - Gibbs R.S., Romero R., Hillier S.L., Eschenbach D.A. & Sweet R.L. 1992. A review of premature birth and subclinical infection. Am. J. Obstet. Gynecol. 166:1515-1528. - Harari J., Besser T., Gustafson S. & Meinkoth K. 1993. Bacterial isolates from blood cultures of dogs undergoing dentistry. Vet. Surg. 22:27-30. - Honda T., Yoshie H. & Yamazaki K. 2005. Effects of Porphyromonas gingivalis antigens and proinflammatory cytokines on human coronary artery endothelial cells. Oral Microbiol. Immunol.:82-88. - Hotarnisligil G., Shargill N. & Spiegelman B. 1993. Adipose expression of tumour necrosis factor alpha: direct role in obesity-linked insulin resistance. Science 259:87-91. - Matthews D. 2000. Periodontal disease: a new paradigm J. Can. Dent. Assoc. 66:488-491. - Meyer M., Gong K. & Herzberg M. 1998. Streptococcus sanguis-induced platelet clotting in rabbits and haemodynamic and cardiopulmonary consequences. Infect. Immun. 66(12):5906-5914. - Miller W. 1891. The human mouth as a focus of infection. Dental Cosmos 33:689-713. - Nieves M., Hartwig P., Kinyon J. & Riedesel D. 1997. Bacterial isolates from plaque and from blood during and after routine dental procedures in dogs. Vet. Surg. 26:26-32. - Offenbacher S. 1996. Periodontal diseases. Pathogenesis. Ann. Periodontol.:821-878. - Offenbacher S., Katz V., Fertik G., Collins J., Boyd D. & Maynor G. 1996. Periodontal infection as a possible risk factor for preterm low birth weight. J. Periodontol. 67(10, Suppl.):1103-1113. - Page R. 1998. The pathobiology of periodontal diseases may effect systemic diseases: inversion of a paradigm. Ann. Periodontol. 3:108-120. - Rawlinson J., Goldstein R., Reiter A., Hollis N. & Harvey C. 2005. Tracking systemic parameters in dogs with periodontal disease. Conf. Proc. 19th Annu. Vet. Dental Forum and IX World Vet. Dental Congr., Orlando, Florida, p.49. - Rice J., Stoll L., Li W., Denning G., Weydert J., Charipar E., Richenbacher W., Miller F. & Weintraub N. 2003. Low-level endotoxin induces potent inflammatory activation of human blood vessels: inhibition by statins. Arterioscler. Thromb. Vasc. Biol. 23:1576-1582. - Ridker P., Cushman M., Stampfer M., Tracy P. & Hennekens C. 1998. Plasma concentration of C-reactive protein and risk of developing peripheral vascular disease. Circulation 97:425-428. - Scannapieco F. 1998. Position paper. Periodontal disease as a potential risk factor for systemic diseases. J. Periodonol. 69:841-850. - Seppala B. & Ainamo J. 1994. A site-by-site follow-up study on the effect of controlled versus poorly controlled insulin-dependent diabetes mellitus. J. Clin. Periodontol. 21:161-165. - Tou S., Adin D. & Castleman W. 2005. Mitral valve endocarditis after dental propyhlaxis in a dog. J. Vet. Intern. Med. 19:268-270. - Winkler K., Greenfield C. & Schaeffer D. 2003. Bacteria and bacterial translocation in naturally occurring canine gastric dilatation-volvulus patient. J. Am. Anim. Hosp. Assoc. 39:361-368.

INDEX TERMS: Periodontitis, systemic, disease, animal, dog, cat.

006. Camargo S.L.S.C & Gioso M.A. 2007. **Metallic multiple restoration: a case report.** *Pesquisa Veterinária Brasileira 27(Supl.).* Odontologia para Pequenos Animais (Odontopet), São Paulo, S.P., Brazil. E-mail: maggioso@usp.br

Introduction: A 8-year-old Dobermann, male, presented with its four canine teeth fractured and with dentary abrasion. These teeth were prepared for non-precious metal, full crown restoration, in canine 104 and 204, after endodontic treatment, and for number 304 and 404, which also received crown lengthening after ossectomy. To accomplish oral rehabilitation, one of the solutions is the use of metallic crowns, with cosmetic and functional reestablishment of the mouth. A crown is an extra coronal restoration that covers all or most of the coronal portion, restores the function and structure of a damaged tooth, and protects the remaining structure. Crown retention is dependent upon preparation

design and choice of cement. The most common place for attrition on the crown of a tooth is the distal face of the canine (Brech et al. 1997). Campos et al. (2003) defend that the teeth with endodontic treatment are more prone to break, because the loss of the dental structure, endodontic techniques and surgical instruments choice, as well as the approach to the radicular canal which can decrease the strength. Additionally there is a lower dentinary humidity, with changes in the resilience of the tooth, with increase of the risk of fractures. Human patients, after prosthetic adaptation, learn and restore the signs of proprioception, which result in changes in their mouth. A gradual conditionament of the tooth structures and diet control (soft food) also cause progressive adjustment (Montenegro et al. 2004). A crown is an extracoronal restoration that covers all or most of the coronal portion of a tooth, restores the function and structure of a damaged tooth, and protects the portion of the tooth that remains (Forest & Roeters 1998, Visser 1998, Wiggs & Lobprise, 1993). For the teeth endodontic treated, that need restoration with intra-radicular pins, there are different opinions about of the length of the pins in relation with the remaining crown. There are reported ranges from 100% of the crown height, or of 5mm beyond the crown and still 2/3 to 4/5 of the length of the root (Mori et al. 1997).

Case Report: The crown preparation was done according to the biomechanical technique used for human dentistry and veterinary dentistry (Schillingburg et al. 1987, Visser 1998). After crown preparation, the impression was done with condensing silicone (Perfil Denso Vigodent®, Perfil fluido Vigodent®), with the double phase technique. These materials provide the exact details required for the crown. The teeth were previously alleviated with wax (utility wax Wilson®). The same procedure was applied to the four teeth (104, 204, 304, 404).The bite registrations were necessary for crowns on canine teeth, and the wax is not inexpensive and simple to use. (utility wax Wilson®). Theses teeth were prepared for non-precious metal Nyckel-cromium (FIT CAST-V®, Paladium of Brazil). The choice of cement used to cement the metal crowns on the canine teeth was Zinc Phosphate (SSWhite ®). After surgical prepare, the remaining crown of each one of the teeth were to cover with a temporary crown by acrylic (Dencor® number 61) to protect the crown. This temporary crown also is cemented with Zinc Phosphate (SSWhite ®). The crown was checked in the mouth to ensure that it seats fully to the marginal line and that the occlusion is correct. The procedures of cementation were taken 15 days, after the crown preparation and impression.

Discussion and Conclusion: The reconstitution of the dental crown is the most difficult and detail job to be done because of the many technical difficulties, due to iatrogenic factors, which can cause permanent damage. There will never be a technique to develop the correct contours. Even, with all the difficulties that knowledge gives us to take immediate and most precise decisions, we conclude that dental metallic rehabilitation is possible, when we use techniques described and consider that there are many concepts for the best methods or the most indicated. The objective of this technique is to protect the remaining crown, even if fractured or not. In most cases the endodontical treated teeth should receive metallic restoration.

References: Brech C., Hamel L., Le Nihouannen J.C. & Daculsi G. 1997. Epidemilogical study of canine teeth fracture in military dogs. J. Vet. Dent. 14(2):51-55. - Brine E.J. & Marreta A.S.M. 1999. Endodontic ireatment and metal crown restoration of a fractured maxillary right fourth premolar tooth: a case report. J. Vet. Dent. l16(4):159-163. - Harvey C.E. & Emily P. 1993. Small Animal Dentistry. 1st ed. Mosby-Year Book Inc., St Louis. 413p. - Holmstrom S.E., Frost P. & Gammon R.L. 1994. Técnicas Dentales de Pequenos Animales. 1ª ed. Editora Interamericana, São Paulo, p.429. - Lindner D.L., Marreta S.M., Pijanowski G.J., Johnson A.L. & Smith C.W. 1995. Measurement of bite force in dogs: a pilot study. J. Vet. Dent. 12(2):49-52. – Martignoni M. & Schönemberger A. 1998. Precisão em Prótese Fixa: aspectos clínicos e laboratoriais. 1ª ed. Quintessense Publ., São Paulo, p.579. - Montenegro F.L.B. 2004. Instalação da prótese parcial fixa: cuidados e controles posteriores. Artigo publicado em Odontologia.com.br, 3.12.2004, endereço: http://www.odontologia.com.br/artigos.asp?id=429. Acesso 10 de agosto de 2005. - Morim et al. 1997. Estudo da distribuição das tensões internas, sob a carga axial em dente hígido e em dente restaurado com coroa metalocerâmica e retentor intra-radicular fundido: método do elemento finito. Revta Odontol. Univ. São Paulo 11(2):99-107. - Phillips R.W. 2005. Materiais Dentários. 11ª ed. Ediora Elsevier, São Paulo, p.467. - Schillingburg H.T., Hobo S., Whitsett L.D., Jacobi R. & Bracket S.E. 1997. Fundamentos dos Preparos Dentários: para Rrstaurações metálicas e de porcelana. 3ª ed. Quintessence Publ., São Paulo, p.389. - Schillingburg H.T. & Kessler J.C. 1987. Restauração Protética dos Dentes Tratados Endodonticamente. 1ª ed. Quintessense Publ., São Paulo, p.384. - Shipp A.D., Favd P. & Fahrenkrug 1992. Practitioners'Guide to Veterinary Dentistry. 1st.ed., p.237.

INDEX TERMS: RMF, metallic crown restoration.

007. Camargo S.L.S.C. & Gioso, M.A. 2007. **Dentary abrasion: cause or consequence of tooth pain?** *Pesquisa Veterinária Brasileira 27(Supl.).* Odontologia para Pequenos Animais(Odontopet), São Paulo, SP, Brazil. E-mail: maggioso@usp.br

Introduction: The animals spontaneously choose and search, without evident reason, hard structures to bite. This can cause progressives abrasion or attrition with injury to the enamel of the incisors, canine teeth, or to any other teeth. At the same time, these lesions can expose dentin and more aggressively, the pulp, with pain process.

Literature Review: The attrition consequences consist in loss of enamel, with exposition of dentine material, initialized with abrasion. The tooth length decreases with loss of crown structures. The canine tooth is most frequently worn on the distal side. (Brech et al. (1997).Ten Cate (2001) related the evolution of de dental attrition in human patients, and found signs which were incomprehensible, due to the functionality of the periodontal ligament. The nervous termination that begins in the apex area and directs to the gingival margin ,joins with others nervous fibers (filament) and penetrate through lateral foramens to the alveoloar wall. In this position they separate as apical ramifications and gingival

ramifications. The pain location is very difficult to find, because they are many afferents pulpar nerves, and afferents terminations coming from orofacial structures, that impair pulpar pain location. When there is severe and fast dentinary abrasion, with pulpar exposure, and there is no fast dentine reaction, pain can be a common report in human patients, in the cases of hot, cold and pressure. When there is sclerosis of the dentine tubules, pain or other sensibilities disappears. (Leon-Roman 2004).

Discussion and Conclusion: The theory of the pain evaluation, by means of dentinary sensibility and by the hydrodynamics theory, or still for by means of dentine overgrowth reaction, which play an important role in dental element defense, seems to be true. Even though it does not explains what comes first: pain leading to abrasion or the abrasion leading to pain. Our patients, dogs and cats, although with pain, maintain their habits of attrition and abrasion that can lead to totals crown destruction with or without dentine reaction.

References: Brech C., Hamel L.LE., Nihouannen J.C. & DaculsiG.1997. Epidemilogical study of canine teeth fracture in military dogs. J. Vet. Dent. 14(2):51-55. - Fantoni D.T. & Cortopassi S.R. 2002. Anestesia em Cães e Gatos. 1ª ed. Editora Roca, São Paulo, p.389. - Harvey C.E. & Emily P. 1993. Small Animal Dentistry. 1st ed. Mosby-Year Book, St Louis. 413p. - Leon-Roman M.A. 2002. Pulpectomia total em duas sessões na endodontia veterinária. Monografia de conclusão do Curso de Atualização em Odontologia Veterinária Anclivepa-SP. 66p. - Regianini L.G. 2001. Condicionamento dentinário. Artigo publicado no Odontologia.com.br em 19 de novembro, no endereço: http:// www.odontologia.com.br/artigos.asp?id=112. Data do acesso: 10 de agosto de 2005. - Ten Cate A.R. 2001. Histologia Bucal: desenvolvimento , estrutura e função. 5ª ed. Guanabara Koogan, São Paulo. 439p

INDEX TERMS: Tooth pain, dentary abrasion.

008. Carvalho V.G.G., Carvalho P.E.G. & Thurler R.C.S.B. 2007. **Corrective orthodontics in dogs: what brackets can do for you.** *Pesquisa Veterinária Brasileira 27(Supl.).* Departamento de Cirurgia, FMVZ-USP; São Paulo, SP 05508-270, Brazil; Departamento de Ortodontia, UNICID, São Paulo, SP 03371-000, Brazil. E-mail: vanggc@uol.com.br

Introduction: Class I malocclusion, the major malocclusion group, is marked by individual teeth positions, like rotations, crowding, excessive spacing, irregular inclination and angulations, teeth size discrepancies, deciduous teeth long retention and many others (Hennet & Harvey 1992). In these cases, mesiodistal relation (rostro-caudal) are normal, with good maxillae and mandible relation. Teeth rotation and crowding can increase plaque and calculus retention, developing periodontal disease (Gioso 2003). Not well positioned teeth can interfere in dental occlusion and pet wellbeing, mainly when exists teeth-teeth or teeth-tegument tissue traumas. The correct individual teeth positioning can only be achieved with corrective fixed orthodontic mechanics, like brackets, wires, coils and orthodontic elastics, with are most useful in human orthodontics.

Literature Review: Among dental leveling and alignment mechanics available nowadays, edgewise technique is the most indicated for veterinarian procedures, as their brackets doesn't have any preprogrammed characteristics, individualizing for human teeth anatomy use. Thus, edgewise dental accessories have no pre-established angulations or inclination slots (Proffit 1986). These properties presuppose that, in dogs, teeth angulations and inclination desired for each clinical case should be obtained by orthodontic appliance correct position bonding and activating orthodontic wire with the correct bends (Interlandi 1986). Even so edgewise appliance seems more arduous than the use of preprogrammed systems, it is not true for veterinarians clinical cases, as preprogrammed brackets have angulations and inclinations specifics for each human dental form. When these appliances are used in dogs, they increase the veterinarian work, who will need to do a lot of wire bends for the undesired inclinations and angulations be neutralized. Orthodontics arch wires are the main components for the activating of dental movement, when fixed appliance is used. Positioned in the brackets slots, they will transmit some force to the teeth for its memory properties, that is, because their tendencies of return to its original form, the previous arch wire form. With this force, the teeth are moved by traction to the correct positions (Cotrim-Ferreira 1997). For this reason, arch wire choice should straightly follow the patient dental arch form and size, avoiding unexpected orthodontic movements. An ideal arch wire construction, as fitting the individual form of patient arch, should be made oriented by patient dental casts (Gioso et al. 2004). There are round, square and rectangular sectional wires, being the round wires the most used for veterinarian orthodontics. The mainly advantage of square or rectangular wires are the root torque control, enhancing three dimensional movements in the alveolar bone (Cotrim-Ferreira 1997). Different metal alloys properties can also interfere in orthodontic wires mechanics behavior, which can be used for choosing the better alloy for each treatment stage. Stainless steal alloys has good mechanical properties and low cost, being the most used in orthodontics. In the treatment mechanics, the increase of wire thickness amplifies wire rigidity and consequently, enhances its forces thought the teeth. The beginning of fixed orthodontic treatment should use arches with small dimensions, like round .012", and increase the thickness to hard wires in the treatment finalizing, as rectangular .019"x.025". This progressive thickness enhancing permits that clinician has an high flexibility wire in treatment beginning, which allows wire adaptation to the brackets slots, even with very unaligned teeth, using light and physiological strength (Moyers 1991). This soft pressure is considered as a light force, which can achieve frontal bone resorption and consequently teeth movement (Burstone 1996). About brackets sizes, they varies accordingly with human teeth sizes and veterinarian should looks for the better fitting bracket

size for each clinical case. In the majority, the mini appliances sizes for human lower incisors are the most useful for dogs, mainly with small and medium breeds, as they are the smallest brackets found in the market. Wrong bracket positioning can result in extra time treatment length for a better occlusion finalizing or appliance removal without the best possible result is achieved (Bennett & McLaughlin 1994). A correct bracket positioning reference is the center of clinical teeth crown, in mesiodistal way. The slot or bracket base angulations should follow the teeth long axis. In relation of the others teeth from the same arch, brackets positioning there are methods using medium crown teeth height or the vertical center of each clinical teeth crown (Sinha, & Nanda, 2004). In the treatment end, the brackets debonding can be done with debonding pliers, between enamel-resin or resin-bracket. The bracket is removed, leaving minimal amount of resin on teeth surface, which should be removed with finishing burs or periodontal scallers (Newman & Facq 1971).

Discussion and Conclusion: The use of corrective orthodontics fixed appliances in dogs can be an important way to achieve a better dental positioning and alignment, factor that can make buccal hygiene easier and buccal health better. However criterious indications parameters, well done planning and technique domain by veterinarian physician are clearly needed for fixed orthodontic appliances procedures. If there is a fully planned fixed orthodontic treatment protocol, these resources are efficient mechanics for a better dogs' buccal health.

References: Bennett J.C. & McLaughlin R.P. 1994. As mecânicas do tratamento ortodôntico e o aparelho pré-ajustado. Artes Médicas, São Paulo, p.55-65. - Burstone C.J. 1996. Aplicação da bioengenharia na ortodontia clínica p.213-42. In: Graber T.M. & Vanarsdall R.L. (ed.), Ortodontia: princípios e técnicas atuais. 2ª ed. Guanabara Koogan, Rio de Janeiro. - Cotrim-Ferreira F.A. 1997. Biomecânica do movimento dental, p.353-90. In: Ferreira F.V. (ed.), Ortodontia: diagnóstico e planejamento clínico. Artes Médicas, São Paulo. - Gioso M.A. 2003. Odontologia Veterinária para o Clínico de Pequenos Animais. 6ª ed. I editora, São Paulo. - Gioso M.A., Carvalho V.G.G. & Carvalho P.E.G. 2004. Construction of dental study models. J. Vet. Dent. 21(2):122-126. - Hennet P.R. & Harvey C.E. 1992. Diagnostic approach to malocclusions in dogs. J. Vet. Dent. 9(2):23-26. - Interlandi S. 1986. Ortodontia: mecânica do arco de canto, introdução à técnica. Sarvier, São Paulo, p.5-17. - Moyers R.E. 1991. Técnicas ortodônticas, p.438-478. In: Idem (ed.), Ortodontia. 4ª ed. Guanabara Koogan, Rio de Janeiro. - Newman G.V. & Facq J.M. 1971. The effect of adhesive systems on tooth surfaces. Am. J. Orthod. 59:67-75. - Proffit W.R. 1986. Contemporary orthodontics. Mosby, St Louis. - Sinha P.K. & Nanda R.S. 2004. Aparelhos ortodônticos fixos edgewise e técnicas de colagem, p.186-207. In: Bishara S.E. (ed.), Ortodontia. Santos, São Paulo.

INDEX TERMS: *Orthodontics, dogs, dental care, orthodontic appliances.*

009. Carvalho V.G.G. & Gioso M.A. 2007. **Perspectives of surgical treatment of skeletal malocclusion in dogs.** *Pesquisa Veterinária Brasileira 27(Supl.).* Departamento de Cirurgia, FMVZ-USP, São Paulo, SP, Brasil. E-mail: vanggc@uol.com.br

Introduction: The result of human selection of dog breeds is the major contribution of malocclusions; its severity and frequency have increased in the last years (Harvey & Emily 1993, Beard 1998). The occlusion and the teeth positioning should be the same in all kinds of breeds. However, the correct teeth positioning can be affected in result of a head shape, causing malocclusions (Shipp & Fahrenkrug 1992, Emily & Penman 1994). In consequence, the malocclusions in dogs sometimes can result in oral pain, by interdental contact or by the teeth lesioning soft tissues (Mitchell 2005). They can happen when there is a mal positioned tooth (Class I malocclusion) or when there is not a correct proportion between mandibular and maxillar length (skeletal malocclusions Class II and III) (Gioso 2003). The most common signs observed in animals with malocclusions can be: masticatory difficulties, problems in temporomandibular joint, caries formation, development of periodontal disease, problems on dental facial development, trauma in soft tissues, teeth fractures or abrasion. Each sign can be a reason to initiate an orthodontic treatment, to obtain a harmonious and correct occlusion (Wiggs & Lobprise 1997). Mal positioned teeth can be re-positioned with orthodontic appliances or can be extracted. However, there is no surgical procedure developed or described in literature for animals that allows the repositioning of the mandible and, at the same time, to preserve the vessels and the nerve of the mandibular canal (Carvalho 2004). Skeletal disturbances, in mandible or maxilla, can not be treated with orthodontic appliances exclusively because this kind of treatment acts specifically on the teeth and alveolar bone. The orthognathic surgery is a repair procedure, involving maxilla, mandible, including the alveolar bone (Medeiros 2001). The purpose of this study is to introduce and describe a technique, based on the humans orthognathic surgery techniques and in the paper "A dog instruction model for correction of mandibular prognathism" (Lohse 1977), that can permit mandibular repositioning by bilateral caudal sagital osteotomy of mandible, to rehabilitate Class II and Class III malocclusions that are causing trauma and pain (according to the ethical considerations), done in cadavers to re-establish the normal occlusion in these patients, analogous to human cases.

Materials and Methods: Twenty cadavers of dogs were used in this experimental study to define a proper technique of the orthognatic surgery in dogs. The used materials were the same surgical instrumentations used in major oral surgeries, dental equipment, X-ray (intra-oral and skull), micro-saw and instrumentation to bone fixation, like titanium screws (provided by Tóride Ind. e Com. Ltda). The technique consisted in a sagittal split osteotomy in the region of the last two mandibular molar teeth, bilaterally, that allows the movement of the mandible between the fragments, repositioning it in the correct occlusion and preserving the alveolar nerve and vessels that is present in the mandibular canal. The first step of the proposed technique is the extraction of the third and second lower molar teeth, exactly where the osteotomy is done. The mucosa is incised and the muscles dissected caudally and rostrally to

the lower first molar tooth, at both sides. First, an osteotomy line is drawn on bone with a very small spherical burr, from the mandibular foramen to the upper angle of mandible and another osteotomy line is done, with the same spherical burr, on the lateral cortical bone, caudal to the first lower molar tooth, parallel to the distal root of this tooth. This osteotomy needs to be extended ventrally, until the medial portion of the mandible. It is not necessary to make an osteotomy from the mandibular foramen to the ventral border of mandible because it is fractured by itself during the corticals separations. The micro saw initiates the split between the vestibular and lingual cortical bones of mandible, dorsal to the mandibular foramen, passing by the last two alveoli and finishing caudal to the first molar. The separation of the two cortical bones is done inserting the chisel (1mm in width) it into the retromolar osseous incision, tapping gently with a mallet. Next, the chisel is removed and then placed within the buccal osseous incision in a more horizontal position, and force is applied with a mallet. After separation of the lingual and vestibular bone fragments, the mandible is repositioned in a normal occlusion and the bones are fixed with three screw. To avoid movement during fixation procedures, helping the maintenance of the mandible in occlusion, orthodontics buttons is placed in the lower and upper canine teeth and in the upper third incisor tooth; a steel wire is placed between the buttons, blocking the open mouth. Most aspects of this technique need to be evaluated like final occlusion (over bite, premature contact, necessity of dental movement by orthodontic treatment before surgery), necessity of interdental block, stability of fixation and efficiency of the material used, percentage of success of the osteotomy, percentage of mistaken fractures and this locations, measurement of the mandibular advance and caudal movement and, the most important, the preservation of the vessels and nerve of the mandibular canal.

Discussion and Conclusion: The orthognatic surgery is a new opportunity to treat skeletal malocclusions, for some reasons related in literature like trauma and pain (Gioso 2003, Mitchell 2005). These problems are increasing and affecting more animals nowadays (Shipp & Fahrenkrug 1992, Harvey & Emily 1993, Emily & Penman 1994, Beard 1998) and any definitive treatment are being required for these animals. Each signs of trauma and pain caused by the malocclusion can be a reason to initiate an orthodontic treatment (Wiggs & Lobprise 1997). So, the orthognatic surgery can be a definitive treatment for the skeletal malocclusion (Medeiros 2001). The instruction model published by Lohse (1977) did not evaluate the positive and the negative points of the procedure and the technique described needs to be improved. Many studies about viability of technique and execution need to be done because this procedure is not simple. And more, it is necessary to develop an appropriated technique for dogs because there are some anatomical considerations to study and the surgical procedure needs to be effective with less damage to provide a good reestablishment of normal occlusion.

References: Harvey C.E. & Emily P.P. 1993.Small Animal Dentistry. Mosby, St Louis. - Beard G.B. 1998. Oclusão e Ortodontia, p.2774-2784. In: Slatter D. (ed.), Manual de Cirurgia de Pequenos Animais. Vol.2. 2ª ed. Manole, São Paulo. - Shipp A.D. & Fahrenkrug P. 1992. Practitioners's Guide to Veterinary Dentistry. 1st ed. Griffin Printing, California, p.8-15. - Emily P.P. & Penman S. 1994. Handbook of Small Animal Dentistry. 2ª ed. Pergamon Press, Oxford. - Mitchell P.Q. 2005. Odontologia de Pequenos Animais. Roca, São Paulo, p.144-48. - Gioso M.A. 2003. Odontologia Veterinária para o Clínico de Pequenos Animais. 6ª ed. I Editora, São Paulo. - Wiggs R.B. & Lobprise H.B. 1997. Veterinary Dentistry: Principles and Practice. Lippincott-Raven, Philadelphia. - Carvalho V.G.G. 2004. Ossos do sistema estomatognático e da articulação temporomandibular de cães e gatos: enfoque anátomo-cirúrgico. Dissertação de Mestrado, Faculdade de Medicina Veterinária e Zootecnia, Universidade de São Paulo, p.22-74. - Medeiros P.P. 2001. Cirurgia ortognática para o ortodontista. Santos, São Paulo, p.ix. - Lohse C.L. 1977. The dog as an instruction model for surgical correction of mandibular prognathism. J. Oral Surg. 35(1):17-20.

INDEX TERMS: Skeletal, malocclusion, dog, orthognathic, brachgnathism, prognathis.

010. Coffman C.R. & Visser C.J. 2007. **Periodontal regenerative surgery.** *Pesquisa Veterinária Brasileira 27(Supl.).* Aid Animal Dental Clinic, 7908 E. Chaparral Road, Scottsdale, Arizona, USA 85250. E-mail: curtcoffman@cox.net

Introduction: The high prevalence of periodontal disease in dogs and cats has been widely published. The most serious consequence is the loss of the periodontal support structure, which includes cementum, periodontal ligament, and alveolar bone. The treatment of periodontal disease in veterinary patients today can range from routine periodontal therapy including scaling and root planing, to advanced periodontal surgical procedures aimed at regenerating diseased periodontal tissues. Successful regeneration of periodontal tissues can offer an alternative treatment option to tooth extraction in cases of moderate to advanced periodontitis. The objectives of periodontal regeneration therapy for patients with periodontitis include probing depth reduction, clinical attachment gain, bone fill of the osseous defect, and regeneration of new bone, cementum, and periodontal ligament. Numerous case reports and controlled clinical trials have provided data on achieving the first three objectives. Only histopathology can accurately determine whether any true periodontal regeneration has developed. (Rosenberg & Rose 1998)

Literature Review: There are studies showing that cells of the epithelial root sheath synthesize enamel matrix proteins and that these proteins play a fundamental role in the formation of acellular cementum, the key in the development of a functional periodontium. (Hammarstrom & Heij 1997) It is reasonable to believe that the molecules involved in triggering the development of periodontal tissue are effective in promoting regeneration of periodontal tissues. (Caranza & McClain 2002) One enamel matrix protein derivative obtained from developing porcine teeth has been approved by the FDA for use in human periodontal surgery[a]. Studies have shown that enamel matrix protein derivative enhances regeneration of both hard (Heijl & Heden 1997, Boyan & Weesner 1999) and soft periodontal tissues (Mellonig 1999).

Discussion and Conclusion: The authors have successfully used enamel matrix protein derivative alone and in combination

with other graft materials in clinical cases as a treatment of the root surface and periodontal defect in conjunction with periodontal surgery. The most common site of use has been in deep periodontal pockets found on the palatal surface of the maxillary canine teeth in dogs. In this report clinical cases will be used to illustrate the use of enamel matrix protein derivative, alone and in combination with demineralized freeze dried bone[b,c], and synthetic bone graft particulates[d], to illustrate potential outcomes in surgical treatment of periodontal defects.

[a] Emdogain Gel, Biora Inc., Chicago, IL, USA.
[b] Grafton Bone Putty, Osteotech Inc., Eatontown, NJ, USA.
[c] Osteo-Allograft, Veterinary Transplant Services, Kent, WA, USA.
[d] Osteograf-N, Dentsply International Inc., Lakewood, CO, USA.

References: Boyan B. & Weesner T. 1999. Porcine fetal enamel matrix derivative enhances bone formation induced by DFDBA *in vivo*. J. Clin. Periodontol. 71:1278-1286. - Caranza F.A., McClain P. & Schallhorn R. 2002. Regenerative osseous surgery, p.812-813. In: Carranza (ed.), Clinical Periodontology. 9th ed. W.B. Saunders, Philadelphia. - Hammarstrom L. & Heijl L. 1997. Periodontal regeneration in a buccal dehiscence model in monkeys after application enamel matrix proteins. J. Clin. Periodontol. 24:667-677. - Heijl L. & Heden G. 1997. Enamel matrix derivation in the treatment of intrabony defects. J. Clin. Periodontol. 24:705-708. - Mellonig J..T. 1999. Enamel matrix derivative for periodontal reconstructive surgery. Int. J. Periodont. Res. Dent. 19:9-12. - Rosenberg E. & Rose L.F. 1998. Biological considerations for autografts and allografts in periodontal regeneration therapy. Dent. Clin. North Am. 42(3):467-490.

INDEX TERMS: Enamel matrix proteins, periodontal surgery.

011. Costa. R.C.S., Pinto N. & Aragão M.V. 2007. Methods of intra-oral radiographic localization.

Pesquisa Veterinária Brasileira 27(Supl.). Doctor Pet, Rio de Janeiro, RJ 23.082-220, Brazil. E-mail: cassiavetodonto@gmail.com

Introduction: The periapical x-ray is basic for an accurate diagnosis in Veterinary Dentistry, to identify certain buccal pathologies and to plan treatments. It is true what Gibilisco et al. (1986) say that "the attainment of satisfactory x-rays of teeth and adjacent structures is one of the difficulties and complicated technical problems in radiology". Cieszynskis (1907), according to its "Rule of the Bisecting Angle"or "Cieszynskis' Rule", based on an old geometric theorem, which establishes that two triangles are equal when they have two equal angles and a common side, idealized its rule that says: "The angle formed for the long axle of the tooth and the long axle of the film will result in a Bisecting Angle in which the beam of X-rays will have to happen perpendicularly". Thanks to technique developed by McCormack (1920) and perfected and divulged by Fitzgerald (1947), the technique of parallelism had its acceptance and diffusion in America and Europe. Lima (1953) presented a comparative study of the techniques of the Bisecting Angle and Parallelism, affirming that is a technique easy to learn and concluded that, when investigation of subtle alterations in the periapical and periodontal structures is necessary, the technique of Parallelism is superior to the one of the Bisecting Angle. He analyzes the techniques of intra-oral Bisecting Angle and Parallelism. Knowledge about radiographic techniques is the best and most secure way for a good treatment plan and therapy, and makes the difference between a good professional procedure and a poor one.

Materials and Methods: Five 5 Cocker Spaniel dogs of the same origin were selected for the study. After clinical dentistry exam, a radiographic intra-oral exam was performed to choose the best treatment plan and therapy for the case. The animals were submitted to the radiographic examination and the radiographic Periapical of the Intra-Oral Bisecting Angle and the Intra-Oral Parallel technique were used for a comparative study for application in the veterinary dentistry clinic. For the execution of the technique Intra-Oral Bisecting Angle three angles were calculated; the angle A is the long axis of the tooth, the angle B is the angle of the film and the angle C is the angle that bisects angle A and B; the beam is then directed at 90 degrees to angle C. The film was located in the lingual/palatine face of the teeth in a 90-degree arc. For the execution of the technique of the Intra Oral Parallel the film was located at the same way but the beam was angled at 90 degrees to the film and the target. The target tooth/teeth should be in the middle of the film and the surrounding structures included, when important, as for example the ventral border of the mandible. The dental films were processed manually.

Results: Regarding the technical procedures, some differences exist between the techniques of Intra Oral Parallel and Intra Oral Bisecting Angle; even so both have the same purpose that is the radiographic examination of the tooth and periapical region. The results with the Intra-Oral Parallel showed that if the angle between the tooth and the film is more than 15 degrees, the use of the Bisecting Angle technique prevents gross distortion of the image caused by increasing the Object Film Distance.

Discussion and Conclusions: The execution of the radiographic technique of Intra Oral Parallel and Intra Oral Bisecting Angle has its advantage because of its great simplicity, not being necessary to correct positioning of the patient's head, there are fewer radiographic images, and standardized radiographic examination, with the possibility of getting x-rays in different situations. In accordance with Gioso (2003) "… for maxilla teeth it is impossible to parallel juxtapose the film to the tooth, a good reason to apply the Bisecting Angle technique to get an image with dimensions next to the tooth", or still in accordance with Roza (2004), "in dogs and cats the technique of Parallelism is easily executable at the premolar and molar teeth"; The Intra-Oral Bisecting Angle is used in areas where the Parallel technique is impossible due to poor access (with an angle between teeth and film more than 15 degrees).

References: Cieszynski A. 1907. Ueber die Einstellung der Roentgenröhre bei Zahnaufnahmen. Corresp. f. Zahnärzte, p.158. - Cieszynski A. 1924. In defense of the rights of authorship of some fundamental rules of X-ray technique and accessories. Dent. Cosmos 66(6):656-664. - Fitzgerald G.M. 1947. Dental Roentgenography. II: vertical angulation, film placement

and increased object-film distance. J. Am. Dent. Assoc. 34(3):160-170. - Gibilisco J.A. 1986. Técnicas radiográficas. In: Gibilisco J.A. (ed.), Diagnóstico Radiográfico de Stafne. 5ª ed. Discos CBS, Rio de Janeiro, 24:379-429. - Gioso M.A. 2003. Odontologia para o Clínico de Pequenos Animais. 5ª ed. São Paulo, p.183-189. - Lima A.C.P.A. 1953. Técnica roentgenográfica dentária periapical do cone longo, comparada a do curto: contribuição ao seu estudo. Tese de Livre-Docência, Faculdade de Odontologia, Universidade de São Paulo, São Paulo. - McCormack F.W. 1920. A plea for a standardized technique for oral radiography with an illustrated classification of findings and their verified interpretations. J. Dent. Res. 2(3):467-490. - Roza R.M. 2004. Odontologia de Pequenos Animais. 1ª ed. Rio de Janeiro, 7:107-112.

INDEX TERMS: Bisecting Angle, Parallelism.

012. Cruz R.A., Santos C.F., Passos S.K. & Pires M.V.M. 2007. **Traumatic oro-nasal communication healing in cats (*Felis cattus*) by the ferulization technique.** *Pesquisa Veterinária Brasileira 27(Supl.).* Faculdade de Medicina Veterinária, Universidade Castelo Branco, Rio de Janeiro, RJ. Brazil. E-mail: drigow@predialnet.com.br

Introduction: Among all the described techniques for repair and fracture healing of the maxillary structure and mandibulary branches, the ferulization techinique (splint) has become an easily and non invasive option, besides promoting a quickly return to its stomatognatic function (Harvey & Emily 1993). The present report describes the case of a eight months old cat which was diagnosed as having a traumatic maxillary fracture with avulsion and a communication between oral and nasal cavities. The patient had the clinical and surgical procedures needed for its case, being the ferulization technique part of the treatment correcting the maxillary fracture and the iatrogenic communication.

Materials and Methods: In the reported case the patient described was a cat (*Felis cattus*), mixed breed, male, weighting 3.6 kg and estimated age of 8 months old. It had peri-domiciliary habits, being home just for feeding and resting in some moments of the day, while in absolute freedom to walk on the streets all day long. Till the clinical attendance, the owner denied any basical care to the animal, such as immunizations or antihelmintics. At the patient's evaluation at the end of the afternoon, the students evolved in the Veterinary Dentistry Lab figured that it had been hitting by a car in the morning. The physical examination revealed blood on the lips and nostril. At the oral inspection it was seen the avulsion of the canine teeth (#104) and the oro-nasal communication with presence of blood. After prescribing Ketoprofen (1.1mg/kg, PO, 24hr) and nebulization for five minutes at that night and the next morning, the animal was recommend to surgical treatment in the next day. At the surgical procedure, induction was made by the use of Propofol (6mg/kg, IV) and Isoflurane for maintenance. Analgesia was achieved with Morphine (0.1mg/kg, IM) and regional block with Lidocaine 2% (0.3ml infiltration on the infra orbitarian foramen) Both morphine and Lidocaine were administered after induction (Pinto & Mannarino 2004). Then, under anesthesia, intra oral radiographs in obliquous projection were taken, confirming the maxillary fracture clinical diagnose and the integrity of the teeth with it's apical root still open, a radiological sign of the presumed patient's age. After cleansing of the oral and nasal cavities with NaCl 0,9% and Chlorexidine 0.12% solutions, suture was performed with 3-0 absorbable polyglycolic wire between the borders of the hard palate and the gingival, what it conferred initial aspect of good reduction of the oral-nasal communication. After that, in order to confer stability to the avulsioned element the splint technique by means of acrylic resin application was carried through, using as anchorage points the superior canine teeth (#104 and #204), being prescribed well-taken care of postoperative with Cetoprofeno use (1.1mg/Kg, vo, SID, 5 days), Clindamicine (11mg/Kg, vo, SID, 5 days) and Clorexidine 0.12% (topical, BID, 30 days) (Gioso 2004) e the removal of the resin inside of 4 weeks, where, later, the root canal treatment would be carried through (French 2001).

Results: The stabilization of the avulsionated bone and tooth showed very satisfactory from the moment of total polymerization of the resin. The recover of the patient from its anaesthetic plain was calm, without vocalizations. The same it demonstrated small discomfort with the presence of the resin during first the 48 hours, what it disappeared in the sequence of its recovery, also with the alimentary habits of the animal returning spontaneously. Sneezing had not been observed, as well nasal discharge had also not been cited during the revision of the patient. The avulsionated segment remained steady after and without signals of muco-gingival alterations 3 weeks. It had profit of significant weight (180 grams) and compatible with the stage of development of the patient.

Discussion and Conclusions: The ferulization technique was demonstrated an easy option with a short-time surgery time, and it could be applied by academics under the supervision of its professors, and with fast adaptation of the patient after-surgical condition, in accordance with what Harvey & Emily (1993). The general anesthesic procedure, associate with the local block with lidocaína 2% promoted excellent analgesia to the patient, as Pinto & Mannarino (2004). The antibiotic use (clindamicina, vo) during the postoperative one was of great value in the prevention of infection of the superior aerial ways and of alveolite, as well as Gioso (2003). The delayed endodontic procedure indication based on the described procedures per French (2001), aiming at the correction of probable damages to the neural-vascular beam on the root canal of the avulsionated dental element. Being thus, the accomplishment of less invasive techniques must be stimulated and be practiced in the clinical routine, aiming at the good recovery of the patient and preservation of the dental elements and the perfect occlusion.

References: Harvey C.E. & Emily P.P. 1993. Small Animal Dentistry. Mosby, St Louis. - French S. 2001. Tooth Avulsion. Proc. 26th World Small Anim. Vet. Assoc. Congr., Vancouver. - Pinto M.A., Mannarino R. 2004. Anestesia em Odontologia Veterinária: aspectos farmacológicos e terapêuticos. In: Rosa M.R. (ed.), Odontologia em Pequenos Animais. L.F. Livros, Rio de Janeiro. - Gioso M.A. 2003. Odontologia para o Clínico de Pequenos Animais. Editco Comercial Ltda, São Paulo.

INDEX TERMS: Cat, fracture healing, splint, tooth avulsion.

013. DeBowes L.D. 2007. **Intraoral dental radiography of dogs and cats: positioning and technique.** *Pesquisa Veterinária Brasileira 27(Supl.).* Shoreline Veterinary Dental Clinic, Seattle, WA, USA. E-mail: ldebowes@aol.com

Introduction: Dental radiographs are an important part of the diagnosis, management, and monitoring of a variety of dental and oral disorders. Intraoral dental radiographs have several advantages over standard radiographic techniques including ease of making and better diagnostic quality. Quality intraoral dental radiographs are important for accurate interpretation. Proper positioning and technique are necessary for obtaining the best quality dental radiographs.

Literature Review: The dental film sizes most commonly used in dogs and cats are the size 2 (periapical) film (1 1/4" x 1 5/8", 31 x 41mm) and size 4 (occlusal) film (2 ¼" x 3", 57 x 76mm). The film speed (A,B,C,D,F) refers to the film sensitivity. The sensitivity of the film determines the required exposure time. The faster speed (higher sensitivity) film requires less radiation to expose (blacken) the film. Commonly used film speeds include D speed and F speed (Kodak Insight ©). Film packets come in single film packet (make one radiograph), double film packet (makes two identical radiographs), and duplicating film (to make duplicate radiograph). The film packet packaging includes an exterior nonabsorbent plastic envelope, a black paper light barrier, and a thin sheet of lead foil (stippled embossment pattern). Errors made during film processing affect film quality.

Discussion and Conclusion: Dental films may be developed in one of several ways; chair side developing system using rapid developers and fixers, automatic processor, regular dip-tanks, small containers in the dark-room (rapid developers and fixers), and automatic processor. When positioning for an intraoral dental radiograph the film or sensor (digital radiography) is oriented in the patient's mouth (intraoral) with the front towards the x-ray tube. The dimple (embossed circle in one corner) in film is positioned away from the area of interest. Mobile dental x-ray machines are recommended. The basic positioning (film and tube-head) techniques include the parallel technique (film is parallel to the axis of the tooth roots) and the bisecting angle technique. The parallel technique is primarily used with the distal mandibular teeth. The bisecting angle technique is used for the other teeth where the film cannot be placed parallel to the tooth. The bisecting angle technique is used to prevent/minimize image elongation or foreshortening. The film is placed intraoral as close to the tooth as possible and the x-ray beam (tube-head) is positioned perpendicular (right angle) to an imaginary line that bisects the angle formed between the film and the roots of the teeth being radiographed. Shifting the tube head in the third axis while maintaining the bisecting angle in the plane is used to separate structures avoiding superimposition of radiograph. Special considerations are made for the maxillary premolar teeth in the cat where the tube head is positioned ventrally to drop the x-ray beam under the zygomatic arch (results in slight elongation of the roots) and allow for better visualization of the tooth roots.

References: Mulligan T.W., Aller M.S. & Williams C.A. 1998. Atlas of Canine and Feline Dental Radiography. VLS, Trenton, NJ.

INDEX TERMS: Intraoral dental radiographs, dental film, positioning for dental radiographs.

014. DeBowes L.J. 2007. **Use of esophageal feeding tube after oral surgery.** *Pesquisa Veterinária Brasileira 27(Supl.).* Shoreline Veterinary Dental Clinic, Seattle, WA, USA. E-mail: ldebowes@aol.com

Introduction: Esophagostomy tubes (E-tubes) are relatively easy and fast to place and are an excellent method for feeding patients with oral problems that are unable or unwilling to eat. An E-tube may be left in place and used for short or long-term (weeks to months) feeding. Bolus feedings of a blended canned diet is generally acceptable when using a large-bore feeding tube in these patients. The most common complications are infection at the site where the tube exists through the skin and obstruction of the feeding tube.

Literature Review: Indications for placing E-tube are the inability to eat (i.e. jaw fractures, head trauma, painful oral conditions) and inadequate consumption of required calories for maintenance and recovery (i.e. painful oral conditions such as stomatitis, glossitis). Contraindications for placing an E-tube are an esophageal or gastric disorder and the risk of aspiration pneumonia (i.e. comatose patient). Recommended E- tube size for cats are 14 to 18 Fr. and for dogs are 20 to 24 Fr.

Discussion and Conclusion: The steps for esophagostomy feeding tube placement using the curved forceps technique are: 1) general anesthesia with tracheal intubation; 2) position patient in right lateral recumbency; 3) clip hair and aseptically prepare surgery site; 4) prepare the feeding tube (premeasure, mark, enlarge openings); 5) extend the neck, pass curved end of forceps into midcervical esophagus; 6) make incision through skin and tissues to exposed tip of forceps; 7) push the forceps through incision and grasp distal end of the feeding tube; 8) withdraw the forceps from esophagus bringing distal end of tube into the oral cavity; 9) redirect the distal end of the tube into the esophagus; 10) position tube so that it ends in the distal esophagus (premeasured); 11) secure tube to the cervical skin using a Chinese finger-trap friction suture; and 12) cap end of tube and lightly bandage. The basic feeding instructions are: 1) Feed blended canned food (blended with water or Clinicare); 2) Feed a minimum of three bolus feedings daily; 3) the volume per feeding (approximate starting volume) for a normal dog and cat 80ml/kg BW, for anorexic patients 30-40ml/kg BW; 4) Reduce volume if vomiting occurs; 5) Calculate resting energy requirement (RER), Exponential equation RER = RER =

$70(BW_{kg})^{0.75}$ (use for patients 2 to 25 kg), Linear equation RER = $30(BW_{kg}) + 70$ (use for patients <2kg); and 6) Flush tube and cap after each feeding. - Selected commercial products suitable for E-tube feeding and calorie content (kcal/ml or g) (taken from Remillard R.L. et al. Small Animal Clinical Nutrition. 4th ed.) are: Hill's Prescription Diet Canine/Feline a/d (1.3), Iams Eukanuba Maximum Calorie/Canine and Feline (2.1), Select Care Canine Development Formula (0.9), Select Care Feline Development Formula (1), Waltham/Pedigree Concentration Diet/Canine (1.4), Waltham/Whiskas Concentration Diet/Feline (1.2), Abbott CliniCare Canine (1), Abbott CliniCare Feline (1), Abbott CliniCare RF Feline (1). The steps for E-tube care and removal include: 1) Daily clean area around tube site to decrease chance of infection; 2) Remove E-tube when patient eating sufficient quantity to maintain weight; and 3) Release E-tube by cutting sutures and gently remove. The opening will seal rapidly and the site will heal in a few days.

References: Remillard R.L, Armstrong P.J. & Davenport D.J. 2000. Assisted feeding in hospitalized patients, enteral and parenteral nutrition, p.371-375. In: Hand M.S., Thatcher C.D., Remillard R.L. & Roudebush P. (ed.), Small Animal Clinical Nutrition. 4th ed. Mark Morris Institute, Topeka, KS. - Seim H.B. & Bartges J.W. 2003. Enteral and parenteral nutrition, p.416-462. In: Tams T.R. (ed.), Handbook of Small Animal Gastroenterolgy. Elsvier-Saunders, St Louis, Missouri. - Zoran D.L. 2006. Nutrition for anorectic, critically ill or injured cats, p.145-149. In: August J.R. (ed.), Consultations in Feline Internal Medicine. Elsevier-Saunders, St Louis, Missouri. - Hand M.S., Thatcher C.D., Remillard R.L. & Roudebush P. 2000. Esopagostomy tube placement, p.114-149. In: Hand M.S., Thatcher C.D., Remillard R.L. & Roudebush P. (ed.), Small Animal Clinical Nutrition. 4th ed. Mark Morris Institute, Topeka, KS.

INDEX TERMS: Esophagostomy tubes, E-tubes, enteral feeding.

015. DuPont GA. 2007. Debunking the myth. *Pesquisa Veterinária Brasileira 27(Supl.).*

Shoreline Veterinary Dental Clinic, Seattle, WA, United States. E-mail: GatorGregg@aol.com

"It is the right and duty of dentists to constantly criticize dogma and investigate the justification for current standards of practice. Therefore, to challenge ...recommendations is a professional obligation. It is also a definite necessity." Dr. John Hardie

Introduction: The practice of evidence based dentistry includes five steps: 1) Create an answerable question to a clinical problem; 2) Search for and find the best evidence to answer it; 3) critically evaluate the information you have found; 4) apply it to your patient; and 5) evaluate the results. Evidence based veterinary dentistry makes use of scientific research to provide the best solutions and treatments for existing problems. The result is a high (or at least a predictable) procedural success rate. Unfortunately, there is only very poor evidence available for many of the decisions that we make every day. This problem was even more widespread in the past, and many "facts" that have been accepted for years are wrong because they were based on inaccurate information. Sometimes even the most basic and universally accepted concepts are nothing more than unverified and completely false myths. As a result, we must always remember some of the other fundamental tenets of science: 1) Avoid dogma by critically reviewing previously interpreted data; 2) apply consistent reasoning; and 3) question the validity of authoritative pronouncements. Applying these tenets can result in dramatic changes in thinking, and even complete paradigm shifts. Well known examples include Pasteur's blasphemous insistence that micro-organisms exist and cause infection, and Lister's equally "ridiculous" claim that scrubbing for surgery might decrease the high rate of surgical infections. In each area within the field of dentistry there are examples of concepts that have changed or that should be questioned.

Literature Review: Following are some examples of facts that contradict currently held beliefs, or areas where the evidence is unclear.

Endodontics

- Causes of treatment failure. Various studies show that coronal leakage of the restoration, inadequate canal obliteration, or inadequate canal cleaning are all equally or more important than apical leakage.
- The best canal flushing materials. Chlorhexidine vs antibiotic solution vs NaOCl. More concentrated bleach is more effective. Warming and agitating the bleach also increases its effectiveness.
- Some people believe that all root canal materials should be strictly controlled completely within the root canal system while others believe the apex should be instrumented and an apical "blush" of sealant should pass through into the periodontal ligament space
- Surgical endodontic treatment vs conventional retreatment of a failed case
- The recommendation that root canals be filed and filled to 1mm short of the apex does not transfer from humans to veterinary patients.
- Nickel-titanium files may navigate curves nicely but they also fail without warning compared to stainless steel.
- The root canal is not always in the center of the root.
- A corollary – the canal should not always be instrumented to a circular cross section so the file can clean all walls.
- Clean white dentin shavings do not indicate that filing is complete.
- The step-back technique to enlarge the root canal coronally is inferior to modified crown-down methods.
- The old method of rotating K-files counter-clockwise with balanced force, then ¼ turn clockwise to advance, then counterclockwise again should not be routinely used. In specific instances this is valuable, but it pushes the dentin mud apically.
- The pulp chambers in veterinary patients should not be "uncapped" as has been done in human patients.
- Is the choice of obturating material important? Is the quality of the 3-dimensional obturation important? Is the sealant the most important material in both type used and placement?
- Radiographic evidence of pulp obliteration (calcific metamorphosis) does not indicate that there is no longer pulp tissue present.

- Vital direct pulp cap with mineral trioxide aggregate (or similar material) seems to be much better that the older $Ca(OH)_2$.
- After vital direct pulp capping, follow-up radiographs that show the presence of a dentin bridge is not radiographic proof of procedural success; it only indicates the pulp survived the procedure.

Periodontal treatment

- Gingivitis is reversible, but so is periodontitis!
- Untreated gingivitis does not cause, and lead to, periodontitis.
- Periodontitis is associated with many systemic diseases including remote lesions, cardiovascular disease, low birth weight babies, and pulmonary disease. However it has yet to be proven to cause them.
- The merits of polishing teeth with each dental cleaning outweigh the resultant enamel loss. The human debate spills over to veterinary dentistry in the minds of some.
- Periodontal pockets should not be treated by gingivectomy unless they are pseudopockets.
- Wide based mucogingival flaps cut across blood vessels. Incisions in the mucosa should be oriented vertically.
- Mucogingival flaps should be coronally repositioned instead of apically repositioned.
- When and how to use systemic antibiotics remains controversial.

Operative dentistry

- Dental caries is not caused by the dreaded tooth worm. Pouring molten metal into the affected tooth may help but not because it killed the worm J
- Newer bonding agents with fewer bottles and fewer steps are not as strong as the older wet-bonding systems.
- Although amalgam is rarely used it remains the strongest material available for direct placement restorations and has the highest long-term success rate.
- $Ca(OH)_2$ should not be used for indirect pulp exposures.
- Composite resins do not move towards the activating light.
- Fast cures are detrimental to the bond.
- Cavity preparations should not be extended for prevention of recurrent disease.
- Unsupported enamel is no longer an important concept with modern restorative materials and techniques.
- Undercuts in cavity preps should not be made with an inverted cone bur.
- Crown preparations do not need a 3 – 5 degree taper with modern cements.
- Dental resorption lesions in humans cause discomfort only when they are intraoral.

"Half of what we know is wrong…but which half?"

"Follow the strongest evidence, wherever it leads"

Discussion: Advances in treatment are only possible by questioning the limits imposed by, and the rationale behind, traditional treatments. Nothing can ever be finally proved to be true. It can only be shown repeatedly that studies (so far) confirm it is not false. Science progresses by constantly challenging existing views and attempting to prove them wrong. Always question. Steven Pinker, an experimental psychologist at Harvard, made the assertion in his essay in the book Curious Minds: "Don't believe a word of what you just read in this paper. Don't believe a word of what you read in the other papers either." Conferences and Proceedings are very low-level evidence. Each author has made an honest effort to share with you the results of their research, and has invested a significant amount of their time to do this for you. It is therefore quite likely that their information is relatively good. Unfortunately, since few of us have the time to properly research and evaluate the available evidence in all areas of practice, we listen to experts and trust them to some extent. As Jamie Whyte shares, "no one can do it all themselves – it is a necessary division of labor".

Conclusion: Question everything regardless of how well established it is. Evaluate the quality of the supporting evidence. Be willing to change your beliefs when the evidence shows that they were wrong.

References: Baum L., Phillips R.W. & Lund M.R. 1995. Textbook of Operative Dentistry. Saunders, Philadelphia. - Cohen S. & Burns R.C. 1994. Pathways.of the Pulp. 6th ed. Mosby, St Louis. - Gibilesco J.A. 1985. Stafne's Oral Radiographic Diagnosis. W.B. Saunders, Philadelphia. - Ricucci D., Pascon E.A., Ford T.R. & Langeland K. 2006. Epithelium and bacteria in periapical lesions. Oral Surg. Oral Med. Oral Pathol. Oral Radiol. Endod. 101(2):241-251. - Stock C.J.R. et al. 1995. Color Atlas and Text of Endodontics. 2nd ed. Mosby-Wolfe, London. - Verstraete F.J.M. 2003. Oral Pathology. Slatter D. (ed.),Textbook of Small Animal Surgery. Vol.2. 3rd ed. Saunders, p.2638-2651. - Walton R.E. 1989. Torabinejad M. (ed.), Principles and Practice of Endodontics. W.B. Saunders, Philadelphia

INDEX TERMS: Debunk, evidence based dentistry, literature inaccuracy, myth.

016. DuPont G.A. 2007. **Digital radiography in veterinary dentistry**. *Pesquisa Veterinária Brasileira 27(Supl.).* Shoreline Veterinary Dental Clinic, Seattle, WA, United States. E-mail: GatorGregg@aol.com

Introduction: Adequate numbers of quality radiographs are essential for dental and oral diagnosis, treatment planning, procedural decision making, follow-up evaluation and medical record keeping. The status and health of the dental pulp and roots can only be fully evaluated by adding radiographs to the other observational information acquired on an oral examination. Without this valuable tool we are truly working "in the dark", missing lesions and disease processes, and only guessing at the quality and success of treatment. Dental radiography is greatly facilitated by having a dedicated dental x-ray unit in the dental operatory, instantly available radiographs, ability for fast re-takes, image enhancement, and enlargement. Conventional radiography falls short in many of these areas.

Literature Review: Digital radiograph units replace the dental film with a sensor. Dental films do not use the intensifying screens that are used in cassettes for standard radiographic film. As a result dental films require much higher doses of radiation to expose them. More sensitive films (E and F speed) require far less radiation than the older films but still use high doses. One of the advantages of digital radiography is the high sensitivity of the sensors. Current sensors of most systems require one tenth the radiation of the commonly used D speed film. Conventional radiographs

are produced when the radiation that has not been absorbed by tissues travels completely through the subject and acts on the photographic emulsion surface of an acetate film. Digital radiography uses a either a charge coupled device (CCD) or a complementary metal oxide semiconductor (CMOS) sensor in place of x-ray film to record the image. The information is transferred to a computer, which then forms an image and displays it on a monitor. Software allows manipulation of the image to enhance viewing. Enhancements might include increasing or diminishing contrast and brightness, adding color, or changing between positive and negative images. The software also provides additional information, such as measured distances, histogram analysis of radiographic density, and magnification of the image on demand. Images are saved on disk for long-term storage, and can be printed for sending with the owner or included in the patient's chart.

Advantages of digital systems:

- Less radiation needed for radiographs.
- Instant images - the radiographic image takes from less than a second to almost three seconds (depending on the system) to appear on the monitor. There is no delay while waiting for film to develop.
- Images can be rejected or retaken immediately - the software allows immediate evaluation and re-take, followed by the ability to select which exposure is preferred.
- Developing fluids are not needed. This results in a savings in supplies purchases, but more importantly a savings in time. It also resolves the problem of disposal of silver-contaminated fixing solutions.
- No x-ray film - again, no need to purchase film, plus time related to responsible and legal disposal of lead backings from film packets. Also eliminates film developing artifacts.
- The CCD and CMOS sensors are firm, eliminating image distortion caused by bending the film.
- Allows for image manipulation to improve interpretation accuracy.
    - positive/negative
    - colorization - positive and negative colorization give separate color schemes, which can be customized
    - enlargement
    - histogram
- Ability to measure anatomical structures directly from image or relative to a known distance.
- Print-out of radiographs for clients and for referring veterinarians - film images are automatically oriented and positioned by the software. This produces a "reader-friendly" print out presenting an image of the mouth similar to a panoramic radiograph.
- Automatic generation of referral letters.
- Ability to export images for e-mailing to clients or veterinarians.
- Ability to import images for enlargement or image manipulation.
- Ability to import digital photographs into the study.

Discussion: There are also some disadvantages to the digital system. The biggest is the initial expense. While the cost of digital systems has dropped over the past few years, most systems in the US cost between $6,000 - $10,000 US. This includes the sensor and the software. The X-ray machine used must have the ability to make fast exposures at 0.01 to 0.05 seconds; the working range for radiographs taken with most digital systems at 60-70 kVp and 7-15 mA. Older x-ray machines can not produce these low exposures, and if a new X-ray machine is needed then an additional $3,000 US must be invested. Another minor disadvantage is the size of the sensor. It is comparable to a size 2 dental film. For very large canine teeth, 2 views are needed to get both the crown and the root apex. Nasal radiographs, which are best viewed on a size 4 film, can be difficult to read on the smaller digital image. Positioning can initially be a little more technique sensitive since gravity acts on the heavier sensor, and the connecting wire can also pull on it. There are also wireless sensors, but we prefer those with a wire to avoid misplacing the sensor. When we first purchased our system in 1995 there were only a few manufacturers. Now there are many systems available. Image quality is one variable between them. Just as important is the software and user-friendliness; a powerful and versatile software that is difficult to navigate is both unnecessary and a liability, while one that performs all the basic and important functions in an easy-to-use and efficient fashion rates highly with us.

Conclusion: A dedicated dental x-ray unit should be considered basic equipment for any veterinary hospital that performs dental procedures. Digital radiography offers many advantages over use of emulsion film. The only significant disadvantage is the expense.

References: Borg E., Källqvist A., Gröndahl K. & Gröndahl H. 1998. Film and digital radiography for detection of simulated root resorption cavities. Oral Surg. Oral Med. Oral Pathol. Oral Radiol. Endod. 86(1):110-114. - Kravitz L.H., Tyndall D.A., Bagnell C.P. & Dove S.B. 1992. Assessment of external root resorption using digital subtraction radiography. J. Endod. 18(6):275-84.

INDEX TERMS: CCD, CMOS, dental radiograph, digital radiography, x-ray sensor.

017. Fecchio R.S.[1], Gomes M.S.[2], Kolososki J.[3] & Gioso M.A.[1] 2007. **Study of the adherence of acrylic resin in fractures of rhinotheca of toucans (*Ramphastus toco*).** *Pesquisa Veterinária Brasileira 27(Supl.).* [1]Laboratory of Comparative Dentistry (LOC), Faculdade de Medicina Veterinária e Zootecnia (FMVZ), USP, São Paulo, Brazil; [2]São Bernardo's Zoo; [3]College of Industrial Engineering, FEI. E-mail: bob_vetmeto@yahoo.com.br

Introduction: The avian beak is a continuously growing, dynamic structure composed of bone, vascular layers, keratin, dermis, joints and a germinative layer (Rupley 1999). In psittacine birds, the upper and lower jaws are connected to the skull via a kinetic joint (Ritchie et al. 1994). The keratinized sheath covering the upper and lower beaks is called rhamphotheca and can be divided into the rhinotheca (maxillary keratin) and the gnatotheca (mandibular keratin) (Altman 1997). The median dorsal border

of the rhinotheca is called the culmen, and the median ventral border of the gnatotheca is called the gonys. The edges of the rhamphotheca are called the tomia. The rhinotheca is perforated by the paired nostrils. Aviculturists classify caged birds into hardbills (e.g., most psittacine birds) and softbills (eg, mynahs, starlings). In ducks and parrots, the tip of the bill contains well developed mechanoreceptor nerve endings (Rupley 1999). The beak is used for prehension, for the physical preparation of food, and in some species such as parrots, for locomotion (Ritchie et al. 1994). The rate of keratin replacement is strongly dependent on the use of the beak. In large parrots, the complete rhinotheca is replaced in about six months, while in toucans the rhinotheca grows approximately 0.5cm over a two-year period. The rate of growth of the gnatotheca is about two to three times faster than that of the rhinotheca. A variety of congenital and acquired defects, including scissor beak and mandibular prognathism, can interfere with normal beak function. Examples of acquired lesions that can lead to malformations or necrosis of the beak include punctures, lacerations, splits and avulsions. Traumatic fractures, especially of the mandible, occur frequently in psittacine birds that get caught in hooks suspended from the ceiling of their enclosures or as a result of fighting (Ritchie et al. 1994). The present work has the aim of studding the forms of fixation of the rhinotheca fractures in toucans, with the use of acrylic resin. In order to simulate the forces that the beak is submitted to during feeding, we opted for the accomplishment of flexing tests essays.

Materials e Methods: Five beaks, removed from dead animals, were used to study the forms of fixation with the use of acrylic resin. The proximal extremity of the beaks was set in a support of epoxy resin while the distal extremity was set with a nylon fastener. This nylon fastener was connected to the movable headstock of a dynamometer through a brace of steel.

Results: The intact beak was fractured in the central portion when submitted to traction of 270.4 N, with displacement of 22.59mm. The location of this fracture served as orientation for the fractures induction in other beaks. The second beak received the resin in the two laterals and it presented resistance up to 69.75 N in 10.35mm. The third beak was submitted to acid conditioning for 60 seconds before the fixation of the resin and it resisted a force of 63.29 N in displacement of 6.73mm. Other two new tests were accomplished with the fourth and fifth beaks, being filled out the whole surface of the rhinotheca, besides the palate. The fourth beak was not submitted to the acid attack and it resisted up to 134.4 N in displacement 17.18mm and, the fifth was submitted to the acid etch and it resisted up to 101.5 N in displacement of 9.79mm.

Discussion and Conclusion: Statistical correlation and, consequently, differences among the procedures (with previous use of acid attack and those without the use of the same) were not observed in this study. Besides, it was noticed that the problem of repairing of the beaks seems to be related to the adherence of the resin to the keratin and not to its resistance. Still, the fixation to the palate provides larger resistance than that when it is used only on the lateral faces of the rhinotheca.

References: Altaman R.B. 1997. Avian Medicine and Surgery. W.B. Saunders Company, Philadelphia. - Ritchie B.W., Harrison G.J. & Harrison L.R. 1994. Avian Medicine: principles and application. Wingers Publ., Florida. - Rupley A.E. 1999. Manual de Clínica Aviária. Roca, São Paulo.

INDEX TERMS: Toucans, rhinotheca, fracture, acid etch, beak.

018. Felizzola C.R. 2007. **Chemotherapy in oral cancer**. *Pesquisa Veterinária Brasileira 27(Supl.).*

Rua Antônio Alves Magan 124, São Paulo, SP 01251-150, Brazil. E-mail cfronca@globo.br

Introduction: Cancer in small animals is the most common death in dogs in USA. In Brazil, you can see increase the frequency of cancer in pets and owner's preoccupation with his animal. Chemotherapy has been utilized since 60s decade in Veterinary Medicine in tumors like TVT, after in lymphoma and solid tumors (Chun et al. 2001, Almeida et al. 2005). The aim of chemotherapy treatment is utilized antineoplasic drugs the in form neoadjuvant, adjuvant or together a treatment with radiotherapy or surgical (Felizzola et al. 2003). There are many histologic types of oral cancer, who response chemotherapy, but the most frequents squamous cell carcinoma, lymphomas and sarcomas (Olgivie et al. 1989). In oral neoplasms adjuvant chemotherapy would be recommended due to its aggressive local and systemic phenotype (Zwahlen et al. 1989).

Materials and Methods: The aim of this study is utilization chemotherapy in treatment of oral tumors for decreases the recurrence of cancer or local or distance metastasis. Neoadjuvants used before surgical for reduce size of neoplasia thus facility surgical resection. Adjuvant treatment in animals, which has dirty margin or incomplete margin or presence microscopic disease are utilized. A chemotherapy strategy in the treatment of cancer is based on the used of pharmacologic agents aimed at forcing cellular differentiation. There are necessary before decide used chemotherapy agents to know which cancer and to do study clinical and laboratory the animal (dog and cat). Need do some biopsies and study histopathological and immunohistochemistry for choice the best chemotherapy and staged the disease. Staging is at two levels: clinical staging (TNM classification) and pathologic staging (depth invasion, grade, vessel and lymphatic invasion). Common drug used for chemotherapy: carboplatina, cisplatin, cyclophosphamide, doxorubicin, methotrexate, vincristina. Used single agents or in protocol multi agents depend the protocol used.

Discussion and Conclusion: The chemotherapy could increase the survival of animals and your quality of life, and reduce the recurrence. Manny authors no know effective adjuvant chemotherapies for oral cancer, but when correctly used you cam improve the survival of dogs. The important point is, use the correct chemotherapy for type of cancer, and study this drug for this patient. There are many preconception for use chemotherapy for the owner and veterinaries, but we will be need change the point of view, because the animal could be tolerate better than human when used chemotherapy. In conclusion a chemotherapy associate a surgical treatment increases a survival in patients.

References: Almeida V.L., Leitão A., Reina L.C.B., Montanari C.A. & Donnici C. 2005. Câncer e agentes antineoplásicos ciclo-celular específicos e ciclo-celular não específicos que interagem com o DNA: uma introdução Quim. Nova 28(1):118-129. - Chun R., Garret & MacEwen E.G. 2001. Cancer Chemotherapy, In: Withrow S.J. & MacEwen E.G. (ed.), Small Animal Oncology. 3rd ed. Saunders, Philadelphia. - Felizzola C., Martins M., Araujo N., Araujo,V. & Sousa S. 2003. Oral neoplasms in domestic animals. Oral Surg. Oral Med. Oral Pathol. Oral Radiol. Endont. 96(3):305. - Olgivie G. & Moore R. 1989. Phase II evaluation of doxorubicin for treatment of various canine neoplasms. J. Am. Vet. Med. Assoc. 195(10):1580-1587. - Zwahlen C.H. 1998. Results of chemotherapy for cats with alimentary malignant lymphoma. J. Am. Vet. Med. Assoc. 213(12):1144-1148.

INDEX TERMS: Chemotherapy, oral cancer, dogs.

019. Felizzola C.R. & Barbuto J.A. 2007. **Vaccine therapeutics for treatment of malignant melanoma**. *Pesquisa Veterinária Brasileira 27(Supl.).* Rua Antônio Alves Magan 124, São Paulo, SP 01251-150, Brazil. E-mail: cfronca@globo.com

Introduction: Cancer in small animals is the most common occurrence of death in dogs in USA. In Brazil, you can see an increase of the frequency of cancer in pets and owners' preoccupation with their animals. Canine malignant melanoma (CMM) of the oral cavity, nail bed, foot pad, and mucocutaneous junction is a spontaneous, highly aggressive neoplasm that can readily metastasize to the lymph nodes, liver, lung, and kidney. Oral malignant melanoma is a neoplasm most common in dogs (Felizzola et al. 2003). These dogs with oral melanoma, which are submitted to many treatments, radical surgery and radiotherapy, seem to have poor survival of only one year, and the prognosis depends on clinical and World Health Organization stage of the tumor. Metastatic diseases decrease quality of life of the dog, and sometimes the owner decides to euthanize the animal. New treatments have been used to fight these diseases as with therapeutic vaccines. The vaccine will activate the immune system, control the neoplastic growth, stabilize the disease or decrease the tumor (Banchereau & Steinman 1998, Barbuto et al. 2004). There are many types of vaccines, prepared with dendrite cells, DNA, RNA and activator substances (Cao et al. 1999, Banchereau et al. 2000, Bergman et al. 2003, Bianco et al. 2003). The present paper leads with an antitumor vaccine for dogs with malignant melanoma. New therapies have been studied, including anti-tumor vaccines which show good results.

Materials and Methods: The aim was to develop, to improve the production and to apply a vaccine for treatment of canine malignant melanoma. The response to the vaccine was checked by clinical examination, ultrasound, X-ray of primary or metastatic lesions. All dogs received the vaccine until 21 days for three times, and the patient was controlled every 3 months until its death.

Results, Discussion and Conclusion: The treatment of dogs with oral malignant melanoma showed 9 months of survival, and further research with vaccines could increase the survival time. The results proved to have stabilized the disease, like in human patients who received the same treatment. The vaccine is not toxic, and doesn't cause effects in the patients like chemotherapies. Melanoma is the most immunogenic solid tumor and, as such, has served as the major model for tumor vaccine investigation in both the laboratory and the clinic. This vaccine is unique for dogs and is a new therapy with good results.

References: Banchereau J. & Steinman R.M. 1998. Dendritic cells and the control of immunity. Nature 392:245-252. - Banchereau J., Briere F., Caux C., Davoust J., Lebeque S., Liu Y.J., Pulendran B. & Palucka K. 2000. Immunobiology of dendritic cells. Annu. Rev. Immunol. 18:767-811. - Barbuto J.Á., Ensina J., Neves A.R., Bergami-Santos P.C., Leite K.R.M., Marques J.R., Costa F., Martins S.C., Camara-Lopes L.C. & Buzaid C. 2004. Dendritic cell-tumor cell hybrid vaccination for metastatic cancer. Cancer Immunol. Immunother. 53:1111-1118. - Bergman P., McKnight J., Novosad A., Charney S., Farrelly J., Craft D., Wulderk M., Jeffers Y., Sadelain M., Hohenhaus A.E., Segal N., Gregor P., Engelhorn M., Riviere I., Houghton A. & Wolchok J. 2003. Long-Term survival of dogs with advanced malignant melanoma after DNA vaccination with xenogeneic human tirosinase. Clin. Cancer Res. 9:1284-1290. - Bianco S., Sun J., Fosmire S., Hance K., Padilla M., Ritt M., Getzy D., Duke R., Withrow S.J., Lana S., Matthiesen D., Dow S., Bellgrau, Cutter G., Helfand S. & Modiano J. 2003. Enhancing antimelanoma immune responses through apoptosis. Cancer Gene Therapy 10:726-736. - Cao X., Zhang W., Wang J., Zhang M., Huang X., Hamada H. & Chen W. 1999. Therapy of established tumor with a hybrid cellular vaccine generated by using granulocyte-macrophage colony-stimulating factor genetically modified dendritic cells. Immunol. 97:616-625. - Felizzola C.R., Martins M., Araújo N., Araújo V. & Sousa S. 2003. Oral neoplasms in domestic animals. Oral Surg. Oral Med. Oral Path. Oral Rad. End. 96(3):305.

INDEX TERMS: Vaccines, cancer, malignant melanoma.

020. Felizzola C.R. & Sousa S.C.M. 2007. **Clinical and patological study of the malignant oral tumor in cats**. *Pesquisa Veterinária Brasileira 27(Supl.).* Departamento de Patologia Bucal, FO-USP, Rua Antônio Alves Magan 124, São Paulo, SP 01251-150, Brazil. E-mail cfronca@globo.br

Introduction: Oral cancer is 5.4% of all cancer in domestic animal (canine, feline, equine and bovine), (Dorn & Priester 1976) furthermore in feline oral cancer is 3 % of all cancer (Moore &Olgivie 2001) The most common oral tumor in cats is malignant and they have a poor prognostic (Stebbins et al. 1989, Bertone 2003, Have been reported over 20 types of oral cancer in felines, but only few are observed commonly. Among the more common feline oral cancer are squamous cell carcinoma (SCC), fibrosarcoma (FSA) lymphoma (LSA) and malignant melanoma (MM). Squamous cell carcinoma is account about 70% of all feline oral tumors. Squamous cell carcinoma (SCC) is an aggressive and common oral neoplasm of the domestic

cat. SCC is highly locally invasive and frequently ulcerative and may cause lytic change in underlying bony structures. These tumors have a relatively low rate of metastasis but may spread to regional lymph nodes and, rarely, the lungs. Female cats and cats with a shorthaired coat might have an increased likelihoodof *p53* overexpression when have SCC oral. (Snyder et al. 2004), Without treatment, affected cats are usually euthanatized within 4-6 weeks of diagnosis because of complications associated with local disease. The etiology isn't clear, and a clinical cure is not possible. Neoplasia must be suspected in all lesions of the feline oral cavity where an obvious cause is not clear. The first step towards treatment of feline oral neoplasia is establishing a correct diagnosis based on a biopsy. Common presenting signs for cats with oral neoplasia include: an obvious oral mass, excessive salivation, weight loss, halitosis, bloody oral discharge, and dysphasia.

Materials and Methods: The aim this research is study a prevalent of oral cancer in cats in the city of São Paulo, São Paulo. In 1,018 biopsies of oral lesions in dogs, cats, horses and rabbits in Oral pathology Department in the Dentistry School, USP, there are 36 oral cancers in cats. Study 36 oral neoplasms and histopathological classification of all tumors. This cats was been classification about age, breed, sex and location of lesion.

Results: The most common is squamous cell carcinoma 24 cases (66.7%), osteosarcoma 6 cases (16.6%), malignant melanoma 5 cases (13.9%) and fibrosarcoma one case (2.8%). Sex males and females are equal and, the average age is nine years old. Cats without breed defined short hair are more common 32 cases (89%).

Discussion and Conclusion: In conclusion, squamous cell carcinoma is more common oral cancer in cats in São Paulo City like an international literature. Older cats have been more oral cancer than younger. In Brazil the most common breed of cat is without breed defined short hair, therefore has the same frequency in oral tumor.

References: Bertone E.R., Snyder L.A. & Moore A.S. 2003, Risk factors for oral squamous cell carcinoma in cats. J. Vet. Intern. Med. 17:557-562. - Dorn C.R. & Priester W.A. 1976 .Epidemiologic analysis of oral and pharyngeal cancer in dogs, cats, horses and cattle. J. Am. Vet. Med. Assoc. 167(12):1202-1206. - Moore A.S. & Ogilvie G.K. 2001. Tumors of the alimentary tract, p.271-291. In: Ogilvie G.K. & Moore A.S. (ed.), Feline Oncology. 1st ed. Veterinary Learning Systems, Trenton, NJ. - Stebbins K.E., Morse C.C. & Goldschmidt M.H. 1989. Feline oral neoplasia: a ten-year survey. Vet. Pathol. 26(2):121-128. - Snyder L.A., Bertone E.R., Jakowski R.M., Dooner M.S, Jennings-Ritchie J. & Moore A.S. 2004. Expression and environmental tobacco smoke exposure in feline oral squamous cell carcinoma Vet. Pathol. 41:209-214.

INDEX TERMS: Oral cancer , cats, squamous cell carcinoma.

021. Ferreira J., Venturini M.A.F.A., Lopes F.M., Leon-Román M.A., Kowalesky J. & Gioso M.A. 2007. **Neoplasias in young dogs: two cases report.** *Pesquisa Veterinária Brasileira 27(Supl.).*
Laboratory of Comparative Dentistry, Surgery Department, FMVZ-USP, São Paulo, Brazil. E-mail: jonathanvet@usp.br

Introduction: The neoplasias seem to be growing in prevalence in pets and the mouth is one of the places with more occurrence. Diverse types of neoplasias occur in the mouth, malignant or benign, and the most common are: epulides, melanoma, carcinoma, fibrosarcoma, papilloma, and osteosarcoma (Gioso M.A. 2003). The present report mentions two young dogs with oral neoplasia treated in the Laboratory of Comparative Dentistry, School of Veterinary Medicine and Animal Science, University of São Paulo, Brazil.

Case Report 1: An animal of the canine specie (*Canis familiaris*), female, 5 months, golden retriever was examined in the Laboratory of Comparative Dentistry. The owner reported that referring veterinarian examined the dog 10 days before due to having noticed a tooth with mobility in the left mandible. The tooth was extracted and sent to histopatological examination together with periapical tissues and was prescribed clorhexidine 0.12% for oral hygiene and antibiotics with associated spiramicin and metronidazole. After 7 days it was prescribed also prednisolone and ceftriaxone. The owner told that it did not have improvements and she noticed the appearance of a lesion in the distal portion of the left mandible. She also reported that the result of the histopatologic examination was suggestive of neoplasia of round cells. It was noticed in physical examination a mass of approximately 3.0cm of diameter, with ulcers and erithema in the distal region to the mandibular left first molar, as well as presence of two teeth in the interior of the mass and dislocated the lingual aspect. An area of osteolisis in distal region to mandibular left first molar was visualized on the x-ray, and no alteration in pulmonary fields in the radiographic evaluation was noted. One week later the animal was submitted to surgical intervention for the total ressection of the mass with safety margin. Left partial mandibulectomy was carried through. The entire mandible distal to the mandibular left third premolar was removed. The safety margin around the neoplasia was at least 2.0cm and the left palatine tonsil also was excised due to localization in the definitive area as safety margin. The animal was medicated with cloridrate of tramadol 2.0mg/kg every 8 hours per 5 days, spiramicin 75,000 UI/kg + metronidazole 12.5 mg/kg every 24 hours per 10 days, meloxicam 0.1 mg/kg every 24 hours per 4 days and clorhexidine 0.12% every 6 hours per 15 days for oral hygiene. The removed material was sent to histopatological examination. The healing process progressed satisfactorly. The owner reported trauma of the maxillar left canine tooth in the lingual gingiva to the mandibular left canine tooth due to the absence of the distal left mandible. After 15 days of the intervention the animal presented complete healing of the surgical wound, however the histopatologic examination indicated suggestive lymphoma neoplasia with anaplasic gigantic cells and was also noticed mass in mandibular left lymph node of approximately 4.0cm of diameter. The animal was directed to the department of internal medicine where chemotherapy treatment with vincristine and prednisolone

was instituted. The animal answered well to the first session of chemotherapy; however it was diagnosed metastasis in mediastinic lymph node and pleural effusion, with about 2 liters removed of liquid every 2 days. One month after the institution of the chemotherapy, drainings of pleural liquid, important loss of weight, and of gradual apathy of the animal, the owner opted for euthanasia, and no necropsy.

Case Report 2: An animal of the canine species (*Canis familiaris*), male, 79 days of age, Schnauzer breed, was examined in the Laboratory of Comparative Dentistry. In the case history the owner informed that at 20 days old it was noticed a mass in the left mandible. He looked for the opinion of a private veterinarian, who did an incisional biopsy and histopatologic examination. The diagnosis was squamous cells carcinoma. It was prescribed prednisolone 1.0mg/kg every 12 hours per 7 days and there was small regression of the tumor. In the physical examination an ulcerated mass, not pigmented through all the extension of the left mandible was seen. In the radiographic examination it was visualized areas of osteolysis and a ventral mass in the left mandible. Explained the prognostic and the absence of safety margin for surgical resection, in agreement with the indication of the referring veterinarian who made the first consultation the owner opted for euthanasia. The animal was sent for necroscopic examination where it was not identified compatible alterations with metastasis and it confirmed the oral neoplasia as squamous cells carcinoma.

Discussion and Conclusion: The lymphomas (malignant lymphoma or lymphosarcoma) are a diverse group of cancers that originate from a type of white blood cell called a *lymphocyte*. They are one of the most common cancers diagnosed in dogs and cats. This cancer usually arises in lymph tissues such as lymph nodes (lymph glands), spleen, and bone marrow; however, it can arise in almost any tissue in the body including the skin, the brain or spinal cord, bones, heart, or intestines (Verstraete F.J.M, 2005). In the case reported the animal was very young. Squamous cell carcinoma is diagnosed in 20% to 30% of oral tumors in the dog but it is more common in the cat (70% of oral tumors). There is no sex predilection in the dog, but older large-breed dogs are more commonly affected. Squamous cell carcinoma most often originates in the gingiva, especially on the rostral mandible, and infiltrates deeply (Wiggs & Lobprise 1997). In this reported case the neoplasia was in this region and with the same aspect related before but the animal was extremely young. In these cases, the prognosis was poor due to the time of evolution and the local tissue invasion.

References: Gioso M.A. 2003. Odontologia para o Clínico de Pequenos Animais. I Editora, São Paulo. - Verstraete F.J.M. 2005. Mandibulectomy and Maxillectomy. W.B. Saunders, Philadelphia (Cit. by Holmstrom S.E. Vet. Clin.North Am. Small Anim. Pract.,Dentistry, 35:1009-1039). - Wiggs R.B. & Lobprise H.B. 1997. Oral Surgery. Lippincott-Raven, Philadelphia (In: Veterinary Dentistry: principles and practice. Lippincott-Raven, Philadelphia).

INDEX TERMS: Oral neoplasia, young dogs, squamous cells carcinoma, lymphoma.

022. Gallo M. A. & Pavezi K. S. 2007. **Dental radiographic study in horses using extraoral techniques.** *Pesquisa Veterinária Brasileira 27(Supl.).* Private Practicioner, São Paulo, SP 04576-040, Brazil. E-mail: gallo_rx.vet@terra.com.br

Introduction: The radiographic investigation of tooth problems in horses is one of the most applicable techniques of evaluating tooth soundness in the horse practice. The use of portable x-ray machines makes the radiographic evaluation become more comfortable for both owners and patients, mainly for the horses who live far from a vet centre. It is quite affordable for vets to purchase the equipments and for owners to pay for the diagnostic examination. This paper has the aim to demonstrate for veterinary colleagues how to approach horses suffering from possible oral disorders, using the x-rays images as an important and very effective diagnostic tool.

Materials and Methods: The radiographic images in this presentation were produced by portable lightweight x-ray machine, with a focal spot tube, a light beam collimator, a kVp of 70, mA of 20 and variable exposure times among the different techniques discussed here. The broader the patient's skull, the longer the exposure time required for good quality images. The dimensions of the cassettes, screens and films are standard in Brazil and we suggest the size of 24 x 30cm films. The screens are green sensitive and of course must match the film choice. The radiographic incidences we try to demonstrate are the lateral and the oblique views. The lateral view is done for a panoramic purpose. For the evaluation of the teeth, this incidence requires higher mAs - about 8 mAs or more. The oblique views have more applicability for isolating each hemi-arcade and require lower mAs - about 6 mAs. For the lower tooth arcade, the cassette is positioned parallel to the side to be investigated and an oblique ventrodorsal incidence should be chosen, in an angle of approximately 30° and the central beam coming upwards from the other side. For the upper tooth arcade, the cassette is positioned the same way, on the side of interest and an oblique dorsoventral incidence must be chosen, in an angle of approximately 30° and the central beam coming downwards from the opposite side.

Results: The lateral view has important diagnostic value when searching for abnormalities in the inner sinuses, such as the presence of bony fragments in traumatic fractures of the skull, bacterial sinusitis (with or without periapical related pathologies) and the presence of masses or foreign bodies. The oblique views have better diagnostic value when each individual tooth is evaluated from the coronary region down to the root and related bone structures, such as the alveolar region. In the mandible, bone lysis surrounding the alveolar bone (with or without fistulae) is commonly observed, even in young horses. The oblique views are very useful to evaluate integrity of the lamina dura.

Discussion and Conclusions: The extraoral radiographic techniques in the horse practice have limited value, when only the lateral view is done. Pathological findings such as sinusitis, for instance, are easily recognizable, but unless a well positioned oblique view is done to isolate the image of each dental hemi-arcade, we cannot properly assure whether there is dental root

involvement or not. For the visualization of lamina dura surrounding each particular tooth, it is necessary to do a very well positioned oblique view, on a strictly perpendicular orientation of the x-ray tube towards the suspected tooth to permit the proper angulation. To seek for abnormalities involving one or more dental structures, the best way to approach the major anatomical details in equine odontology is to investigate both sides, no matter which side is the supposedly altereded, to permit comparison between left and right hemi-arcades. This reduces misinterpretation of radiographic findings and assures better reports and diagnosis.

References: Baker, G. J. 1999. Diagnosis of dental disorders, p.139-169. In: Easley K.J. & Baker G.J. 1999. Equine Dentistry. W.B. Saunders., London. - Done, S.H. 1989. Cabeça, p.2-50. In: Ashdown R.R. & Done S.H. (ed.), Atlas Colorido de Anatomia Veterinária, o Cavalo. Vol.1. Manole, São Paulo. - Easley K.J. 1996. Equine Dental Development and Anatomy. 1996. Proc. Am. Assoc. Equine Pract. 42:1-10. - Hillmann D.J. 1986. Osteologia equina, p.294-323. In: Getty R., Sisson S. & Grossman J.D. 1986. Anatomia dos Animais Domésticos. Vol.1. Guanabara Koogan, Rio de Janeiro. - Klugh D.O. 2003. Intra-oral radiography of equine premolars and molars. Proc. 49th Congr. Am. Assoc. Equine Pract., IVIS. Disponível em www.ivis.org. Acessado em: 2.12.06, 20:30. - O'Brian R.T. Intra-oral Radiography: experimental study and clinical use in two horses and a llama. Vet. Radiol. Ultrasound 37(6):412-414.

INDEX TERMS: Horses, radiography, extra-oral.

023. Garrido M.G. 2007. **Porcelain fused to metal crowns in dogs.** *Pesquisa Veterinária Brasileira 27(Supl.).* Departamento de cirugía, UNAM, Mexico city. E-mails: docgusgarridodentista@yahoo.com, gusgamen@yahoo.com

Introduction: Preparation and setting of porcelain fused to metal crowns is an alternative treatment for restoration of dental pieces in small species, principally in dogs, Restorative dentistry is based on dental restoration and preparation of teeth for to rehabilitate them, partially or totally. The totally rehabilitation could be with crowns, as well as for fixed prosthesis. Fixed prosthesis is the specialty in which all techniques for preparation of fixed crowns and bridges from diverse material used to partially or totally rehabilitate dental structures lost due to pathological causes (tooth decay, external odontoclastic resorption, enamel hypoplasia, etc.), or traumatic (fractures at different levels of tooth crown), or worn out prosthesis (titanium implants, malocclusion, ectopic teeth, etc.) are studied. When working with any kind of crowns, multidisciplinary support from all odontological areas is required to set a porcelain metal crown. It is necessary to work with a dental laboratory using the ideal techniques and material, since final results depend 50% from laboratory work. Knowledge of dental anatomy, gums and occlusion animal to treat are very important because making a porcelain crown requires the best possible imitation of the tooth shape and its function in occlusion. In dogs and cats it is regularly preferable to prepare supra gingival since they are more hygienic. In the case of anterior teeth (incisive and canines), many owners want aesthetic crowns requiring infra gingival preparations. The technique to prepare porcelain metal crowns has certain basic objectives such as: Removing or eliminating abnormal tissue; preserving as much healthy tissue as possible; rehabilitate the crown portion in case of severely destroyed teeth in order to get an adequate stump and; preparing the most adequate design to keep stability and sealing of the porcelain metal unit. There are 4 main principles to prepare crowns:

I. Preserve dental estructure. Not to wear out more than necessary. In the case of porcelain metal crowns, wearing is 1.2 mm from cervical in aesthetic faces.
II. Retention and estability. Retention avoids movement of the restoration along the longitudinal axis of preparation. Estability avoids dislocation of restoration due to oblique or apical direction forces. The basic unit of retention has two opposite dental surfaces of a maximum of 6° conicity.
III. Structural Strength. Dental shaping is proyected to a metal porcelain width necessary to resist occlusion forces.
IV. Pefect limits: Supra or infra gingival dental wear must be precise. This allows restoration to have a sealing isolating the tooth from the buccal environment. Limits support occlusion forces too.

There are 5 types of margins or cervical terminals for dental preparation:

1. Knife edge. It is difficult to wax and drain, since it may produce excessive edges for restoration and distort it with occlusion forces. A needle diamond (pencil point) bur should be used. This margin is used only for metal crowning.
2. Champfer. A rounded point conic diamond bur is used. to finish metal crowns. It is easy to wax and drain and it does not allow excessive edges on the crown and produces less effort before the occlusion forces.
3. Shoulder. It is used for porcelain crowns. The tooth is prepared with a conic diamond bur with plane tip. It is highly resistant to occlusion forces and minimizes restoration effort.
4. Bevel: Modified shoulder shape with a major 90° corbel. A conic diamond bur with round point is used for preparation. It is resistant to occlusion forces and diminishes restoration effort. It is used for metal porcelain crowns.
5. Shoulder with bevel. It is a 90° shoulder ending with beveling ending between 30° and 45°. The sharp angle gotten with beveling is excellent for metal sealing and it is ideal for metal porcelain crowns. The tooth is prepared with a conic diamond bur with plane tip to preparing the shoulder and then a needle diamond bur is used to preparation with beveling. It is resistant to occlusion forces and minimizes restoration effort.

When a tooth is prepared infra gingival it is necessary to use retraction cord for soft tissues. It may be soaked in epinefrin or aluminum sulfate as a vasoconstrictor so that there is no bleeding when it is withdrawn. The first impression is taken (primary impression) with heavy material of polivynil siloxan with the retraction cord in position.

After withdrawing the primary impression the retraction cord is withdrawn from the gingival sulcus and the heavy material impression of silicon is checked with the polyvinil siloxan fluid taking the tray again into the mouth. The fluid or light material is introduced easily into the gingival sulcus allowing getting the negative of the subgingival edge with great precision. The impression is plastered in stone past "velmix" to get the working model. It is necessary to get the patient occlusion with a study model stone. The impression of the antagonist teeth it's getting with alginate (irreversible hydrocoloid). To get a reliable bite is necessary to get the occlusion impression in the patient's mouth with low fussion wax registering the teeth marks. With this marks on the wax the plaster models are articulated so the dental laboratory personnel makes a crown adapted to the specific occlusion of the patient.

Results: 4 clinical cases are presented with different types of rehabilitation of the tooth crown. In 3 cases dentinary pins were used to form the stump, one was rehabilitated with light cured composite, and the other 2 with a mixture of amalgam with "Duralay" acrylic. In the 4th case, the canine stump was rehabilitated with a metal casting post. All cases got an endodontic treatment since the dental pulp was compromised. All canines were rehabilitated with metal porcelain crowns following the methodology described above.

Discussion and Conclusion: Totally aesthetical restorations with infra gingival finishing in pets cause rejection from some veterinaries devoted to odontology since it requires more appointments and a lot of work. Although these factors are considered in deciding whether to place a metal crown, a metal porcelain crown with supra gingival preparation or a metal porcelain crown with infra gingival preparation, It is important to recognize the owners demand better cuality and aesthetics in the treatment of their pets. In all clinical cases, the owners were completely convinced of the benefit they got with this type of restoration and the patients have evolved adequately without gingival problems or rejection of the crown.

References: Amimoto A. 1995. Dental treatment of small animals: radiographic techniques in dentistry. J. Vet. Med., Japan, 48(7):593-598. - Amimoto A. 1995. Dental treatment of small animals: use of a dental unit for treating teeth. J. Vet. Med., Japan, 48(12):1088-1089. - Archundia A.G. 1997. Educación quirúrgica. Méndez Editores, México. - Bojrab M.J. 1990. Small Animal Oral Medicine and Surgery. Lea and Febiger, USA. - Done S.H., Goody P.C., Evens S.A. & Stickland N.C. 1999. Anatomía Veterinaria (Atlas a color). Editorial Hartcourt Brace, España. - Garrido M.G. 1998. Odontología veterinaria integral: caso clínico. Revta AMMVEPE 9(4):132-137. - Garrido M.G. & Paredes R.J. 2002. Pines dentinarios autoenroscados, un auxiliar en retención (tres casos clínicos). Revta AMMVEPE 13(4):135-141. - Garrido M.G., Paredes R.J. & Peña R.M. 2000. Problemas de endodoncia y rehabilitación en colmillos de carnívoros: cuatro casos clínicos. Revta AMMVEPE 11(4):125-130. - Gorrel C. 1998. Radiographic evaluation. Vet. Clin. North Am. Small Anim. Pract. 28(5):1089-1110. - Guilmore H.W., Lund M.R., Bales D.J. & Vernetti J.P. 1985. Operatoria Dental. 4ª ed. Nueva Editorial Interamericana, México. - Hale F.A. & Anthony J.M. 1996. Treatment of mandibular and dental fractures in a young dog. Can. Vet. J. 37(5):307-309. - Harvey C.E. & Emily P.P. 1993. Small Anim. Dentistry. Mosby, USA. - Holmstrom F.E. 1998. Veterinary Dental Techniques for the Small Animal Practitioner. 2nd ed. Lea and Febiger, USA. - Kertesz P.A 1993. Colour Atlas of Veterinary Dentistry andral Surgery. Wolfe Publ., London, UK. - Lang N.P., Karting T. & Lindhe J. 1999. Proc. 3rd European Workshop on Periodontology. Quintessence Publ. Co., Bosch-Druck, Landshut, Germany. - Malone W.F., Koth D.L. 1994. Tylman's Teoría y práctica en Prostodoncia fija. 8ª ed. Nueva Editorial Interamericana, Venezuela. - Oaku A.B. 1998. Small Animal Surgical Nursing and Dentistry: clinical textbook for veterinary technicians. 4th ed. D.M. McCurnin and W.B. Saunders, Philadelphia, USA. - Seif R.T. 1997. Cariología: prevención, diagnóstico y tratamiento contemporáneo de la caries dental. Actualidades Médico Odontológicas Latinoamérica, C.A. Colombia. - Sturdevant C.M. 1985. The Art and Science of Operative Dentistry. 2nd ed. C.V. Mosby, USA. - Verstraete F.J.M. 1998. Routine full-mouth radiographs as a teaching tool in veterinary dentistry. J. Vet. Med. Educ. 25(2):28-31.

INDEX TERMS: Porcelain fused to metal crowns, restorative dentistry.

024. Garrido M.G. 2007. **Self-threading dentinary pins as retention auxiliary: clinical cases in dogs and turtles**. *Pesquisa Veterinária Brasileira 27(Supl.).* Departamento de Cirugía, UNAM, Mexico city. E-mails: docgusgarridodentista@yahoo.com, gusgamen@yahoo.com

Introduction and Development: Self threading dentinary pins are small screws used in odontology as reconstruction material retainers such as amalgam, composite, "duralay" acrylic with amalgam or glass ionomer cement with amalgam filing. There are three kinds of dentinary pins: cemented pins, holding pins by friction and self threading pins. The technique for cemented pins was first reported by Markley in 1958. Research done by Dits and colaborators in 1968, and Moffa and his group in 1969 showed the self threading pin is the most retentive in dentine as well as in the restoration material. Reconstruction is a method to rehabilitate severily destroyed teeth, forming stumps for prothesic purposes or restoring the shape and function of the affected tooth. Pins are placed in dentine, which is the mineralized tissue found along the teeth under the crowning enamel and the cementum. Dentine is formed due to odontoblastos which are cells found in the perifery of dental pulp and in contact with predentine. Dentine is structurally different from bone tissue, but it is very similar from the physical-chemical point of view. When mineralized it has between 15% to 30% organic matter, mineralization cristals are hydroxiapatita and its elasticity and hardness are very similar to bone. Elasticity allows dentinary pins to be placed in dentine without causing tooth fractures due to occlusion. An important problem to consider is that in young teeth pin placing is more difficult since there is a smaller quantity of dentine. Dentine has millions tubes going from pulp to enamel and cement, inside this tubes there are citoplasmatic prolongations from odontoblastos and nerve terminals tath allow the tooth to form reparing esclerotic dentine as well as sensitivity

respectively. Procedure to place self threat pins requires a one channel drill slightly smaller in diameter to place the pin. Drills have a point to prepare channels for a depth going from 1 to 4 millimeters with a diameter from 0.34 to 0.68 millimeters. The self threading dentinary pins are made of titanium o stainless steel. Their lenght goes from 3 to 8.2 millimeters and a diameter from 0.38 to 0.78 millimeters. The differences between the drill and the pin go from 0.04 to 0.10 millimeters. There are self section pins, others which may be cut with burs being self section pins the most confortable. Dentinary pins work better for vital teeth since teeth with endodoncy traetment loose moisture and organic material and consequently loose elasticity. Choosing the pin´s diameter and the necessary number of pins has to do with the ammount of dentine present in the affected tooth. The pin is placed where there is more dentine, normally in vital teeth in the mesial-buccal, mesial-palatal, distal-palatal and distal-buccal angles, according to tooth destruction. To decide where and what direction the pin must go into the tooth, the morphology of every tooth of the species to treat must be known, otherwise the pulpar tissue or the peridontal ligament with all bone tissue. The canal must be from 1 to 2 mm from the external crowning surface or radicular and with a direction parallel to the longitudinal axis of the root involved, although this may vary occacionally but always trying not to hurt the pulp or the oseo-paradontal tissue. The most common failures may be due to: dentinary or mineralizad tissue sostened by tooth decay or any other factor; drilling more than necessary and making a channel a lot wider than the pin; part of the pin being in pulpar or paradontal tissue. The most common accidents are: breaking the pin inside the channel; leaving part of the pin outside the base, causing the pins exit from the receibing tissue and; penetration within the pulpar chamber or the external surface of the tooth (periodontal or bone tissues). In veterinary medicine, dentinary pins are used as in human odontology, but also may be used in other cases such as reduction and ferulization in turtle shell fractures or big birds beaks, or interdentary casting. Other applications are possible using common sense before need. It is important to mention some general aspects about quelonian anatomy. Turtle shells are made of a shell (dorsal region) and a plate (ventral region) connected with bone bridges. The shell is made of about 50 bones coming out of the ribs, vetrvrae and skin elements. The bone part of the shell is covered with superficial sheets made of queratin. These plates are organized in a way they dont overlap at the bone tissue joints under them. Turtles produce new plates every period of growth and change tha plates from the previous period. There are 4 clinical cases in this work where self threaded dentinary pins were used, automatic section with plastic base for counter angle with slow speed handpiece. Two of the cases are dental reconstruction from a canine and a 4th upper premolar with light cured composite in two dogs.The other two cases are turtles suffering a shell fracture using 0.010 inch in diameter wire as a ferula and pins. The other turtle was rehabilitated with an acrilic plate fixed to the shell with dentinary pins, 0.010 inch wire, thermo maleable silicon and a covering made of acrylic.

Discussion and Conclusion: Self threaded dentinary pins are instruments that provide retention to a great number of elements. Without them, the possibility to reconstruct or ferulize structures which size make it impossible to use screws. With training they are easy to handle and the cost is low for the service they provide. With common sense they can be used for many different treatments and new alternatives. The final decision depends upon the doctor and his/her wish to solve the problems present in their patients. In the clinical case of the acrilic plate place on the turtle's shell, the decision was made principally to observe the healing process in quelonians and to photograph its evolution.

References: Amimoto A. 1995. Dental treatment of small animals: radiographics techniques in dentistry. J. Vet. Med., Japan, 48(7):593-598. - Amimoto A. 1995. Dental treatment of small animals: use of a dental unit for treating teeth. J. Vet. Med., Japan, 48(12):1088-1089. - Bojrab M.J. 1990. Small Animal Oral Medicine and Surgery. Lea and Febiger, USA. - Done S.H., Goody P.C., Evens S.A. & Stickland N.C. 1999. Anatomía Veterinaria (Atlas a color). Editorial Hartcourt Brace, España. - Fowler M.E. 1986. Zoo and Wild Animal Medicine. 2ª ed. W.B. Saunders, Philadelphia. - Garrido M.G. 1998. Odontología veterinaria integral\; caso clínico. Revta AMMVEPE 9(4):132-137. - Garrido M.G., Paredes R.J. & Peña R.M. 2000. Problemas de endodoncia y rehabilitación en colmillos de carnívoros: cuatro casos clínicos. Revta AMMVEPE 11(4):125-130. - Gorrel C. 1998. Radiographic evaluation. Vet. Clin. North Am. Small Anim. Pract. 28(5):1089-1110. - Guilmore H.W., Lund M.R., Bales D.J. & Vernetti J.P. 1985. Operatoria Dental. 4ª ed. Nueva Editorial Interamericana, México. - Harvey C.E. & Emily P.P. 1993. Small Animal Dentistry. Mosby, USA. - Holmstrom F.E. 1998. Veterinary Dental Techniques for the Small Animal Practitioner. 2nd ed. Lea and Febiger, USA. - Kertesz P. 1993. A Colour Atlas of Veterinary Dentistry and Oral Surgery. Wolfe Publ., London, UK. - Marreta S.M. 1998. Maxillofacial surgery. Vet. Clin. North Am. Small Anim. Pract. 28(5):1285-1296. - Oaku A.B. Small Animal Surgical Nursing and Dentistry: clinical textbook for veterinary technicians. 4th ed. McCurnin D.M. and Saunders W.B., Philadelphia, USA. - Sturdevant C.M. 1985. The Art and Science of Operative Dentistry. 2nd ed. C.V. Mosby Company, USA. - Verstraete F.J.M. 1998. Routine full-mouth radiographs as a teaching tool in veterinary dentistry. J. Vet. Med. Educ. 25(2):28-31.

INDEX TERMS: Self threading dentinary pins, teeth reconstruction, turtle shell repair.

025. Garrido M.G. 2007. **Sinusotomy in *Amazona autumnalis* parrot with infraorbitary bilateral approach: clinical case.** *Pesquisa Veterinária Brasileira 27(Supl.).* Departamento de Cirugía, UNAM, Mexico city. E-mail: docgusgarridodentista@yahoo.com

Introduction: Amazon parrots are widly accepted due to their colors and ability to emit sounds immitaing human language. The majority of respiratory diseases in birds develop rapidly allowing early identification by the owner and therefore a rapid diagnosis as well as effective treatment by the veterinarian, even so, chronic inflammation of the nose, sinus and air sacs may go on for many years without showing clinical signs. Respiratory diseases may complicate due to many opportunistic infections that take advantage of the respiratory ephitelium damage. Diagnostic and treatment depend upon knowledge of the anatomy and physiology of the bird respiratory system. The process that will take the

bird to good health implies frequent exposure to fresh air and sun light, adequate nutrition and rutinary flying exercises. The factors predisposing to respiratory tract diseases include: 1) Nutrition problems, being vitamin A deficiency the most common; it may cause metaplasia of the squamous respiratory epithelium; mechanical obstruction caused by the precense of foreign bodies such as seeds, peelings, dust and feathers; 2) Parasite local problems principally caused by *Cnemidocoptes pilae* causing obstruction of air flow; 3) Environmental factors as tabacco smoke, low moisture because of air conditioners, boilers, irritation of nasal tissues due to perfumes and sprays; 4) Problems caused by infection agents suchs as bacteria, fungus, *Chlamydia* spp., *Mycoplasma* spp., and virus; 5) Local traumatism; and 6) Respiratory epithelium neoplasms of the superior respiratory tract, being the most common fibromas, fibrosarcomas and squamous cell carcinomas. During the examination, the patient must be observed from a distance in order to see if there are changes in normal posture, wing position, respiratory frequency, and respiratory pattern that may indicate abnormalities. A bird uses chest muscles for the respiratory cycle. Any compromise in the input or output effort may affect the bird´s posture. Normal respiratory effort must be observed and the beak must be closed. Respiratory diseases may be present in two levels, the upper respiratory tract (nostril, operculum, nasal shell, infraorbitary sinus, glottis and trachea) and the lower respiratory tract (sirynge, bronchus, lungs, and air sacs). The infraorbitary sinuses are divided into right and left, in some birds they are connected as in the psittacides and are separated in other species. The infraorbitary sinus is the only paranasal sinus in birds and is located sideways to the nasal cavity and surrenders ventrally to the eyes. It has several compartments (rostral, preorbitary, infraorbitary, postorbitary, preauditory and mandibular) and two chambers (maxilar and suborbital). The left and right infraorbital sinus are connected in their rostral portion with the nasal shell through an opening coming out of the preorbital compartment, and in its caudal portion with the cranial portion of the cervical-face air sacs communicating to the suborbitary compartment. It is important to understand that the disease process in the upper respiratory tract could invade internal zones, and may spread into the muscles of the patient's face and neck. The interconnection of the nasal cavity, the infraorbitary sinus and the head, causes a situation in which inflammatory reactions in the sinuses or in the nasal cavities may involve the majority of the head structures. At the same time, the infection may spread to the cervical face air sacs. In severe chronic sinusitis the piling of abscess tissue may cause destruction of the nostril, nasal cavity, operculum and concha nasal. This degree of destruction is very common in amazon and grey African parrots with sinusitis due to apergilosis. The clinical conditions that the professional must consider to diagnose upper respiratory tract illnesses depend upon the presence of clinical signs as open mouth breathing, voice changes, sneeze, face tumors in the sinus zone, nasal granulomas, intolerance to exercise, breathe difficulty, shaking head movements, mucous purulent nasal discharge, neck swelling, blepharospasm, epiphora, periophtalmic swelling, obliterated nostril, anatomic distortion of the nostril, and face deformities. Diagnose protocols may be: Checking the nutricional state through a clinical history (exposure to cigarette smoke, etc.), Gram tint in feces, flotation test in feces to determine parasites, affected areas cytology, Xrays, tomography, magnetic resonance, ultrasound, rhinoscopy, cultures and sensitivity tests to antibiotics, biopsy and histopathology.

Case Report: "Gastón", a 10-year-old male *Amazona autumnalis* parrot was taken for checking to the Hospital of Small Species of the Veterinary Medicine School, National University in Mexico city. Upon physical examination the animal had a 41.9ºC temperature, cardiac frequency of 140 bits/min, respiratory frequency of 30 respirations/min, body condition 2/5, weight 450g, slight diminishing in left nostril, mucous secretion in both nostrils, increasing volume in the right side of the face at the jaw angle and infraorbital, increased volume of the left side of the face at infraorbital level, blepharospasm and bilateral epiphora. The patient was sent home administered with enrofloxacin at 5mg/Kg every 12 hours. It was appointed for surgery and entered the preparation area of the hospital where anesthesia was induced with isoflurane at 3% plus 100ml/min of oxygen, later a pediatric endotraqueal (catheter of Cole) was placed, fixed to the lower beak with tape. The catheter was connected to a tube for Bain opened system. An esophagic catheter was placed to monitor constantly the changes in cardiac and respiratory frequences. Two 1cm preorbital incisions were done caudally towards the rostro. The sinus were treated extracting solid abscess material from all compartments and chambers and on the right side a fistula among a muscle aponeurosis, which had invaded all the way to the lower angle of the jaw. The extracted material was sent to the lab for bacteria testing. Tissue samples from the infraorbitary sinus were taken for histopathological diagnosis. The wound was sutured with simple separate points of nylon 5-0. It was pressure washed with a physiologic salty solution at 0.9%. The patient was sent home with Enrofloxacin at 5mg/kg administered orally every 12 hours for 7 days, with a multivitamin given orally every 24 hours, and with instructions to keep the wounds clean. The lab results showed a *Pseudomonas aeruginosa* in high quantities, susceptible to gentamycin, polymixin B and norfloxacin. The pathomorphologic diagnosis was heterophylic sinusitis and multifocal moderate linfoplasmocytic with spread necrosis compatible with an abscess. During the checking appointment the suture was removed, the nostrils were positive pressure washed with salty solution at 0.9% using a syringe, and the Gaston´s head was leaning so that the water running out the coanas was not aspirated. Medication was changed to norfloxacin at 10mg/kg administered orally every 12 hours.

Disscusion and Conclusion: Sinusitis diagnosis in pet birds requires clinical experience. Causes originate this type of pathology are many and generally interrelated. Anesthetic handling of pet birds must be carefully done and it is necessary to have knowledge and experience. Sinusotomy is an effective chirurgic technique as long as there is adequate postoperatory handling.

References: Bauck G. 1993. A Practitioners´s Guide to Avian Medicine. The American Animal Hospital Association, Pullman, Washington, USA. - Bennet R.A. & Phalen D.N. 2000. Exotic animal practice. Vet. Clin. North Am. 3(2). - Bennet R.A. & Phalen D.N. 2000. Exotic animal practice. Vet. Clin. North Am. 3(2). - Bransom W.R., Harrison G.J. & Harrison L.R. 1994. Avian Medicine Principles and Application. Wingers Publ., USA. - Burr E.W. 1987. Companion Bird Medicine. Iowa State University Press,

Ames. - Campbell T.W. 1995. Avian Hematology and Cytology. 2nd ed. Blackwell Publishing Company, USA. - Coles B.H. 1997. Avian Medicine and Surgery. 2nd ed. Blackwell Science, UK. - Cooper J.E. 1998. Birds of Prey Health and Disease. Blackwell Publ., USA. - Getty R. 1992. Anatomía de los Animales Domésticos. 5ª ed. Salvat, Mexico. - Heidenreich M. 1997. Birds of Prey, Medicine and Management. Blackwell Publ., USA. - Redig P.T., Cooper J.E. & Rangle J.D. 1993. Raptor Biomedicine. University of Minnesota Press, Minneapolis. - Ridell C. 1987. Avian Histopathology. The American Association of Avian Pathologists. - Rosskopf W. & Woerpel R. l996. Diseases of Cage and Aviary Birds. 3rd ed. Lea and Febiger, Philadelphia. - Samour J. 2000. Avian Medicine. Mosby, St Louis. - Tully T.N., Lawton M.P.C. & Dorressein G.M. 2000. Avian Medicine. Butterworth Heinemann Publ., London, UK.

INDEX TERMS: Sinusotomy in parrots.

026. Gawor J. 2007. **Oral Melanoma malignum in dogs and cats: postoperative protocol with the use of interferon and cytotoxic drugs.** *Pesquisa Veterinária Brasileira 27(Supl.).* Klinika Weterynaryjna Arka, ul. Ch³opska 2a 30-806 Kraków, Poland. E-mail: jgawor@pp.com.pl

Introduction: Oral Melanoma is the most frequently diagnosed malignant tumor in oral cavity in dogs and the second most frequent one in cats (Gawor 2002, Madewell 1973, Harvey & Emily 1993, Withrow & MacEwen 1996, Priester & McKay 1999, Gawor 2002). Management of this condition may be very frustrating because of its specific biology that causes failure of many surgical procedures. It is relatively common that the oral MM is diagnosed at the stage of growth that allows only for palliative surgery. There are numerous studies that evaluate different supporting treatment which follows the oral surgery (Harvey et al. 1981, Bateman et al. 1994, Gillette 1995, Blackwood & Dobson 1996, Theon et al. 1997, Luna et al. 2000, Kieza 2001, Ohashi et al. 2001, Rassnick et al. 2001, Lewicki 2002). Many papers and experiences show possible efficiency of immune-related drugs and the procedures that involve immune system of the patient (Bostock 1979, MacEwen et al. 1986, Theon et al. 1997, Carson 1998, Soergel et al. 1999).

Materials and Methods: Eight 9 to 13-year-old dogs weighing 6 to 38 kg with diagnosed oral melanoma (Stage of growth II and III) were treated in the similar way. Surgery put a greater stress on simply removing the mass than on radical resection. Therefore, the sections had marginal or wide character. In the first place, because the stage allowed for that, and secondly, because the owner did not accept aggressive procedures. Recovery lasted for 10 days and was followed by the postoperative supportive protocol. This protocol consisted of cytotoxic therapy and administration of interferon á. In the case of dogs, the cytotoxic drug was Dacarbazin which was given intravenously at the dose 200mg/m2 at 3 weeks intervals. In the case of cats, Cyclophosphamid was given orally at the dose 50mg once per week. Additionally, dogs and cats received p.o. saline containing interferon á in a dose of 10 IU/kg for 7 consecutive days with 10 days break between the cycles. Each animal had preoperative blood profile, radiographic evaluation of the chest and x-ray of affected area made. Before each cytotoxic cycle, haematologic tests were done followed with sedation X-ray and clinical examination of affected area.

Results: All of the treated dogs had dark skin and/or hair. There were mixbreds, pekingese, a scottish terrier, a shi-tzu, a poodle and a briard. Their average age was 10.4 years. Two cats were black domestic shorthaired 6 and 11 years old. Location of tumors was different. In the group of dogs: 4 were in mandible, 3 on maxillae, and one dog had 2 different tumors both diagnosed as melanoma. One cat had mandibular mass, another one - palatal. Among 10 tumors, 7 were melanotic melanomas, 2 amelanotic, and one was a desmoplastic type of melanoma. After surgery, all animals received 10 days of recovery period. All individuals presented postoperatively good blood test results that allowed them to undergo the cytotoxic protocol. After first intravenous administration of Dacarbazin, 6 dogs had temporary (24 hrs) problems with appetite and significant drop of activity. In the case of 2 dogs, no side effects were observed. Orally administered interferon did not cause any inconveniences. The cats also accepted the drugs very well. All dogs were under control for maximum 18 months and in all cases a monthly control was done. In each case, postoperatively and after cytotoxic treatment, complete remission was observed. The recurrence of tumor took place in 6 dogs and was observed after 3-10 months after surgery. All of them were euthanized when the obvious discomfort of life occurred. Two dogs died because of other than neoplastic reasons without signs of MM after 10 and 11 months after surgery. Survival time in those dogs which had recurrence was 4-18 months. Average survival time in this group was 11.1 months. One cat survived 12 months after surgery, however the tumor reappeared 3 months after its removal in the same place (mandible) The other cat was euthanized 2 months after surgery because of local rapid recurrence of palatal mass which disturbed the cat eating and drinking.

Discussion and Conclusions: Numerous studies showed the results of treatment oral MM tumors as unsatisfactory. The reported survival time in dogs was in the range of 9-19 months. (Kosovsky et al. 1991, Withrow & MacEwen 1996, Horsting 1998, Gawor 2002). In humans, the average survival time in oral MM is 1.8 years. 10% of patients live more than 5 years, and the longest survival time was 19 years. (Shklar 1984, Hoyt et al.1989, Conley 1991, Orr et al.1993). Insufficient resection is considered the most common reason of failure of the treatment of MM. In this particular tumor, the section margins are very often "dirty" with presence of neoplastic cells, moreover the risk of metastasis in melanoma is very high. (Patton et al. 1994) It is the reason of continuous studies on improving MM treatment. When commenting the mentioned average survival time in dogs, one has to note that different stages and methods of treatment were evaluated. Perhaps an important difference is that all dogs and cats in the presented studies had no radical surgery but only palliative one. In supportive protocol, the choice of dacarbazin was based on relatively low level of side effects and requirements for administration and use. (Lewicki 2002) MM is recognized

as the problem where the immune system may play a serious role in the treatment. (Holzle 1993) The use of *Corynebacterium parvum*, interferon alpha, and other immunostimulants were reported and significant improvement in evaluating parameters was observed (MacEwen 1986, Carson 1998, Soergel et al. 1999). It was the reason for adding interferon alpha in low doses which is found beneficial to patients in infectious, neoplastic and some immune mediated conditions. The goal of the presented studies was to evaluate another modification of postoperative protocol in the cases where the margins of section did not remain clear. The measurement of achieved results was mainly the survival time which ended with the obvious lack of life comfort. The author's previous postoperative protocol in such cases consisted of melphalan 2mg/m2 daily with a 10 days intervals every week, given together with prednisone 1mg/kg daily and the average survival time in the group of 25 dogs was 8,23 months (range 2-14). The new protocol with different cytotoxic substance and interferon provided longer medium survival time of 11.1 months (4-18). Based on the obtained results, the used protocol seems to be promising, as we take into consideration the prolonged survival time. Regarding cats, there were too few cases to make an honest judgment on the benefits of this treatment. Still, the number of treated patients is not sufficient to claim spectacular improvement. Further studies are required to evaluate whether this protocol may be an option for palliative treatment of oral MM in small animals.

References: Bateman K.E., Catton P.A., Pennock P.W. & Kruth S.A. 1994. 0-7-21 radiation therapy for the treatment of canine oral melanoma. J. Vet. Intern. Med. 8:267-272. - Blackwood L. & Dobson J.M.1996. Radiotherapy of oral malignant melanomas in dogs. J. Am. Vet. Med. Assoc. 1(209):98-102. - Bostock D.E. 1979. Prognosis after surgical excision of canine melanomas. Vet. Pathol. 16:32-40. - Bradley R..L., MacEwen E.G. & Loar A.S. 1984. Mandibular resection for removal of oral tumors in 30 dogs and 6 cats. J. Am. Vet. Med. Assoc. 184:460. - Carson W.E. 1998. Interferon-alpha-induced activation of signal transducer and activator of transcription proteins in malignant melanoma. Clin. Cancer Res. 4(9):2219-2228. - Conley J. 1991. Is melanoma changing? Otolaryngol. Head Neck. Surg. 104:327-32, 1991. - Gawor J. 2002. Melanoma malignum in oral cavity: review of the literature and analysis of 26 cases. Magazyn Wet.11(67):5-13 (Polish). - Gillette S.M. & Gillette E.L. 1995. Radiation therapy for head and neck cancers. Semin. Vet. Med. Surg. (Small Anim.) 10:168-172. - Harvey C.E. & Emily P.P. 1993. Malignant Melanoma in Dogs and Cats in Small Animal Dentistry. Mosby, p.304-305. - Harvey H.J., MacEwen E.G., Braun D. et al. 1981. Prognostic criteria for dogs with oral melanomas. J. Am. Vet. Med. Assoc. 178:580. - Holzle E., Kind P., Plewig G. & Burgdorf W. 1993. Malignant Melanoma Diagnosis and Differential Diagnosis. Schattauer Verlag, Stuttgart, p.5-11. - Horsting N., Reisewitz A.von, Wohlsein P., Bullerdiek J., Reimann N. & Nolte I. 1998. Oropharyngeal tumors of dogs: a clinical study of 79 cases. Berl. Münch. Tierärztl. Wochenschr. 111:242-247. - Hoyt D.J., Jordan T., Fisher S.R. 1989. Mucosal melanoma of the head and neck. Arch. Otolaryngol. Head Neck Surg. 115:1096-1099. - Kieza Z. 2001. Czerniak z³oœliwy jamy ustnej z przerzutami u psa (próba leczenia cysplatyn¹ i cymetydyn¹). M.W. 10(56):8-10. - Kosovsky J.K., Matthiesen D.T., Marretta S.M. & Patnaik A.K. 1991. Results of partial mandibulectomy for the treatment of oral tumors in 142 dogs. Vet. Surg. 20:397-401. - Lewicki J. 2002. Czerniak - nowe moźliwoœci postêpowania chemioterapeutycznego. Mag. Wet. 11(67):15-17. 2002 - Luna L.D., Higginbotham M.L., Henry C.J., Turnquist S.E., Moore A.S. & Graham J.C. 2000. Feline non-ocular melanoma: a retrospective study of 23 cases (1991-1999). J. Feline Med. & Surg. 2(4):173-181. - MacEwen E.G., Patnaik A.K., Harvey H.J., Hayes A.A. & Matus R. 1986. Canine oral melanoma: comparison of surgery versus surgery plus *Corynebacterium parvum*. Cancer Invest. 4:397-402. - Madewell B.R. 1973. Cancer of the head and neck. Proc. 40th Am. Anim. Hosp. Assoc., p.268. - Nathanson L. 1986. Management of Advanced Melanoma. Churchill Livingstone, New York. - Ohashi E., Hong S.H.,Takahashi T., Nakagawa T., Mochizuki M. & Sasak N. 2001. Effect of retinoids on growth of two canine melanoma cell lines. J. Vet. Med. Sci. 63:83-86. - Orr D.J., Hughes L.E. & Horgan K. 1993. Management of malignant melanoma of the head and neck Brit. J. Surg. 80:998-1000. - Patton L.L., Brahim J.S. & Baker A.R. 1994. Metastatic malignant melanoma of the oral cavity: a retrospective study. Oral Surg. Oral Med. Oral Pathol. 78:51-56. - Priester W.A. & McKay F.A. 1979. The Occurrence of Tumours in Domestic Animals. National Cancer Institute Monograph 54, Departament of Health and Human Services, Bethesda. - Rassnick K.M., Ruslander D.M., Cotter S.M., Al.-Sarraf R., Bruyette D.S., Meleo K.A. & Moore A.S. 2001. Use of carboplatine for treatment of dogs with malignant melanoma cases (1989-2000). J. Am. Vet. Med. Assoc. 1(218):1444-1448. - Shklar G. 1984. Unusual Malignant Oral Neoplasms in Oral Cancer. W.B. Saunders, Philadelphia, p.276. - Soergel S.A., MacEwen E.G., Vail D.M., Potter D.M. & Sondel P.M. 1999. The immunotherapeutic potential of activated alveolar macrophages and antitumor monoclonal antibodies in metastatic canine melanoma. J. Immunother. 22:443-453. - Theon A.P., Rodriguez C. & Madewell B.R. 1997. Analysis of prognostic factors and patterns of failure in dogs with malignant oral tumors treated with megavoltage irradiation. J. Am. Vet. Med. 15(210):778-84. - Withrow S.J., MacEwen E.G. 1996. Small Animal Oncology. W.B. Saunders, Philadelphia, p.240.

INDEX TERMS: Dogs and cats, oral melanoma, interferon alpha, dacarbazin.

027. Gawor J.[1] & Postawa T.[2] 2007. Evaluation of periodontal and dental lesions found in dentition of *Myotis bechsteinii* living 3900 yrs BP (rcybp). *Pesquisa Veterinária Brasileira 27(Supl.).*

Weterynaryjna Arka, ul. Ch³opska 2a 30-806 Kraków, Poland. E-mail: jgawor@pp.com.pl

[1]Jerzy Gawor, Klinika Weterynaryjna Arka, ul. Ch³opska 2a 30-806 Kraków, Poland. E-mail: jgawor@pp.com.pl

[2]Tomasz Postawa, Institute of Systematic and Evolution of Animals, Polish Academy of Science, ul. S³awkowska 17, 31-016 Kraków, Poland.

Introduction: Several thousands years ago, *Myotis bechsteinii* was a dominant bat species in Central Europe (Phillips et al. 1977). Certain amount of mandibles of this animal found in the area of Krakow have had specific lesions in dentition looking similar to FORL. There is no former report about similar pathologic changes in this species. Was the dental disease the reason of significant reduction of this population? The preliminary analysis of clinical, radiologic, and histologic evaluation is presented in this brief.

Materials and Methods: Among 92 mandibles of *Myotis bechsteinii* found in Jaskinia Malotowa (the cave in southern Part of Poland near Krakow), a part had visible damages of hard tissues. The age of the mandibles was evaluated with the use radiocarbon dating (AMS ^{14}C). The mandibles were numbered and photographed. Each mandible was clinically evaluated with 7,5x magnification. All of them were X-rayed too. Two groups of defects were distinguished: dental and mandibular. One of the most representative mandible for each group had been evaluated with the use of a scanning microscope. Two others were demineralized, sliced, stained and evaluated histologically.

Results: All mandibles belonged to one species: *Myotis bechsteinii.* The estimated age was evaluated with the use of of ^{14}C and estimated as 3905 yrs ±35. 37 of 92 mandibles (40%) had visible lesions in dentition and/or in mandibular bone. Based on a preliminary evaluation, the external cause seemed to be very unlikely. 18 were left, and 19 right mandibles. In clinical evaluation of 37 selected mandibles with 7,5x magnification, all the lesions that were found were described (Table 1). Location of defects was précised as it exists in anatomy of mandible (Fig. 1). The defects were divided into 2 groups: dental and mandibular. First group referred to the dental crown and its neck area, the second group contained those which had the lesions in different parts of mandibular bone. All 37 selected mandibles had mandibular lesions (Group 1), and 8 of them had dental defects (Group 2). In Group 1 there were affected: one fourth premolar tooth, five first molars, five second molars and three third molar teeth. Dental lesions had sharp edges, hard bottom and an appearance similar to resorptive lesions. Radiographs made with different techniques did not allow for detailed evaluation of dentition. Scanning microscope visualization confirmed the cavital shape of the lesions and the sharp edges of defects. In some places, openings of dentinal tubules were seen. Histology made possible evaluation of the entire tooth including its roots. Microscopic evaluation showed the more intensive stain of hematoxylin in the affected areas. In root, the lesions looked as root replacement with variable density of hard substance, irregular shape and empty spaces were found. All of the lesions were considered as intravital ones. In Group 2, localization of defects is presented in Table 2. In macroscopic examination the lesions had focal character and had different stages of bone damage: from the discolorations of the bone through erosion into complete lack of cortical bone and perforation into mandibular canal and/or into alveolus. Most of bone lesions were located at processus alveolaris of the mandible. Radiographically, no further details could be obtained as the resolution of picture was not satisfying. In scanning microscopy, the lesions had certain margins, did not look as infiltrative. Microscopic evaluation of histological slide showed the areas of affected bones with numerous empty spaces which were intrabony and had regular round and oval shape. Trabecular character of bony structure was partially lost in those areas. More intensive hematoxylin stain was observed in most external parts of the affected bone.

Discussion and Conclusion: Preliminary analysis of the obtained results allows for the fundamental conclusion: the defects presented in mandibles were intravital and not caused by external conditions as climate, humidity, acidity of environment etc. Among evaluating methods, the most reliable results were obtained in microscopic evaluation of histological slides. Obviously, in non-fixed material all vital cellular soft structures disappeared. However the remaining empty spaces looked exactly like vascularisation, root replacement and cavities. The localization of those empty spaces was not casual. All of them were located next to erosions and/or dental defects. The more intensive stain of hematoxylin used to be the consequence of less mineralized, softer substance in material. This area was present only in

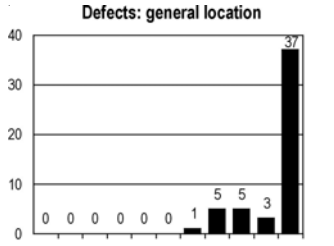

Table 1

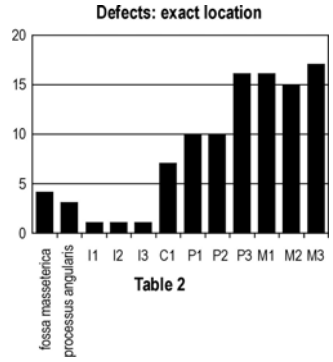

Table 2

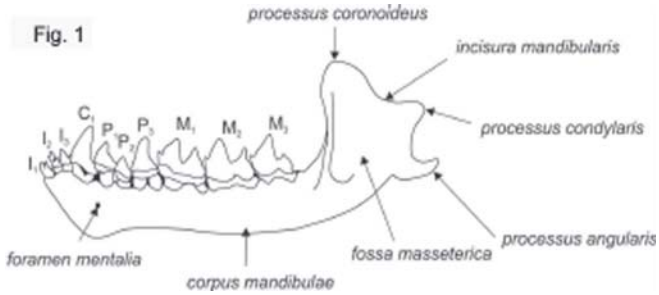

defects, not circumferential in the entire tooth surface. Such an appearance of the described above lesions is typical for inflammatory or resorptive process often observed in periodontal disease, dental resorptive lesions or caries in mammals. In radiographic evaluation, an important limitation was the resolution of image. Small size of the mandibles (10mm length) and even smaller dentition made the classic and digital methods of radiographic imaging useless. In fact, this part of examination did not give an important input to the results. Still, the method of an accurate radiographic evaluation of that small object is being tested as radiolucency of the affected places is one of missing aspects of examination.

The location of defects excluded possibility of attrition and abrasion as their possible origin. Dentition of bats was the subject of interest and studies. Alveolar resorption was described in different species of bats living in Europe and North America (Phillips & Jones 1970). In studies made on the sculls of currently existing European species of bats, 1/5 of the examined sculls had signs of periodontitis (Vierhaus 1980). In all studies, the endogenic reason was seriously considered (Phillips 1970, Vierhaus 1980). There are no reports about oral problems in bats from that old times. The presented material gives the preliminary ideas about possible clinical problems in the nature that occurred in the past and had a serious influence on the existing species:

1. The real clinical character of periodontal and dental lesions found in mandibles of *M. bechsteinii* living over 3900 ^{14}C yrs BP is very likely.
2. Possible inflammatory character of lesions typical for periodontal disease, caries and dental resorption is considered.
3. Prevalence of oral problems might affect the size of population of *Myotis bechsteinii* and cause its reduction.

References: Phillips C.J., Grimes G.W., Forman G.L. 1977. Oral

biology, p.121-177. In: R.J. Baker R.J., Jones Jr J.K. & Carter D.C. (ed.), Biology of Bats of the New World, Family Phyllostomatidae, Part II. Spec. Publ. Mus.Texas Tech. Univ. 13. - Phillips C.J. & Jones K. 1970. Dental abnormalities in North American bats. II. Possible endogenous factors in dental caries in *Phyllostomus hastatus*. Kansas Sci. Bull. 48:791-99. - Vierhaus H. 1980-1981. The occurrence of parodontal disease in central European bats. Proc. 1st European Symposium on Bats Research, Myotis, p.18-19.

INDEX TERMS: *Myotis bechsteinii*, periodontal disease, caries, dental resorption.

028. Hall B.P. 2007. **Endodontic and prosthodontic repair of maxillary cuspids in a working dog.** *Pesquisa Veterinária Brasileira 27(Supl.).* The Animal Dental Clinic, Vienna, VA. United States. E-mail: K92thBarron@aol.com

Introduction: Signalment: 2-year-old, male, German shepherd dog. The patient is an actively working police dog. The handler/owner noticed him "backing off the sleeve" during his training sessions. The RDVM saw the patient and referred him for assessment of a fractured canine tooth with possible endodontic and prosthodontic therapy to preserve his career. Upon presentation the oral exam revealed bilateral Class VI, Stage IV mesiodistal fractures of the maxillary canine teeth (104, 204). There was a vertical fracture of the distal third of 104 that extended subgingivally.

Case Report: Once anesthetized a complete oral exam was done: attrition was noted along with the maxillary canine tooth fractures. Infraorbital nerve blocks were done bilaterally using Marcaine with epinephrine. Intraoral radiographs revealed the vertical fracture of 104 did not extend into the root canal. Using a 12-fluted bur on a water cooled high-speed handpiece, a Type II crown lengthening procedure was done for 104 and a Type I crown lengthening was done for 204. Standard root canal therapy was performed on both teeth using CRCS and gutta percha for obturation. A plastic post, extending into the root canal, was placed so that it extended about 3-4mm from the open pulp chamber. An area specific impression tray was filled with vinyl polysoloxine and placed over the prepared tooth to make the area specific impressions. Full mouth impressions were taken using normal setting alginate, and then the open pulp chambers were temporarily closed with Cavit-G. Boxing wax was used for the bite registration. The patient recovered uneventfully. Die keen green, a Type IV stone, was used to make both the area specific and full mouth models. The models were taken to the lab and the Titanium base metal crowns with posts were created.

Discussion and Conclusion: Three days later the crowns were cemented on using Panavia. There was to be no bite work for 72 hours, then he could resume normal activity. The patient presented for an oral exam 8 months post-opt. The crowns were holding up well and the patient was actively working again "like nothing had happened." The kids on his beat call him "bling-bling".

References: Wiggs R.B. & Lobprise H.B. 1997. Veterinary Dentistry: principles and practice. Lippincott-Raven, Philadelphia, PA, p.687. - McKelvey D., Hollingshead K.W. Veterinary Anesthesia and Analgesia. 3rd ed. Mosby, St Louis, MO, p.15, 66-104. - Plumb D.C. 2005. Veterinary Drug Handbook. 5th ed. Blackwell Publishing, Ames, IA. - Walton R.E. & Chiappinelli J. 1993. Prophylactic penicillin: effect on post-treatment symptoms following root canal treatment of asymptomatic periapical pathosis, J. Endod. 19:466. - Muir W.W., Hubbell J.A.E., Skarda R.T. & Bednarski R.M. 2000. Veterinary Anesthesia. 3rd ed. Mosby, St Louis, MO, p.20-22, 100-101. - DiBartola S.P. 1992. Fluid Therapy in Small Animal Practice. W.B. Saunders, Philadelphia, PA, p.502. - Hartsfield S.M. 1991. Advantages and guidelines for using ketamine for induction of anesthesia, In: Haskins & Klide (ed.). Vet. Clin. North Am. Small Anim. Pract. 22(2)266-267. - Lumb W.V. & Jones E.W. 1997. Veterinary Anesthesia. 2nd ed. Lea and Febiger, Philadelphia, PA. - Wiggs R.B. & Lobprise H.B. 1997. Veterinary Dentistry: principles and practice. Lippincott-Raven, Philadelphia, PA, p.685-686. - Beckman B.W. & Legendre L. 2002. Regional nerve blocks for oral surgery in companion animals. Comp. Cont. Educ. Pract. Vet. 24(6):439-444. – Mulligan T.W., Aller M.S. & Williams C.A. 1998. Atlas of Canine and Feline Dental Radiography. Veterinary Learning Systems, Trenton, NJ, p.124-152. - Wiggs R.B. & Lobprise H.B. 1997. Veterinary Dentistry: principles and practice. Lippincott-Raven, Philadelphia, PA, p.46.

INDEX TERMS: Endodontic, prosthodontic, maxillary, cuspids.

029. Hall B.P. 2007. **Labial advancement flap after excisional biopsy of a labial mast cell tumor (MCT).** *Pesquisa Veterinária Brasileira 27(Supl.).* The Animal Dental Clinic, Vienna, VA. United States. E-mail: K92thBarron@aol.com

Introduction: Signalment: 9-year-old, FN, Husky. Patient presented for surgical consultation after 2.5 months of chemotherapy to treat a Grade 3 (poorly differentiated) mast cell tumor (MCT) located on the buccal mucosa of the rostral right lip. Preoperatively, two types of skin flaps were considered to close the defect left after the mass was excised: Y-plasty and advancement flap. Due to the more rostral location, the advancement flap was selected.

Case Report: Once anesthetized a complete oral exam was done: Class III malocclusion, level bite with secondary attrition, and a Class VI, Stage II fracture of the maxillary left intermediate incisor (202). The margins of the mass were delineated. An alveolar infusion block using Marcaine with epinephrine was placed in the oral mucosa around 202, the region around the mass, and along the projected incision line for the advancement flap. An infraorbital block was done using the same local anesthesia. After clipping and surgically scrubbing the right side of the face and extracting 202, a 2cm area around the mass was delineated. A full thickness skin incision was made along these margins to remove the neoplasm, leaving a rectangular defect. The dorsal extent of the excision was horizontally extended caudally about 3cm ventral to the right lateral canthus. The infraorbital neurovascular group was ligated. A small wedge-shaped segment was excised from the rostrodorsal border of the flap to allow for the slight curve along the lip margin. The flap was advanced and closed intraorally and cutaneously without tension. The patient recovered uneventfully.

Discussion and Conclusion: Mast cell tumors (MCT) are

one of the most common skin tumors in the dog comprising 20-25% of the cutaneous and subcutaneous tumors and 11-27% of all malignant tumors. While there is no sex predilection, MCT's are normally found in middle to older aged (mean age ~8.5 years) brachycephalic breeds. They are located 50% over the trunk and perineum, 40% on the extremities, and 10% on head and neck regions. They are classified by Patnaik into three categories: well differentiated (Grade 1), moderately differentiated (Grade 2), and poorly differentiated (Grade 3). The more differentiated they are the more likely they are to metastasize, although pulmonary metastasis is very rare. MCT's cannot be diagnosed definitively without cytology or histopathology. They are best described by their biologic behavior as unpredictable, as they may become systemic and behave similar to a hematopoietic malignancy. The KIT immunophenotype uses immunohistochemistry to help give a more detailed prognostic evaluation for MCT's based on their cytoplasmic staining. Based on a study of 100 dogs with MCT's from the College of Veterinary Medicine, Michigan State University, an increased cytoplasmic KIT staining has been shown to occur in patients with a higher rate of local recurrence and decreased survival intervals. Based on these results, the authors feel a new prognostic classification for MCT's should be used based on their cytoplasmic KIT staining. Dogs with MCT's can be treated with surgery, chemotherapy, and/or radiation therapy. Surgery, ideally 2-3cm margins based on the Grade of MCT, and radiation therapy have the potential to be curative and are the most successful treatment options to date, while chemotherapy is only palliative. If excisional biopsy is incomplete, then re-excision with 3cm margins and/or radiation are the recommended treatment options. Once metastasis has occurred treatment is usually chemotherapy and supportive therapy. The wedge and rectangular resections were individually considered for the excisional biopsy; however due to the size and rostral location of the mass, and the owners concern with cosmesis the full-thickness labial advancement technique was selected. Although the infraorbital neurovascular bundle was ligated the collateral circulation to the lip and muzzle will be supplied by the facial artery and the contralateral infraorbital artery. The final histopathology report showed a Grade of II MCT with adequate surgical margins. Since muzzle MCT's are biologically more aggressive, continued monitoring of this area is recommended. The complete excision combined with chemotherapy should allow this dog a good quality of life through her senior years. The owners were very satisfied with the outcome, medically and cosmetically.

References: Wiggs R.B. & Lobprise H.B. 1997. Veterinary Dentistry: principles and practice. Lippincott-Raven, Philadelphia, PA, p.687. - McKelvey D. & Hollingshead K.W. 2003. Veterinary Anesthesia and Analgesia. 3rd ed. Mosby, St Louis, MO, p.15, 66-104. - Plumb D.C.. 2005. Veterinary Drug Handbook. 5th ed. Blackwell Publ., Ames IA. - Walton R.E. & Chiappinelli J. 1993. Prophylactic penicillin: effect on post-treatment symptoms following root canal treatment of asymptomatic periapical pathosis. J. Endod. 19:466. - Muir W.W., Hubbell J.A.E., Skarda R.T. & Bednarski R.M. 2000. Veterinary Anesthesia. 3rd ed. Mosby, St Louis, MO, p.20-22, 100-101. - DiBartola S.P. 1992. Fluid Therapy in Small Animal Practice. W.B. Saunders, Philadelphia, PA, p.502. - Hartsfield S.M. 1991. Advantages and guidelines for using ketamine for induction of anesthesia. Vet. Clin. North Am. Small Anim. Pract. 22(2)266-267. - Lumb W.V. & Jones E.W. 1997. Veterinary Anesthesia. 2nd ed. Lea and Febiger, Philadephia, PA. - Silness J. & Loe H. 1964. Periodontal disease in pregnancy. II. Corre-lation between oral hygiene and periodontal conditions. Acta Odont Scand. 22:121-135. - Loe H. & Silness J. 1963. Periodontal disease in pregnancy. I. Preva-lence and severity. Acta Odont Scand. 21:533-551. - Muhlemann H.R. & Son S. 1971. Gingival sulcus bleeding: a leading symptom in initial gingivitis. Helv. Odontol. Acta 15:107. - Ramfjord S.P. 1967. The Periodontal Disease Index (PDI). J. Periodon-tol. II 38:602. - Robinowich B.Z. 1956. The fractured incisor. Pediatric Clin. North Am. 3:979. - Beckman B.W. & Legendre L. 2002. Regional nerve blocks for oral surgery in companion animals. Comp. Cont. Educ. Pract. Vet. 24(6):439-444. - Mulligan T.W., Aller M.S. & Williams C.A. 1998. Atlas of Canine and Feline Dental Radiography. Veterinary Learning Systems, Trenton, NJ, p.124-152. -Wiggs R.B. & Lobprise H.B. 1997. Veterinary Dentistry: principles and practice. Lippincott-Raven, Philadelphia, PA, p.46. - Nelson R.W. & Couto C.G. 1998. Small Animal Internal Medicine 2nd ed. Mosby, St Louis, MO, p.1148-1150. - Morrison W.B.. 1998. Cancer in Dogs and Cats. Williams and Wilkins, Baltimore, MD, p.477-482. - Withrow S.J. & MacEwen E.G. 2001. Small Animal Clinical Oncology. 3rd ed. W.B. Saunders, Philadelphia, PA, p.261-273. - Kiupel M., Webster J.D., Kaneene J.B., Miller R. & Yuzbasiyan-Gurkan V. 2004. The use of KIT and tryptase expression patterns as prognostic tools for canine cutaneous mast cell tumors. Vet. Pathol. 41(4):371-377. - Simpson A.M., Ludwig L.L. et. al. 2004. Evaluation of surgical margins required for complete excision of cutaneous mast cell tumors in dogs. J. Am. Vet. Med. Assoc. 224(2):236-240. (Prospective Study, 17 Refs.). - Pavletic M.M. Atlas of Small Animal Reconstructive Surgery. 2nd ed. W.B. Saunders, Philadelphia, PA, p.306-311. - Lascelles B.D.X., Thomson M.J., Dernell W.S. et al. 2003. Combined dorsolateral and intraoral approach for the resection of tumors of the maxilla in the dog: a retrospective study. J. Am. Anim. Hosp. Assoc. 39:294-305. - Gieger G.L., Theon A.P. et. al. 2003. Biologic behavior and prognostic factors for mast cell tumors of the canine muzzle: 24 Cases (1990-2001). J. Vet. Intern. Med. 17(5):687-692. (Retrospective study, 27 Refs.)

INDEX TERMS: Labial, flap, biopsy, excisional, MCT.

030. Harvey C.E. 2007. **Use of antibiotics in management of patients with oral diseases: why the controversy?** *Pesquisa Veterinária Brasileira 27(Supl.).* Department of Clinical Studies, School of Veterinary Medicine, University of Pensylvania, Ryan-VHUP 3113, 3900 Delancey Street, Philadelphia, PA 19104, USA. E-mail: ceh@vet.upenn.edu

Introduction: Every mouth has a rich microbiological flora and contains structures that do not have a vascularized epithelial covering. This combination makes the concept of 'infection' in the mouth complex compared with other tissues.

Oral Bacteria: In addition to 'periodontopathogenic' organisms, bacteria commonly found in the mouth include organisms considered to be primary pathogens when cultured from other tissues - Staphs and Streps of every type, coliforms, *Proteus*, *Pseudomonas*, *Pasteurella*. Periodontal disease, caused by periodontopathogens in the dental plaque biofilm, is by far the most common oral infection. As the plaque biofilm matures and gingival inflammation starts to develop, the

plaque biochemical environment becomes richer, allowing anaerobic periodontopathogens, including spirochetes, to thrive. To prove the infectious nature of periodontal disease by applying Koch's postulates is not possible because of the complexity of the microflora in dental plaque. Periodontopathogens are defined by Sokransky's Postulates:

Association: The causative agent must be found in active 'sites' in higher numbers than in non-active sites.

Elimination: The elimination of the agent must stop the progression of disease.

Host response: The cellular or humoral immune response must validate the specific role of the agent in the disease.

Virulence factors: The agent must possess virulence factors that are relevant for the initiation and progression of the disease.

Animal models: The pathogenicity of the agent in an animal model must provide conclusive evidence that it can cause periodontitis.

A change from primarily periodontopathogens - predominantly anaerobes of the black-pigmented *Bacteroides* group (including *Porphyromonas* and *Prevotella* spp.) - to a wider variety of organisms, particularly aerobic Staphs and Streps, is considered indicative of reversion from periodontal disease to oral health. However, qualitative and quantitative assessment of the bacteria in direct contact with infected periodontal tissues is challenging, and inconsistent culture results are often found in microbiological studies of periodontal disease. The ability of an individual animal to resist a given gingival bacterial load varies greatly, depending on immunological competence, differences in protective constituents of oral fluids, and other factors such as age, stress, nutritional status, concurrent infections, distant-organ health status and probably additional factors that are incompletely understood or not yet known. What is the purpose of an antibacterial drug when an infection is located in a tissue that is always exposed to a rich bacteriological flora? Is re-infection the inevitable result of contamination following antibacterial treatment?

Antibacterial Drug Treatment - Role in Management of Oral Diseases: In a healthy mouth, the well vascularized oral tissues are adapted to existing in a contaminated environment. Use of an antibiotic drug is indicated in patients with oral diseases to treat either local infection or to prevent settlement and growth of bacteremic organisms in distant sites in at-risk patients.

Considerations of the patient's general health aside, patients with contaminated oral sites that are already open for drainage (i.e., periodontal pockets) or that will be open for drainage following a procedure such as scaling or extraction generally do not require antibiotic treatment. Thus, treatment of extensive periodontal disease by a combination of scaling and extraction is, of itself, not an indication for treatment with an antibacterial drug. Periodontal infection is treated by removing the cause (plaque and calculus) so that the tissues can revert to health; antibiotic administration is an auxiliary treatment.

Indications for Use of Antimicrobial Drug in Patients with Oral Infection:

Treatment of Local Infection. An antibiotic can shift the plaque flora from a pathogenic to a commensal mix. Combining this effect with the mechanical removal of calculus and plaque will enhance the likelihood of stabilization of healthy flora in the healing tissues.

1. Local tissues are severely infected and treatment including retention of teeth would require periodontal surgery that will expose infected bone, or teeth surrounded by severely infected bone are to be extracted. The local tissues will withstand the effects of surgery better and healing will be more rapid if local periodontal infection is controlled at the time of the dental procedure. In this circumstance, antimicrobial treatment is commenced several days prior to surgery and is continued for several days following surgery.

2. When the periodontal infection has progressed to wide-spread osteomyelitis (i.e. is affecting the trabecular bone and outer cortical bone of the involved jaw) and infected bone will be left in place following extraction or deep scaling. Antimicrobial treatment is best started several days prior to the procedure, and continued for several weeks following the dental procedure.

3. When mucosal immunopathy has resulted in oral ulceration that is exacerbated by contact with even small amounts of dental plaque accumulation, such as in ulcerative stomatitis in dogs and possibly stomtatitis in cats.

Prevention of Bacteremia. Bacteremia is frequent in patients with gingivitis and active periodontitis, and is rapidly cleared by the reticulo-endothelial system in otherwise healthy patients. However, there is an association between severity of periodontal disease and distant organ abnormalities. Anaerobic culture methods were not used in most studies reporting the prevalence of bacteremia associated with dental treatment; more recent studies have shown that the full range of aerobic and anaerobic bacteria found in local periodontal infection also can cause bacteremia. Treatment with an antibiotic drug is indicated when the patient's distant tissues are at risk as a result of bacteremia during a dental procedure.

Examples of Indications for Prevention of Bacteremia

1. Patients with clinically evident cardiac disease. Although a cause-and-effect relationship between periodontal infection and endocarditis has not been proven, turbulent flow in an abnormally functioning heart may enhance the attachment of bacteremic organisms to the heart valves.

2. Patients with clinically-evident renal or hepatic disease, or with uncontrolled hormonal disorders such as diabetes mellitus or hyperadrenocorticism. When cellular metabolism is depressed by systemic disease, the oral tissues are less able to respond normally to the trauma of the procedure, and the kidney and liver may be at risk of infection from bacteria that become lodged in sludged blood vessels.

3. Patients with prostheses, such as ocular prosthesis, total hip replacement or cruciate ligament repair using a non-absorbable material, or patients whose spleen has been resected (the spleen is a primary site of the reticulo-endothelial filter that eliminates bacteremia within several minutes in healthy patients).

4. Patients in which a clean surgical procedure will be performed during the same anesthetic episode, such as an older dog with a mammary mass and severe periodontal infection. In this case, continuation of the antimicrobial treatment for several days post-operatively is recommended to ensure that any bacteria trapped in blood clots are exposed to an effective concentration of the antimicrobial drug.

5. Patients with immunopathies or who are undergoing treatment with immune-suppressive drugs, such as cancer chemotherapy or for treatment of severe skin diseases and other severe reactive or auto-immune disorders.

A broad-spectrum bactericidal antibiotic that achieves a high concentration in serum is indicated. Peri-operative treatment is all that is required (single dose orally the morning of the procedure, or IV during induction of anesthesia, repeated every 2-3 hours during prolonged procedures).

Which Antibiotic to Select? Broad-spectrum or narrow-spectrum? When an antimicrobial drug is administered to treat periodontal infection, it must be effective against the pathogenic organisms likely to be present, and must reach an effective concentration in serum and periodontal pocket fluid. Because of the breadth of the oral flora, and the possibility that bacteria may be pathogenic locally or as a result of bacteremia, a broad-spectrum antibiotic is indicated to ensure effectiveness against local and contaminating pathogens.

Culture and Sensitivity Testing or Not? Because of the microbiological challenges noted previously and the delay in treatment that would result, bacterial culture and susceptibility testing are rarely performed in oral disease patients.

Specific Antibiotics: Based on susceptibility testing of gingival samples from a group of patients with gingivitis, the most broadly effective antimicrobial drug currently approved for use in dogs and cats is **amoxicillin-clavulanic acid**. For deep-seated, long-standing periodontal bone infections, **clindamycin** has good activity against oral anaerobes, but has less broad-based aerobic activity compared with amoxicillin-clavulanate. **Metronidazole** is effective against oral anaerobes, but has no aerobic bacterial activity; it is particularly effective for both short-term and long-term/intermittent treatment of ulcerative stomatitis, though whether the beneficial effect is antibacterial or a poorly understood immunological effect on these immunopathic tissues is not yet clear. I have had no direct experience with **metronidazole-spiramycin** combination that is approved for treatment of oral infections in Europe. The **tetracycline** group of antibacterial drugs is now rarely used for peri-operative treatment during dental procedures because of the risk for development of plasmid-derived antibacterial resistance; however, there is renewed interest in the tetracycline group because, even at sub-antimicrobial doses, tetracyclines have an anti-collagenase effect that can protect periodontal tissues against inflammation-induced destruction. **Doxicycline** is available for local injection into periodontal pockets in an absorbable gel to provide a high concentration locally. For some specific oral infections (such as actinobacillosis osteomyelitis), treatment with a **penicillin/sulfonamide** combination for several months is required. Fortunately, such infections are uncommon, and are typically identified only as a result of failure of 'standard' treatment.

Discussion and Conclusion: A patient under consideration for treatment of oral infection may have no, one or two indications (local disease, distant organ prophylaxis) for use of an antibacterial drug as part of his/her dental treatment. Each of these indications may have a different recommended treatment period, and the various sub-types of local indication and systemic risk also have different recommended treatment periods.

INDEX TERMS: Periodontal disease, oral infection, antimicrobials, dogs, cats.

031. Harvey C.E. & Lai C.-H. 2007. **Bacterial isolation results in cats with stomatitis: Comparison of periodontal pocket and non-gingival stomatitis lesion samples.** *Pesquisa Veterinária Brasileira 27(Supl.).* Department of Clinical Studies, School of Veterinary Medicine and Department of Periodontics, School of Dental Medicine, University of Pennsylvania, Ryan-VHUP 3113, 3900 Delancey Street, Philadelphia, PA 19104, USA. E-mail: ceh@vet.upenn.edu

Introduction: Periodontal pocket and stomatitis lesion samples were obtained using paper points from thirty eight cats with clinical stomatitis. The most prevalent species were identified and antibiotic susceptibility testing was performed.

Materials and Methods: Microbiological techniques used included dark-field morphometric examination, immunofluorescence testing for presence of standard human periodontopathogens, aerobic and anaerobic culture, and microdilution and E-test strip susceptibility testing of four antimicrobial drugs (amoxicillin-clavulanic acid, clindamycin, metronidazole, and pradofloxacin). The cats were treated with either amoxicillin-clavulanic acid or pradofloxacin for 14 days and sample collection was repeated.

Results: On morphometric examination, both the number and proportion of motile rods and spirochetes decreased following treatment, and the number and proportion were both lower when comparing stomatitis lesions with periodontal pocket samples. On immunofluorescence testing for *Porphyromonas gingivalis, Tannerella forsythensis* and *Campylobacter rectus*, *P. gingivalis* was the most common periodontopathogen identified. *P. gingivalis* was found less commonly in stomatitis lesions than in periodontal pocket samples. It was reduced in frequency and proportion for both peridontal pocket and stomatitis lesion samples post-treatment compared with pre-treament. A very wide range of bacterial species was found on culture in both sites sampled. Susceptibility data showed similar results for amoxicillin-clavulanic

acid and pradofloxacin; resistance to clindamycin and metronidazole was more common, particularly to metronidazole in aerobic bacteria. Susceptibility testing results were similar when comparing pre- and post-treatment samples. There was good correlation in the results of the two susceptibility testing methods used.

Discussion and Conclusion: In this short-term study, bacteria found in periodontal pockets and on the surface of stomatitis lesions in cats are affected by treatment with a broad-spectrum antimicrobial drug.

INDEX TERMS: Microbiology, periodontal disease, stomatitis, cats, amoxicillin-clavulanic acid, pradofloxacin.

032. Hoffman S. 2007. **Dental disease in captive orcas.** *Pesquisa Veterinária Brasileira 27(Supl.).*

North Florida Veterinary Dentistry, Jacksonville, Florida 32226, USA (www.pettoothvet.com).
E-mail: shoffmandvm@gmail.com

Introduction: *Orcinus orca*, commonly called killer whale or orca, is a member of the Cetacea (dolphin group). It has monophydont tooth development, thecodont tooth anchorage, brachyodont crowns, and homodont dentition. An orca has 40-56 teeth (Wiggs & Lobprise 1997).[1] The mandible of cetaceans acts as an integral part of the auditory system. The caudal 2/3 of the mandible is used as an acoustic horn in dolphin and whale hearing. For this reason, only the anterior 1/3 of the mandibles are solid - the caudal 2/3 are hollow (St Leger 2004).[2] Dental disease involving the pulp is not uncommon in captive orcas and is also present in wild orcas. One trainer, having worked with upwards of fifteen orcas over seventeen years, estimates that 30% of orcas he worked with in captivity had dental problems. These whales have lived in France, California, Texas, New York, Ohio, and Florida (Delgross 2004). Some were bred in captivity and some were captured from the wild. As part of this study, several orca skulls (both captive and wild) in museum collections were studied. In all of the orca specimens examined, the teeth had open apices, with the following exceptions: some of the smaller most mesial and distal teeth in specimens having more than 40 teeth and one tooth having pulp obliteration.

Cases Report: Tooth fractures in wild orcas lead to pulp exposures. Malocclusions have also been observed in some orcas, which may lead to abnormal forces and dental trauma. In captivity, some orcas rub their mandibular teeth on the pool walls repeatedly, causing abrasion of these teeth and eventual pulp exposures. The reason for the tooth rubbing behavior is unknown but has been speculated to be an obsessive compulsive behavior or boredom. Dental trauma and pulp exposures have been noted in orcas as young as 5-6 years of age. In captive orcas, once the tooth has been damaged and the pulp is exposed, the management option that has become customary is to "drill" the pulp cavity open further to allow drainage and flushing of the exposed pulp. The exposed pulp cavities become contaminated with food and other debris from the pool water. The trainers flush the exposed pulp cavities multiple times per day with various solutions. The drainage from the open pulp cavity resolves once granulation tissue fills the cavity (St Leger 2004). In one case involving a female orca in captivity, a dentin bonding agent[3] was applied monthly to teeth with near pulp exposures. Thermography was unsuccessfully attempted in this patient to locate heat in teeth that may have pulpitis. In another case involving an eleven year old female orca in captivity, there was bleeding reported from the teeth that had been "drilled" on the left mandible. Four adjacent teeth (teeth 3-6 on the left side) had open pulp cavities. The teeth had been "drilled" several months previously and had a history of intermittent bleeding. On the day of examination, the pulp cavities that were bleeding were probed with cotton swabs. The depths of the cavities measured 4.9cm, 5.4cm, 5.2cm, and 5.9cm from mesial to distal. (The depth of the left seventh alveolus measured in a museum specimen was 7.5cm.) There was a visible diffuse firm swelling on the lingual side on the mandible in the area of the drilled teeth. The depths of the pulp cavities of the teeth that had been drilled on the right mandible were 1.2cm, 1.5cm, and 1.4cm (teeth 2-4). There was no bleeding from the right mandibular teeth and what appeared to be firm pink soft tissue was grossly visible within the pulp cavities of these teeth. The open pulp cavities were being flushed 2-4 times/day with a dilute iodine solution using a waterpick. The trainer had noticed an odor from the left mandibular teeth, particularly at the time of the early morning flush and assumed it was from food and other debris in the pulp cavities. A recommendation was made to flush with 0.12% chlorhexidine solution[1], at least once daily, because of its substantivity and antimicrobial benefits (Robinson 1995). The trainer reported a resolution of the odor from the teeth and bleeding had stopped after a few days of flushing with the chlorhexidine solution. Within the next two months, this orca was relocated to another state and there has been no further follow-up. Other management options for the exposed pulps, some of which are vital and some non-vital have been tried. Root canal therapy is not an option due to the open apices in captive orca teeth. Apparently, this option has been tried in spite of the apical anatomy, without success due to the inability to control hemorrhage. Local anesthesia nerve blocks have not been perfected and lengthy procedures are not preferred. An ideal solution for treatment of these endodontically involved teeth might include an implant that could be placed quickly, did not shrink or swell, is biocompatible, can withstand further abrasive dental trauma, and be color matched to the adjacent teeth. This would need to be placed in the tooth of the orca without general anesthesia. Dental chemical erosion has recently been identified in a *Pseudorca crassidens* (false killer whale). The whale is a sixteen year old, 507 kg male living in captivity in a marine park in the Philippines. He has been in captivity for eleven years and currently resides in an ocean water, plastic mesh fence enclosure with several female Pseudorcas. He has a history of gradual generalized dental erosion on the lingual, incisal and occlusal surfaces over four months with rapid progression more recently. This Pseudorca has a chronic history of frequent regurgitation (much more frequent than the females in the enclosure). The pattern of erosion of the maxillary and mandibular teeth is consistent with the pattern seen in people

[a] Optibond, Kerr Corp, Orange, CA.

[b] Nolvadent, Fort Dodge Animal Health, Fort Dodge, IA.

having progressive chemical dental erosion from gastric fluids in those with bulimia or gastroesophageal reflux (Sturdevant 2002). Recommendations for treatment included: 1) topical fluoride treatments (gel, foam, or sealants) to decrease the acid solubility of the dental enamel, influence its hardness, decrease the rate of demineralization, enhance the rate of remineralization and increase resistance to dental caries (Shugars 2002), 2) identify the etiology of the excessive regurgitation and control of this behavior, and 3) intraoral radiographs to identify endodontic disease. Follow-up is pending.

Discussion and Conclusions: Dental disease in captive orcas is present worldwide. To the author's knowledge, there are no published references documenting diagnostics, treatment planning or outcome of dental disease treatment in this species. Our ability to treat orcas requires: 1) knowledge of orca dental and oral anatomy, 2) knowledge of etiology and progression of dental disease, 3) restraint and anesthesia expertise, 4) an understanding of orca behavior, and 5) application of dental procedures and materials appropriate in this species. This requires a team of professionals including trainers, aquatic animal veterinarians, anesthesiologists, and dentists working together to address dental disease in captive orca.

Acknowledgements: To the Museums which provided access to their collection of *Orcinus orca* specimens for this study: 1) University of Michigan Museum of Zoology - Mammal Division, Ann Arbor, MI www.ummz.lsa.umich.edu/mammals; 2) Skulls Unlimited Museum of Osteology, Oklahoma City, OK, (Orca skulls donated by Sea World from several locations), www.education@skullsunlimited.com; 3) National Museum of Natural History, Smithsonian, Washington, DC.

References: Wiggs R.B. & Lobprise H.B. 1997. Veterinary Dentistry: principles & practice. Lippincott Raven, Philadelphia, p.55, 56, 542. - St. Leger Judy 2004. (Director of Pathology, Sea World, San Diego): personal e-mail, May. - Delgross D. 2004. (Orca Trainer, Six Flags, Ohio): personal interview. - Robinson J.1995. Chlorhexidine gluconate, the solution for dental problems. J. Vet. Dent.12(1):29-31. - Sturdevant J.R. 2002. Clinical Significance of Dental Anatomy, Histology, Physiology, and Occlusion. Art & Science of Operative Dentistry. 4th ed, Mosby, St. Louis, Missouri, p.21.

INDEX TERMS: Orcinus orca, captive orcas, dental disease.

033. Hofmann-Appollo F. 2007. **Secondary hyperparathyroidism in chronic renal disease in dogs, rubber jaw.** *Pesquisa Veterinária Brasileira 27(Supl.).* Mestranda no Departamento de Cirurgia, FMVZ-USP, São Paulo, SP, Brazil 05508-270. E-mail: fehofmann@usp.br

Introduction: The parathyroid hormone (PTH) is a polypetidic hormone that increases the osteoclastic activity, resulting in calcio and phosphorus resorption of bone. Decreasing glomerular filtration causes retention of phosphate, and the resulting hyperphosphatemia then causes hypocalcemia, wich is the stimulus for the increase of parathormone secretion. The vitamin D has great effect on high calcium absorption on intestine. However, it needs to be converted on liver and kidney to its final active product, 1,25-dihydroxycholecalciferol (1,25-$(OH)_2$-D_3). The kidneys have the main role in this process because they are the greatest source of 1-á-hydroxilase, that transform 5- hydroxycholecalciferol in the active form of vitamin D_3. At chronic kidney failure, the 1,25-diidroxicolecalciferol production by the kidney is impaired, decreasing the intestinal transport of calcium that causes hypocalcemia. The result is calcium resorption of bone to maintain homeostasia. Resorbed bone tissue is replaced by connective tissue. The osteopenia that results is generalized but does not affect the bones uniformly. With secondary hyperparathyroidism, both renal and nutritional, there is a hierarchy of bone loss in decreasing order: the jaw bones, ribs, vertebrae and, finally, long bones. The cribiform plate of alveolar bone, recognized by *Lamina dura* in radiographies and the marrow bone of jaws are more susceptible to demineralization than others, and are affected earlier. Clinically, there can be noted jaw flexibility and teeth mobility. These signs are compatible with rubber jaw. The bone decalcification and pathologic fractures are the most advanced degree of chronic renal disease, but occur only in chronic cases whereas most of them die before, because of renal complications. The young dogs with few months can present swell and flexibility of the jaw bones and ulcerative gingivo-stomatitis. The clinical signs of renal disease can or can not be present like emesis, dehydration, poliuria and polidipsia. The diagnostic consists in clinical, radiographic and laboratorial findings. High concentrations of PTH, hyperphosphatemia and normal or reduced calcium concentrations are common findings.

Case Report: We examined at Laboratório de Odontologia Comparada (LOC) from Departamento de Cirurgia, Faculdade de Medicina Veterinária e Zootecnia, Universidade de São Paulo, a mixed breed dog, five years old, with supposed jaw fracture and it had been referred to emergency treatment. The animal was submitted to general inhalatory anesthesia to intra oral radiographic examination and fracture treatment. At this moment, a general flexibility of jaws was detected. The radiography showed severe osteopenia. The anesthesia procedure was interrupted and the dog conducted to the internal medicine department for laboratory exams and support therapy. The abnormal laboratorial findings were: Urea 329.7 mg/dl (normal until 40mg/dl), Creatinine 5.8mg/dl (until 1.5mg/dl), Phosphorus 13.9mg/dl (until 6.2mg/dl), Calcium 11.1mg/dl (until 11.3mg/dl), Pancitopenia, Trombocitopenia. The therapy started at the same day but the owner decided not to continue it. The animal died at home 30 days after diagnoses with the same symptoms.

Conclusion: Although we do not have updated references about the rubber jaw treatment, it is not common in our routine. Unfortunately, when diagnosed, the animal already had a severe degree of renal disease, and few chances of survival.

References: Cappen C.C., Martin S.L. 1977. Calcium metabolism and disorders of parathyroid glands. Vet. Clin. North Am. 7(3):513-548. - Chew D.J. & DiBartola S.P. 1989. Diagnosis and pathophysiology of renal disease, p.1893-1961. In: Ettinger S.J. (ed.), Textbook of Veterinary Internal Medicine. W.B. Saunders, Philadelphia. - Bovee K.C. 1984. Metabolic disturbances of uremia, p.585-591. In: Bovee K.C. (ed.), Canine Nephrology. Harwal Publishing

Co, USA. - Baumhammers A., Stallard R.E. & Zandar H.A. 1965. Remodeling of alveolar bone. J. Periodont. 36:411-439. - Weller R.E., Cullen J. & Dagle G.E. 1985. Hyperparathyroid disorders in the dog: primary, secondary and cancer-associated (pseudo). J. Small Anim. Pract. 26(6):329-341. - Sarkiala E.M., Dambach D. & Harvey C.E. 1994. Jaw lesions resulting from renal hyperparathyroidism in a young dog: a case report. J. Vet. Dentistry 11(4):121-124. - Carmichael D.T., Williams C.A. & Aller M.S. 1995. Renal dysplasia with secondary hyperparathyroidism and loose teeth in a young dog. J. Vet. Dentistry 12(4):143-146.

INDEX TERMS: Secondary hyperparathyroidism, rubber jaw, renal disease, dog.

034. Kressin D.J. 2007. **Pain management for the veterinary patient.** *Pesquisa Veterinária Brasileira 27(Supl.).* Animal Dental Centers, Oshkosh/Milwaukee Wisconsin-Animal Emergency Center, United States. E-mail: dalekressin@ntd.net

Introduction: Pain management for the veterinary patient has developed tremendous interest in the last decade. In human medicine, pain management has been described as the "fifth vital sign" (Wolf 2006). Pain is a crucial vital sign for patient assessment as are temperature, pulse, respiration and blood pressure. Pathways of nocioception have been well defined in all mammals including humans and companion animals, canines and felines commonly treated by veterinarians (Gaynor et al. 2006). Since these pathways are similar, any stimulus or injury that would be painful for people are highly likely to be painful for animals and therefore should either be pre-empted or managed.

Materials and Methods: There are several critical considerations for veterinary patient pain management. The clinician must understand that veterinary patients experience pain. Pain is an "unpleasant sensory and emotional experience associated with actual or potential tissue damage" (International Association for the Study of Pain 1979). An accurate patient history is the starting point. If the patient has an oral disease, the duration of the problem is important. Acute pain has been described as the result of the stimulation (recent dental fracture or oral surgery) of a normally functioning nervous system. It allows avoidance or the minimization of tissue damage. Chronic pain (stomatisis in feline patients) is typically experienced over a longer time period often arbitrarily set at 3-6 months (Woessner 2006). Clinicians must consider the potential sources of pain (nocioceptive, inflammatory or neuropathic). To manage pain, it is useful to understand the classic pathways of transduction, transmission, modulation and pain perception. With this fundamental understanding, we can develop balanced anesthesia protocols and multimodal approaches to pain management. Additionally, we can apply complementary and alternative therapies.

Discussion and Conclusions: Pain management can effectively improve patient well being. Preempting and treating acute pain can help prevent the development of chronic pathologic pain. Pain management can effectively prevent pain amplification (allodynia, hyperalgesia and hyperesthesia), avoid depression, reduce infection and improve tissue healing. This allows for improved patient function and quality of life.

References: Wolf B.B. 2006. A brief history of pain from a personal perspective, p.3-34. In: Boswell M.V. & Cole B.E. (ed.), Weiner's Pain Management: a practical guide for clinicians. 7th ed. CRC Press. - Gayner et al. 2006. The Essential Guide to Pain Management, a Complete Resource for Veterinary Pain Management. The Companion Animal Pain Management Consortium, p.2-42. - Woessner J.W. 2006. Overview of Pain: Classification and Concepts, p.35-48. In: Boswell M.V. & Cole B.E. (ed.), Weiner's Pain Management: a practical guide for clinicians. 7th ed. CRC Press.

INDEX TERMS: Veterinary pain management.

035. Kressin D.J. 2007. **The Importance of veterinary dental radiography.** *Pesquisa Veterinária Brasileira 27(Supl.).* Animal Dental Centers, Oshkosh/Milwaukee, Wisconsin-Animal Emergency Center, United States. E-mail: dalekressin@ntd.net

Introduction: Intraoral dental radiography is fundamental to the practice of veterinary dentistry (DeForge & Colmery III 2000). As in other disciplines of veterinary medicine, it is important to establish a diagnosis, prognosis and treatment plan prior to treating dental patients.

Materials and Methods: A dental radiograph machine is useful in veterinary dental practice. Images can be produced using dental radiograph film or digital sensors. There are advantages and disadvantages in using either radiograph film or digital sensors.

Results: Dental radiograph images can help the veterinarian in identifying tooth, bone or soft tissue pathology. They help establish diagnosis, in treatment planing and in performing dental procedures. These images allow the veterinarian to verify that procedures have been accurately performed and for documentation in the medical record (Mulligan et al. 1998).

Discussion and Conclusions: Veterinary dental radiography is highly valuable for veterinarians in performing dental procedures. The author has a tremendous passion for veterinary dentistry and interest in veterinary radiology. A 40 to 45 minute powerpoint presentation will be provided that will emphasize the importance of intraoral veterinary dental radiography. A brief question period will follow the presentation. In canine and feline patients, 2/3 of the tooth lies below the gingival sulcus and are not viewable on oral examination. In other species such as lagamorphs and rodents, a greater amount of tooth structure is located subgingivally. Intraoral radiography helps in the evaluation of the subgingival tooth as well as adjacent structures. The presentation will describe when and why intraoral radiography is beneficial and it will emphasize the value of these images. Intraoral

radiography is very useful in evaluating normal teeth and oral structures (bones of the skull and periodontal tissues). These images allow for the identification of abnormal teeth, abnormal skull anatomy, oral/dental fractures, dental caries, foreign bodies (objects) and periodontal disease. Periodontal disease is the most prevalent disease in domestic species (such as canine and feline) and intraoral radiography is essential in the diagnosis, staging, treatment planing as well in the treatment. Intraoral radiography helps in performing and the documentation of most dental procedures. Specific clinical case examples will be discussed.

References: DeForge D.H. & Colmery III B.H. 2000. An Atlas of Veterinary Dental Radiology. Iowa State Press, Ames. - Mulligan T.W., Aller M.S. & Williams C.A. 1998. Atlas of Canine and Feline Dental Radiography. Veterinary Learning Systems, Trenton, NJ.

INDEX TERMS: Veterinary, dental, radiology.

036. Lacerda M.S. & Alessi A.C. 2007. **The histobacteriologic aspects and electronic microscopy scanning of the incisor teeth involved in periodontal disease of dogs after periodontal scaling**. *Pesquisa Veterinária Brasileira 27(Supl.).* Veterinary Medicine Course, UNIUBE, Uberaba, MG 34061-500, Brazil. E-mail: moacir.lacerda@uniube.br

Introduction: The periodontal disease occupies a prominent place reaching about 80% of the dogs over 4 years old (Harvey & Emily 1993). In the periodontal disease the exposure of the cementum to the buccal environment occurs (Borghetti et al. 1987, Nisengard & Bascones 1987), favoring the penetration of microorganisms (Olgart et al. 1974, Mjor 1983, Adriaens et al. 1987). Langeland et al. (1974), Wirthlin (1981) and Eide et al. (1983), showed histologically the penetration of microorganisms into the cement exposed to the periodontal bag. Teeth abrasion (Borghetti et al. 1987) does not avoid the installation of bacteria in the dentinal tubules exposed after the periodontal treatment (Gantes et al. 1992). The anaerobic Gram-negative microbiota as *Bacteroides (Phorphyromonas) asaccharolyticus* and *Fusobacterium nucleatum* is found mainly on the radicular subgingival surface (Sarkiala et al. 1993). The most common pathogens in clinical periodontics are anaerobic Gram-negative rods, especially the pigmented group, and certain Gram-positive coccos (Sarkiala et al. 1993). The treatment of the periodontal disease and the maintenance of the periodontal health involve the elimination of the dental plaque and dental calculi, and also the establishment of dental plaque control. To achieve this objective, it is necessary to treat the surface of the teeth with abrasion procedures, planning and polishing with proper instruments for such purpose. Among the operative procedures, the abrasion has gotten great impulse with the development of the manual instruments, which came to be widely used (Rabbani et al. 1981, Khatiblou & Ghodssi 1983, O'leary 1986). Other means of abrasion were tried through the development of new methodologies. The methodology used nowadays in higher evidence is the ultrasonic method, through the pioneer work of Zinner (1955). The ultrasonic apparatus are extensively used by the Human and Veterinary Dentistry for their effectiveness in the removal of dental calculi of crowns and roots, and by their comfortable usage (Fraguela et al. 2000). They are also used for curettage of soft tissues of the wall of the periodontal (Brine et al. 2000). The objective of the present study was to accomplish histobacteriologic and ultrastructural evaluations of the teeth of dogs involved with the periodontal disease, looking for checking the bacterial contamination of the cement, dentinal tubules, percentage of raw dentin in abraded faces compared to the non-abraded ones.

Materials and Methods: The sample used is constituted of 40 inferior and superior incisor teeth with periodontal advanced involvement (mobility level III) of dogs with or without defined race, adults from 3 to 10 years old, weight varying from 1.9 to 13.0 kg, males or females, coming from the Veterinary Hospital of the Federal University of Uberlândia, the College of Agrarian and Veterinarian Sciences, Jaboticabal Campus of Unesp, and the Veterinary Dentistry Center (Odontovet), and distributed at random in two groups of equal number. The teeth of Group I were abraded with curette and the ones from Group II with ultrasonic dentistry, being the mesial face of the root destined to verify the action of the instrument (treated surface) and the distal was considered as control (non treated surface). For the abrasion of the radicular surface of the teeth from Group I a sharpened periodontal curette kind Gracey Hu-Friedy nr. 5/6 was used for each tooth. For Group II it was used a point coupled to the dentistry ultrasonic equipment piezo-electric of variable frequency from 30-40 cycles per second (KHertz). With the tooth already fixed in formaldehyde, the tooth plaque was stained by an evinced solution of basic fuchsine. The dental surface was abraded until it was considered clinically clean by visual check-up. To make the histological processing procedures easy, the specimen were sectioned transversally with 6 micrometers of thickness. The presence or absence of the dental plaque in the residual radicular structure was studied. The percentage of raw dentine considering the total area treated of the histological sections. Two samples of the material of each Group were drawn for scanning electronic microscopy check-up.

Results: In the optical microscopy the distal face presented alteration where the cementum, beyond the irregularities, had continuity solution and the penetration of microorganisms into its structure in several degrees of depth. Beyond the cementum, the dentine in some dental elements was contaminated in several levels of depth. In the mesial face, 16 teeth had no plaques in Group I and II. The areas undergone to the abrasion procedures presented variable thickness and extension of the residual cementum, remaining frequently amounts of raw dentine, which varied from 25% to 100% of the area treated. The residual cementum was contaminated. In the area treated by the curette and ultrasonic procedure there could be observed the presence of solution areas of continuity of the cement exposing the dentine. Despite the superficial dentine was free of microorganisms, there existed dental tubules contaminated in the depth. The analysis by scanning electronic microscopy of the samples of teeth from Group I and II confirmed the optical microscopy. The presence of dental plaques and dental calculus

in the control face of the teeth from both Groups was observed, as well as the interface of the dental calculus and cementum. In both treatments it could be seen that the cementum obstructed the dental tubules and there were some areas with open dental tubules after the abrasion.

Discussion: In the optical microscopic check-up of the sample from Groups I and II demineralization of cementum and loss of radicular substance was observed (Mjor 1983). The analysis of the samples in scanning electronic microscopy allowed to accomplish an evaluation of the controlled and treated surfaces of the teeth and presence of dental plaques, the efficiency of the instruments used, the exposure to the dental tubules after treatment, and made it also possible to observe the calculus interface and the treated area and the penetration of dental tubules by bacteria (Adriaens et al. 1987, Gantes et al. 1992, Bergenholtz & Babay 1998). For each treatment a curette and an ultrasonic point was used. This procedure was applied for not having other variables (sharpening, cut effective area) during the abrasion process. Contamination by microorganisms of variable depths in Group I and II were observed, from a simple existence of superficially deposited plaques on the radicular surface to the total destruction of the cementum or dentine with consequent exposure of the dental tubules (Langeland et al. 1974, Wirthlin 1981, Eide et al. 1983, Adriaens et al. 1987). The observation of the treated surfaces showed alterations which occurred from histologically clean areas, protected or not by cementum, and others with raw dentine contaminated or not and frequently in depth of difficult clinical access. The treated faces which were histologically free of plaques or microorganisms represented 80% of Groups I and II. The presence of residual plaques on the treated surface (20% for both groups) can be explained by the little pressure during the use of the instrument, anatomic irregularities and that, by the clinical observation of the surface clinically clean, some plaque can still remain, which only could be observed histologically. There occurs less raw dentine with the use if the ultrasonic procedure, as proved by the histological analysis of the cementum for this group, which shows a decrease of its thickness and which remains residual in counter position with the use of the curette, which results in more raw dentine. The greatest amount of residual cementum in the treated area of Group II can also be due to the time of action of the ultrasonic procedure at the radicular structure. There was contamination of the dental tubules of the control and the treated faces of both groups. Even if the instruments used draw all the cementum and smooth the dentine, there still is the contamination in different levels in the dentine in variable depth not allowing the action of the curette and the ultrasonic (Adriaens et al. 1987, Borghetti et al. 1987). Probably the mechanical action itself is not able to remove bacteria present in the radicular dentine (Borghetti et al. 1987). It is suggested that all the cementum affected by the periodontal disease should be removed, because it is possible that a mechanical removal of the endotoxin may also occur.

Conclusion: The usage of the periodontal curette according to Gracey has shown to be more effective for the periodontal treatment than the treatment by ultrasonic piezo-electric dentistry. Both treatments do not dislodge bacteria from the residual contaminated cementum or deeper levels of dentine, especially from the dental tubules. Examining clinically smooth and hard surfaces of teeth, the microscopic check-ups showed that those can be composed of dentine, cementum or a combination of both, and its clinical differentiation is not accurate.

References: Adriaens P.A., Edwards C.A., Boever J.A. & Loesche W.J. 1987. Ultrastructural observations on bacterial invasion in cementum and radicular dentin of periodontally diseased human teeth. J. Periodontol. 59(8):493-503. - Bergenholtz A. & Babay N. 1998. Scanning electron microscopy of the root surface texture of extracted periodontally diseased teeth following various etching and chelating regimens. Int. J. Periodont. Rest. Dent. 18:171-179. - Borghetti A., Mattout P. & Mattout C. 1987. How much root planning is necessary to remove the cementum from the root surface? Int. J. Periodont. Rest. Dent. 7(4):23-29. - Brine E.J., Marretta S.M., Pijanowski G. J. & Siegel A.M. 2000. Comparison of effects of four different power scalers on enamel tooth surface of the dog. J. Vet. Dent. 17(1):7-21. - Eide B., Lie T. & Selvig K.A. 1983. Surface coatings on dental cementum incident to periodontal disease. I. A scanning electron microscopy study. J. Clin. Res. 10(2):157-171. - Fraguela J.L.V., Vallès M.A.V. & Calvo L.J.E. 2000. Effects of ultrasonicdental scaling on pulp vitality in dog: an experimental study. J. Vet. Dent. 17(2):75-79. - Gantes B.G., Nilvéus R., Lie T. & Leknes K. 1992. The effect of hygiene instruments on dentin surfaces: scanning electron microscopic observations. J. Periodontol. 63(3):151-157. - Harvey C.E. & Emil P.P. 1993. Small Animal Dentistry. Mosby-Year Book, St Louis. 413p. - Khatiblou F.A. & Ghodssi A. 1983. Root surface smoothness or roughness in periodontal treatment. J. Periodontol. 54(6):365-367. - Langeland K., Rodrigues H.H. & Dowden N.E. 1974. Periodontal disease, bacteria and pulpal histopathology. Oral Surg. 37(2):257-270. - Mjor I.A. 1983. Reaction patterns in human teeth. CRC Press, Boca Raton, p.157-220. - O'leary T.J. 1986. The impact of research on scaling and root planning. J. Periodontol. 57(2):69-75. - Olgart L., Brannstrom M. & Johson G. 1974. Invasion of bacteria into dentinal tubules: experiments *in vivo* and *in vitro*. Acta Odont. Scand. 32:61-70. - Rabbani G.M., Mjor M.A. & Caffesse R.G. 1981. The effectiveness of subgingival scaling and root planning in calculus removal. J. Periodontol. 52(3):119-123. - Sarkiala E.M., Asikainen S.E.A., Kanervo A., Junttila J. & Jousimies-Somer H.R. 1993. The efficacy of tinidazole in naturally occurring periodontites in dogs: bacteriological and clinical results. Vet. Microbiol. 36:273-288. - Wirthlin M.R. 1981.The current status of new attachment therapy. J. Periodontol. 52(9):529-544. - Zinner D.D. 1955. Recent ultrasonic dental studies including periodontia. J. Dent. Res. 34:748. (Abstract).

INDEX TERMS: Dog, disease periodontal, scaling.

037. Lobprise H.B. 2007. **Periodontal management - periodontal prevention and treatment options: systemic implications**. *Pesquisa Veterinária Brasileira 27 (Supl.).* Senior veterinary specialist, veterinary specialty team Pfizer Animal Health. E-mail: Heidi.Lobprise@pfizer.com

Introduction: This lecture investigates the dynamics of periodontal disease and the impact this chronic infection can have on systemic health. Research now focuses on inflammatory markers and their significance in disease prevalence and treatment response. Aspects of prevention, from home care to early intervention to innovative preventative means, will be discussed.

Literature Review: Periodontal Medicine is described as

a discipline that focuses on validating the association between oral infection and systemic disease and its biological plausibility in human populations and animal model (Offenbacher 1996). Impact of Periodontal Disease (PD) on Systemic Health (Human data); mouth as the focus of infection (Miller 1891); rebuttal: patients not relieved of symptoms (JAMA Editorial 1952). Bacterial Link: Inflammatory Bowel disease and periodontal microorganisms (VanDyke et al. 1986); relationship between PD and cardiovascular disease (Matilla 1989); identification of periodontal pathogens in atheromatous plaques (Zambon et al. 1997). ARIC Study - Atherosclerosis Risk in Communities - periodontal disease associated with: coronary artery calcification (Nakib et al. 2004), renal insufficiency (Kshiragar et al. 2005), stroke/ TIA (Elter et al. 2003), carotid Artery Intima-Media Wall Thickness (Beck et al. 2001). Inflammatory Link: IgG antibody of oral organisms association to carotid intima-media thickness (ARIC - Beck et al. 2005), PD measures and association with clinical markers (Beck & Offenbacher 2002), PD relationship with C-Reactive Protein (Slade et al. 2003), risk factors for cardiovascular disease in patients with periodontitis (Buhlin et al. 2003), PD and biomarkers related to cardiovascular disease (Joshipura et al. 2003), C-Reactive Protein used as indicator of risk for diabetes, heart diseases, etc. Response to Therapy - significant decrease in C-RP in treated periodontitis patients at 6 months (D'Aiuto et al. 2003), Theories (Xiaojing et al. 2000), direct bacterial infection - 'metastatic infection', bacterial toxins- 'metastatic injury', immunocomplexes - antigen - 'metastatic inflammation'. Complicated factors of other diseases, risk factors, veterinary data, association of PD and histological lesions in multiple organs (DeBowes et al. 1996), systemic effects of chronically infected wound in oral cavity of dogs (Pavlica & Petelin 2005), echocardiographic alterations and PD in dogs: a clinical study (Boutoille et al. 2006), mitral value endocarditis after dental prophylaxis in a dog. (Tou et al. 2005), tracking systemic parameters pre- and post-treatment for PD (Rawlinson et al. - publication pending).

Discussion: Periodontal Management: Future studies may continue to look at the association of inflammatory markers, in particular with response to therapy. Dealing with the inflammation, as well as the infection, may help stabilize periodontal conditions by reducing the rate of alveolar bone resorption and discomfort associated with the disease (Tschappe & Kielbassa 2006). As with any disease, the best management is one of prevention whenever possible, instead of treating it once it has happened. Development of the Porphyromonas Denticanis-Gulae-Salivosa Bacterin: Periodontitis is a bacterial infection of the oral cavity primarily caused by Gram-negative black-pigmented anaerobic bacteria (BPAB) (Boyce et al. 1995). Twenty-four of these BPAB that cause periodontal disease are collectively known as periodontopathogens. In a recent study, the most commonly isolated BPAB in dogs with periodontitis were *Porphyromonas gulae*, *Porphyromonas salivosa* and *Porphyromonas denticanis* (Hardham et al. 2005 - Vet Microbiology). Once the microbiological study was completed and a Porphyromonas Vaccine was developed, studies were performed to establish that the *Porphyromonas gulae* used in the Porphyromonas Vaccine was pathologic (Hardham et al. 2005, Vet Microbiology). Then a study was conducted to determine if a *P. gulae* vaccine would prevent the pathologic changes demonstrated (Hardham et al. 2005, Vaccine). Mice vaccinated with the *P. gulae* strain B43 bacterin demonstrated a 83.9% reduction in alveolar bone lysis when compared to the control mice following a homologous *P. gulae* challenge. In addition, vaccinated mice showed a 40.7% and 64.6% reduction in alveolar bone lysis following challenge with a heterologous *P. gulae* strain or *P. salivosa*, respectively, when compared to the saline vaccinated and challenged mice. A dog model was then developed by Pfizer investigators to determine if the Porphyromonas Vaccine's protective effects would be seen in canines. This study provided data which were used to meet the USDA's reasonable expectation of efficacy requirement for conditional licensure of the Porphyromonas Vaccine (Pfizer Inc., Data on file 3860R-03-198). The canine apical periodontitis challenge model induces alveolar bone changes (osteolysis / osteosclerosis). The canine apical periodontitis challenge model is an acute model that may not reflect the chronic nature of canine periodontitis. The study demonstrated that the trivalent Porphyromonas Vaccine containing *P. gulae* (strain B43), *P. salivosa* (strain B104) and *P. denticanis* (strain B106) significantly reduced bone changes (osteolysis / osteosclerosis) following challenge with heterologous *Porphyromonas gulae* strain B69 when the challenge strain was administered at a high concentration (approx. 1x109 organisms/mL). In addition to a laboratory safety study, a clinical field study demonstrated the safety of the Porphyromonas Vaccine when administered in client-owned animals as young as 7 weeks old under field conditions (Pfizer Inc., Data on File, study 3467R-60-040218). Immediate post-vaccination pain was characterized as vocalization, scratching or biting at the injection site, aggression/attempt to escape from restraint or an abnormal attitude (5.9%). Sixty-two adverse events (4.6%) considered by the investigators to be related to vaccination were reported over the course of the trial. The types of events reported included generalized pain, injection site swelling, lethargy, and pain at the injection site. No significant adverse events were observed in any animal during the study period. Most of these reported events were mild and self-limiting, requiring no treatment. The USDA has granted a conditional license to Pfizer Animal Health for a new product to be used as an aid in the prevention of periodontitis in dogs, as evidenced by a reduction in bone changes (osteolysis/ osteosclerosis). This product is a Porphyromonas Denticanis-Gulae-Salivosa Bacterin, which can be administered to healthy dogs with two initial doses 3 weeks apart. A field safety study was conducted in over 600 dogs of multiple sizes and breeds, and safety was demonstrated in dogs as young as 7 weeks of age when vaccinated according to the label directions. A reasonable expectation of efficacy has been demonstrated in 8-month-old dogs. Duration of immunity for this product has not been evaluated; 6 and 12-month revaccination intervals are currently under evaluation in a field efficacy study. Consultation with a veterinarian is recommended. Additional efficacy and potency studies are in progress.

Conclusion: While there are studies and data that look to correlate the presence of periodontal disease with systemic disease, a definitive causal relationship has yet to be proven. Continued research to show this relationship, and the impact of therapy will provide additional data. With the general consensus that these are related, the options of preventing periodontitis should continue to be encouraged.

References: Beck et al. 2001. Relationship of Periodontal Disease to carotid artery intimal-media wall thickness: the ARIC study. Arch. Intern. Med. 163:172-179. - Beck & Offenbacher S. 2002. Relationship among clinical measures of periodontal disease and their associations with systemic markers. Ann. Periodontol. 7(1)79-89. - Beck et al. 2005. Associations between IgG antibody to oral organisms and carotid intimal-media thickness in ARIC. Atherosclerosis 10 (Epub) - Boutoille F. et al. 2006. Echocardiographic alterations and periodontal disease in dogs: a clinical study. Proc. 15th ECVD, Cambridge, p.63-65. - Boyce E.N., Ching R.J., Logan E.I. et al. 1995. Occurrence of Gram-negative black-pigmented anaerobes in subgingival plaque during the development of canine periodontal disease. Clin. Infect. Dis. 20 (Suppl.) 2:S317-319. - Buhlin et al. 2003. Risk factors for cardiovascular disease in patients with periodontitis. Eur. Heart J. 24:2099. - D'Aiuto et al. 2003. Periodontitis and systemic inflammation: Control of the local infection is associated with a reduction in serum inflammation markers. J. Dent. Res. 83:156. - DeBowes L.J. et al. 1996. Association of periodontal disease and histological lesions in multiple organs from 45 dogs. J. Vet. Dent. 13(2):57-62. - Elter et al. 2003. Relationship of periodontal disease and edentulism to stroke/TIA. J. Dent. Res. 82(12):998-1001. - Hardham J., Dreier K., Wong J. et al. 2005. Pigmented-anaerobic bacteria associated with canine periodontits. Vet Microbiol. 106:119-128. - Hardham J., Maryke R., Wong J. et al. 2005. Evaluation of a monovalent companion animal periodontal disease vaccine in an experimental mouse periodontitis model. Vaccine 23:3148-3156. - JAMA Editorial 1952. J. Am. Med. Assoc. 150:490. - Joshipura et al. 2003. Periodontal disease and biomarkers related to cardiovascular disease. J. Dent. Res. 83:151. - Kshiragar A.V. et al. 2005. Periodontal disease is associated with renal insufficiency in the ARIC study. Am. J. Kidney Dis. 45(4):650-657. - Mattila K. 1989. Association between dental health and acute myocardial infarction. Brit. Med. J. 298:779-782. - Miller W.D. 1891. The human mouth as a focus of infection. Dental Cosmos 22:689-713. - Nakib et al. 2004. Periodontitis and coronary artery calcification: the ARIC study. J. Periodontol. 75(4):505-510. - Offenbacher S. 1996. Periodontal Disease: Pathogenicity. Ann Periodontol. 1:821-878. - Pavlica Z. & Petelin M. 2005. Systemic effects of chronically infected wound in oral cavity of dogs. Proc. 14th ECVD, Ljubljana. - Pfizer Inc., Data on File, study 3860R-03-198. - Pfizer Inc., Data on File, study 3467R-60-04-218. - Slade G.D. et al. 2003. Relationship between periodontal disease and C-reactive protein among adults in the ARIC study. Arch. Intern. Med. 26;163(10):1172-1179. - Tou S.T. et al. 2005. Mitral valve endocarditis after dental prophylaxis in a dog. J. Vet. Intern. Med. 19:269-270. - Tschappe P. & Kielbassa A.M. 2006. The role of COX-2 in dentistry: past to future. Schweiz. Monatschr. Zahnmed. 116(9):880-886. - VanDyke T.E. et al. 1986. Infect. Immun. 53(3):671-677. - Xiaojing L.I. et al. 2000. Systemic diseases caused by oral infection. Clin. Microbiol. Rev. :547-558. - Zambon J.J. et al. 1997. Identification of periodontal pathogens in atheromatous plaques. J. Dent. Res.76:3159.

INDEX TERMS: Periodontal disease, systemic health, inflammatory markers.

038. Lobprise H.B. 2007. **Systemic impact of periodontal therapy - do no harm!** *Pesquisa Veterinária Brasileira 27(Supl.).* Senior veterinary specialist, veterinary specialty team Pfizer Animal Health. E-mail: Heidi.Lobprise@pfizer.com

Introduction: While ongoing studies strive to tie the impact of periodontal disease to systemic health, there must also be a strong effort to assure that our means of therapy cause no further damage to the patient as a whole. The entire peri-operative effort should be directed at resolving the patients' oral and dental problems and infections while implementing a complete body focus on pain management, patient monitoring and avoiding problems, or handling them adequately should they occur.

Literature Review: Appropriate literature references are used throughout the notes and catalogued at the end of the paper

Discussion: A comprehensive patient focus will be discussed, from pre-operative evaluation to peri-operative management and recovery. *Pre-operative Patient Evaluation:* A thorough evaluation prior to the day of the procedure allows for complete physical examination, taking a complete history and assessing any individual considerations such as breed-related concerns (brachycephalic, sight hounds, etc.). Routine examination on apparently health patients may miss subtle warning signs, so be thorough. There is a higher death rate in "routine procedures" than in emergency procedures, possibly due to the decreased intensity of evaluations in those 'routine' patients that might miss an underlying problem, as compared to the detailed evaluation an emergency patient might get (Matthews 2001). The initial dental examination may alert you to specific problems. Be sure to let the owner know that 'hidden' issues may be found once the patient is under anesthesia, and this may change the anticipated anesthetic time, or open up the consideration for a staged procedure. Laboratory screening protocols are set in each hospital and should be recommended based on the relative anesthetic risk of the patient. While the patient history and physical examination may be of great importance in human anesthesia (Ross & Tinker 1990), often the details we can obtain about our patients may be limited (Smith 1997). - *Pre-operative Patient Management and Triage:* Two important considerations in the pre-operative phase, based on the physical examination (repeated) and laboratory screening, include evaluating the patient for antimicrobial therapy and pain management considerations. Be sure to review any individual concerns (or breed concerns) and review all medication the patient is being given (Muir 2000). This pre-operative time can cause undue stress to the animal and in aggressive or anxious patients; this may not allow the practitioner to perform a complete physical examination, which may limit complete assessment. In addition, the stress can affect the anesthetic needs and immune function of the patient. Anxiety produced by not sedating a patient and using gas inhalants for induction only may be detrimental. A complete pain management protocol, including appropriate sedation, will not only reduce the stress on the patient (and you!), but most importantly can allow you to use the minimum amount of general anesthesia during the

procedure. Give appropriate medications (multi-modal when possible) for the best synergistic effects prior to starting the procedure. Local and regional blocks intra-operatively, when performed by trained personnel, can help reduce intra-operative pain and even post-operative, stress-induced immunosuppression (Koun-Boun et al. 2005). - *Patient Classification* (Smith 1997): I.) Excellent: Apparently healthy: no obvious signs of disease, elective procedures - OHE, neuter, screening radiographs; II.) Good: Mild systemic disease: pregnancy, obesity, dental disease, compensated cardiac disease, localized infection, neonatal (<8 weeks); geriatric (>10 yrs), procedures: skin tumor, uncomplicated ocular surgery; simple fracture repair or hernia; III.) Fair: Moderate systemic disease - activity limited: low or moderate fever; moderate dehydration or hypovolemia; anorexia, cachexia, anemia; chronic heart disease, procedures: complicated fracture, C-section, diaphragmatic hernia; IV.) Poor: Severe systemic disease, constant threat to life, shock, high fever, uremia, toxemia; severe dehydration or hypovolemia; severe anemia, emaciation; decompensated cardiac or renal failure; severe pulmonary disease, diabetes; V.) Guarded: Moribund patient not expected to survive 24 hours: advanced multiple system failure; profound shock; severe head injury, major trauma, DIC. - *Induction:* Many protocols are available for anesthetic induction, depending on the patient status, pre-medication used and the extent of the procedure. Once induced, intubation should include proper selection, placement and securing the tube. Take care with older tubes and cat intubation to avoid tracheal rupture (Hardie et al. 1999, Mitchell et al. 2000). - *Patient Care and Maintenance:* Maintain perfusion, IV catheter and fluids, 5-10ml/kg/hr or bolus, additional as needed (Seeler 1996), maintain body temperature, wet procedures, long, less than 99°F (37°C) (Armstrong et al. 2005); small, pediatric, geriatric (Koun-Boun et al. 2005), hypothermia may alter mentation, immunity, cardiac function and wound healing (Moon 1996), passive and active surface re-warming, active core rewarming. - *Patient Monitoring:* The best monitoring tool in a practice is a good technician! General assessment of CNS function to check muscle tone of the jaw and the palpebral reflex give an initial reference, but should be supplemented with monitoring devices (Benarski 2001). Remember, anesthesia depresses many systems, not just during the procedure. This may extend into the post-operative period, where most unexpected deaths occur (Ko 2001). The respiratory system can be impacted significantly during anesthetic events, and hypoventilation is one of the most common complications during anesthesia (Evans 1996), including death during recovery. The respiratory rate should be similar to that during sleep, from 6 bpm in a large dog to 10-15 bpm in a small dog or cat. The ease of using a pulse oximeter, to maintain saturation above 97% optimally (92% minimum), can be offset by complications in attaining an accurate reading (Haskins 1996). Capnography (EtCO2, to measure end tidal CO_2 at 35-55mg Hg) is more expensive and labor intensive, but gives a truer indication of ventilation. Primary treatment of hypoventilation is reduction of general anesthetic, but positioning, and maintaining an unobstructed airway are essential. Some patients (geriatric, obese, ill) may require ventilation assistance. Hypotension and hypoperfusion are also common anesthetic complications, as anesthetic levels can decrease cardiac contractility and cause vasodilation that can impact the circulating volume which may already be compromised due to hydration, age and disease. While assessment of membrane color, pulse strength and capillary refill time will provide an initial level of evaluation, the gold standard is monitoring the blood pressure. Unrecognized hypotension with a reduction in peripheral perfusion may lead to hypoxic damage to organs, including the kidneys and heart. While the indirect Doppler units may require some practice, they are fairly easy to use and produce an audible indicator of blood flow. If hypotension is encountered, again, decreasing the anesthetic depth is the first step of treatment. From there, increasing fluid flow for preload and cardiac output is essential. Additional supplementation with a colloidal material may be necessary. Keep the patient and fluids warm. The use of positive inotropes may be necessary to improve contractility and heart rate (Evans 1996). Electrocardiography can be an important tool to monitor the electrical activity of the heart, but should be used in conjunction with other monitoring, as the true mechanical activity of the heart is not assessed with the ECG. The most common arrhythmias encountered during anesthesia include bradycardia (<40-50 bpm for large dogs, <80-100 bpm for cats and toy dogs), tachycardia (>140 bpm for large dogs, >240 bpm for cats) and ventricular arrhythmias. Anticholinergics may be used to treat the bradycardia (Evans 1996), keep the patient warm, oxygenated and evaluate electrolytes. If the patient experiences tachycardia, first assess the anesthetic depth, which may be too light (painful) or too deep, as well as checking for hypoxia or use of anticholinergics, and adjust accordingly. *Recovery:* Often the patient leaves the operative time period and gets minimal attention, especially once the endotracheal tube is removed. In fact, this is the time when complications can occur unnoticed, so patient management is very important (Ko 2001). Continue with appropriate hydration, temperature monitoring and particularly ventilation, especially in brachycephalic patients. With debris or fluids in the oral cavity, elongated soft palates and potential swelling of the pharyngeal or tracheal tissues, the endotracheal tube should be maintained as long as possible, and the patient should be monitored closely once it is removed. Patients with a history of tracheal problems may benefit from the anti-tussive effect of certain opioids, as well as their sedative and analgesic properties. The period of emergent delirium may cause the patient to injury itself and can increase stress, so close attention to pain management during this time period is crucial. Provide additional analgesia, such as an opioid to smooth this recovery period, and consider an 'escape' dose of an alpha 2 agonist, such as medetomidine (1-2 micrograms/kg) to reduce the delirium.

Conclusion: With appropriate patient assessment, management and monitoring, treatment of oral and dental

disease can have the most positive impact on our patients, while minimizing the complications.

References: Armstrong S.R., Roberts B.K. & Aronsohn M. 2005. Perioperative Hypothermia. J. Vet. Emerg. Crit. Care 15(1):32-37. - Bednarski R.M. 2001. Patient monitoring essential for safe anesthesia. DVM, p.22-27. - Evans A.T. 1996. Anesthetic emergencies and accidents, p.841-860. In: Thurman J.C. & Tranquilli W.J., et al. (ed.), Veterinary Anesthesia. 3rd ed. William and Wilkins, Baltimore. - Hardie E.M., Spodnick G.J. et al. 1999. Tracheal rupture in cats: 16 cases (1983-1998). J. Am. Vet. Med. Assoc. 15;214(4):508-512. - Haskins S.C. 1996. Monitoring the anesthetized patient, p.409-424. In: Thurman J.C., Tranquilli W.J. et al. (ed.), Veterinary Anesthesia. 3rd ed. William and Wilkins, Baltimore. - Ko J. 2001. Patient management during recovery - most important part of anesthesia. DVM, p.25-32. - Koun-Boun J., Silim A. et al. 2005. Immunological aspects of veterinary anesthesia and analgesia. J. Am. Vet. Med. Assoc. 15;226(3):355-363. - Matthews N. 2001. Comprehensive pre-operative evaluation could eliminate potentially lethal mistakes. DVM, p.8-11. - Mitchell S.E., McCarthy R. et al. 2000. Tracheal rupture associated with intubation in cats: 20 cases (1996-1998). J. Am. Vet. Med. Assoc. 15;216(10):1592-1595. - Moon P.F. 1996. Anesthesia for Healthy Pediatric and Geriatric Patients. Perspectives. - Muir W.W., Hubbel J.A.E. et al. 2000. Handbook of Veterinary Anesthesia. 3rd ed. Mosby, St Louis, p.275-283. - Ross A.R. & Tinker J.H. 1990. Anesthesia Risk. Anesthesia. 3rd ed. Miller R.D. (ed), Churchill Livingstone, NY, p.15-742. - Seeler D.C. 1996. Fluid and Electrolyte Therapy, p.572-589. In: Thurman J.C., Tranquilli W.J. et al (ed.), Veterinary Anesthesia. 3rd ed. William and Wilkins, Baltimore. - Smith J.A. 1997. Preanesthetic evaluation and risk assessment of small animal patients. Suppl. Vet. Med. Vet. CE Advisor.

INDEX TERMS: Periodontal, therapy, systemic, health.

039. Lopes F.M. 2007. **Orthodontic treatment in a Labrador retriever dog with mandibular brachygnathism and base narrow canine teeth.** *Pesquisa Veterinária Brasileira 27(Supl.).*

Mestranda do Departamento de Cirurgia, FMVZ-USP, São Paulo, SP 05508-270. E-mail: lopesfm@usp.br

Introduction: Malocclusion is a common dental problem in domestic dogs. Etiology includes dentofacial deformities, heredity, systemic and local factors, such as trauma and chewing habits. Several treatment options are available for occlusion correction, as teeth extraction, crown-height reduction, and orthodontics. This category of treatment includes several techniques, two of them are presented in this report.

Case Report: A 5-month-old, female, Labrador Retriever dog was presented to the Comparative Dentistry Laboratory of the Veterinary Hospital of São Paulo University with malocclusion. The owner reported oral bleeding after biting or chewing. Oral examination revealed mandibular brachygnathism (Angle's class 2 occlusion), base narrow canine teeth (degree 4) and retained primary tooth (604). Under general anesthesia, it was performed retained tooth extraction, dental alginate impression and gypsum model and a direct acrylic inclined plane was applied between maxillary canines and second premolars. The patient returned 6 weeks later for appliance removal, since the lower canine teeth movement was acquired and no homecare complications were reported by the owner during postoperative period. After 3 months the owner reported lingually displacement of the canine teeth. Dental impression and models were performed and a second direct acrylic inclined plane was applied over maxillary incisors until first premolars in the anesthetized patient. During postoperative examination after 2 and 6 weeks the owner reported oral bleeding, halitosis and prostration. The appliance was removed 2 months later, revealing extensive palatitis, with bleeding and palatal necrosis. At the same procedure, a "W" wire was positioned on the mandibular canine teeth in order to prevent lingually displacement of both teeth. The appliance was bonded with light-cure resin and acrylic. Postoperative examination after 2 weeks, 3 and 6 months revealed palititis regression, absence of halitosis, no dislodgment or breakage of appliance and vestibular movement of mandibular canine teeth. At the 6-month recheck examination the appliance was removed and prophylaxis performed. Both canine teeth remained in the new position after 4 months since appliance removal.

Discussion and Conclusions: Orthodontic treatment is the best option of malocclusion treatment, if possible, since teeth are preserved and complications risks are minimized if orthodontic fundaments are followed. Lingually displacement of mandibular canine teeth is a common malocclusion in dogs, sometimes related with pain and inability to close the mouth, since it may cause damage to oral tissues, as palate, resulting, in some cases, in oronasal communication. The direct acrylic inclined plane is, usually, the treatment of choice. The advantages of this technique include easy placement, low cost, rapid correction and it rarely needs adjustments after appliance. The disadvantages are its restriction to maxillary growth and gingival and palatal inflammation. At the reported case, the direct inclined plane was able to correct the malocclusion, but the mandibular canine teeth returned to the previous position and another intervention was necessary. Palatal inflammation presented by the patient was severe at the second time, and tissue necrosis occurred. A "W" wire was performed and applied on the mandibular canine teeth in order to maintain both teeth in position. This technique could be considered a good option, since the patient presented satisfactory adaptation, easy home care cleaning, and no breakage of the equipment. The final result was not a perfect occlusion, but a healthy and functional one. The combination of both orthodontic techniques presented a good option of treatment for correction and maintenance of the teeth at the correct position.

References: Hale F.A. 1996. Orthodontic correction of lingually displaced canine teeth in a young dog using light-cured acrylic resin. J. Vet. Dentistry 13(2):69-73. - Holmstrom S.E., Frost P. & Gammon R.L. 2004. Veterinary Dental Techniques. 3rd ed. W.B. Saunders, Philadelphia, PA. - Legendre L.F.J. 1994. Treatment of a malocclusion in a dog using both exodontic and orthodontic procedures. Can. Vet. J. 35:454-456. - Oakes A.B. & Beard G.B. 1992. Lingually displaced mandibular canine teeth: orthodontic treatment alternatives in the dog. J. Vet. Dentistry 9(1):20-25. - Ulbricht R.D. & Marretta S.M. 2005. Orthodontic treatment using a direct acrylic inclined plane. J. Vet. Dentistry 22(1):60-65. - Verhaert L. 1999. A removable orthodontic device for the treatment of lingually displaced mandibular canine teeth in young dogs. J. Vet. Dentistry 16(2):69-75. - Wiggs R.B. & Lobprise H.B. 1997. Basics of orthodontics, p.435-481. In: Wiggs R.B. & Lobprise H.B. (ed.), Veterinary Dentistry: principles and practice. Lippincott-Raven Publ., Philadelphia, PA.

INDEX TERMS: Veterinary dentistry, orthodontics, malocclusion, dogs.

040. Miranda R.A.[1] & Nakamura A.A.[2] 2007. **What a veterinarian that acts in Veterinary Dentistry needs to know about instruments and equipments to open a dental clinic.** *Pesquisa Veterinária Brasileria 27(Supl.).* [1]Veterinary Polyclinic São Francisco, Veterinary Dentistry, University of Guarulhos (UnG), São Paulo, Brazil; [2] Master's degree course at VPS, FMVZ, University of São Paulo (USP), São Paulo, Brazil. E-mail: r.a.miranda@estadao.com.br

Introduction: This paper has the intention to show details that most of the times the veterinarian specialized in Veterinary Dentistry or either the ones who got interest to have this service in their clinics or hospitals have to consider when they make a project for a surgical room ready for odontologic services (Gioso 1994). After knowing this subject, the professional will have conditions to make a project that contains many kinds of equipments, furniture, surgical materials and respective prices, researched in many stores of Brazilian's market. Here we won't consider expenses as values of property, monthly expenses (servants, accounts of light, water and telephone) or values of materials for basic consumption (as gauze, adhesive tape and anaesthetics).

Materials and Methods: We have four surgical centers are practicing veterinary dentistry, situated in Grande São Paulo, Brazil: 1) the USP Surgical Center, called LOC (Laboratory of Comparative Dentistry); 2) a surgical center at UnG (University of Guarulhos); 3) the Odontovet Surgical Center, that is the second clinic opened in the world only to take care of veterinary dentistry, and 4) the surgical center of the Veterinary Polyclinic São Francisco, where are realized dental surgeries and dental treatments of routine, and that also has all the necessary equipment and materials for practices of veterinary dentistry. In the folowing, we have opportunity to present two human odontologic centers: one of them is a center of excellence situated at Unesp-Bauru, that serves as reference for the human dentistry in Brazil, and the other is a dental centre that respects the standard of Brazilian human dentistry. The reason for the inclusion of these six centers in this presentation was just to compare the kind of work in each one, including all sorts of equipment used in both the human and veterinary dentistry.

Results: After a long lasting study with the intention to compare all the infrastructure, equipments and surgical materials, we can conclude that the veterinary dentistry is practiced at a great technical and scientific level which approaches very much to human dentistry (Venturini et al. 1998). We showed the most diverse equipments, since a simple however important millimetric probe (Roza 2004) until the future of veterinary dentistry, that will use magnetic resonance (reality in human dentistry) and lasers ray for many odontological procedures. After all of this, we can claim that the two principal points that differentiate human and veterinary dentistry are first the patients and second the place where they will be treated (Gioso 2003, Roza 2004).

Discussion and Conclusions: Today, most of Brazilian dental veterinarians present excellent scientific and technical level they acquired mainly by specialization courses (500 hours lesson) developed by Anclivepa (National Association of Small Animal Veterinary Clinics) and through complementary courses, developed by ABOV (Brazilian Association of Veterinary Dentistry). With all this technical knowledge (Harvey & Emily 1993) we can establish a point of union and balance with human dentistry and look forward to find and use the best equipment and consumption material, so that we are able to develop veterinary dentistry with technology of the last generation.

References: Harvey C.E. & Emily P.P. 1993. Small Animal Dentistry. - Gioso, M.A. 1994. Odontologia Veterinária para o Clínico de Pequenos Animais. São Paulo. - Gioso M.A. 2003. Odontologia para o Clínico de Pequenos Animais. Doença Periodontal. São Paulo, p.25-47. - Mitchell P.Q. 2005. Odontologia de Pequenos Animais. Instrumentos especializados e materiais para cirurgia oral. São Paulo, p.127-154. - Roza M.R. 2004. Odontologia em Pequenos Animais. Montando sua unidade de atendimento odontológico. Rio de Janeiro, p.68-74. - Small Animal Dental Equipments and Materials. 1993. Mosby, St Louis, p.378-400. - Venturini M.A.F.A., Corrêa, H.L. & Gioso M.A. 1998. Registro de exame clínico odontológico. Odontograma. Clín. Vet. 13:23-28.

INDEX TERMS: Dental equipments, prices, equipments, Surgical Centers.

041. Nemec A., Pavlica Z., Crossley D.A., Zdovc I., Petelin M., Nemec M. & Šentjurc M. 2007. **Systemic response to aspiration of gram negative pathogens and treatment with nitric oxide synthase inhibitors.** *Pesquisa Veterinária Brasileira 27(Supl.).* Veterinary Faculty Small Animal Clinic, University of Ljubljana, Gerbièeva 60, 1115 Ljubljana, Slovenia. E-mail: ana.nemec@vf.uni-lj.si

Introduction: Nitric oxid NO• is considered an important intra- and inter-cellular messenger molecule and small amounts of nitric oxide (NO•) are found in tissues due to constitutive NO• production (Thippeswamy et al. 2006). Larger (toxic) amounts are produced locally and systemically by inducible nitric oxide synthase (iNOS) after exposure to bacterial lipopolysaccharides (LPS) (Berliner & Fujii 2004). Excess NO• production is detrimental, leading to oxidative tissue damage (Miller & Britigan 1997). The local pathogenesis of periodontal disease involves excessive NO• production (Ugar-Cankal & Ozmeric 2006). The systemic effects of periodontitis may also be related to NO• production, but systemic NO• production after oral exposure to gram negative pathogens has not so far been reported.

Materials and Methods: The organ levels of NO• in normal mice were compared with levels found in mice inoculated perorally with 10^8 CFU *E. coli* ATCC 25922 or *P. gingivalis* ATCC 33277, with or without concurrent use of iNOS-specific (1400W) or non-specific (L-NAME) NOS inhibitors. Electron paramagnetic resonance (EPR) detection of NO• was performed using a diethyldithiocarbamate (DETC), Fe-sulfate and Na-citrate 'spin-trap'. (Berliner & Fujii 2004).

Specific pathogen free balb/c mice 3 to 4 months old were randomly divided into eight groups: I) untreated, II) spin trap, III) sterile broth inoculation + spin-trap, IV) *E.coli* inoculated, V) *E.coli* + spin trap, VI) *E.coli* + L-NAME + spin-trap, VII) *E.coli* + 1400W + spin-trap, VIII) *P.gingivalis* + spin trap. Additionally, the effects of NOS inhibitors alone or with administration of spin trap were tested in ten mice. Mice were euthanised at intervals - 2.5, 7, 13, 25 hours after infection, (spin trap being administered one hour before sacrifice in the relevant groups) and the internal organs immediately harvested and frozen in liquid nitrogen. The EPR spectra of the organs were measured on an X-band EPR spectrometer (Bruker ESP 300) at 130°K and searched for the EPR spectrum of $FeNO(DETC)_2$ which is formed when NO• reacts with the spin trap (Vanin et al. 2002). The signal intensity is proportional to the amount of NO• present in the tissue (Venkataraman et al. 2002, Kleschyov et al. 2003). The intensity of the signals was normalized to the mass of each sample and recorded as adjusted units (AU) to enable statistical comparison between the measurements (nonparametric Wilcoxon's rank sum two-sided two-samples test).

Results: A typical $FeNO(DETC)_2$ signal was detected in all organs and in all the mice infected with *E.coli* and levels were at a maximum 25 hours after infection. (Fig.1)

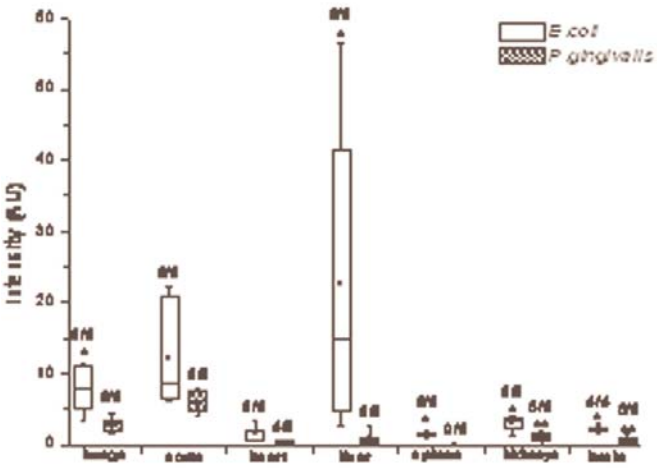

Fig.1. NO• response as detected by EPR in different organs of mice 25 hours after infection with *E.coli* (group V) or *P.gingivalis* (groupVIII). * indicates statistically significant difference between native and with *E.coli* infected mice (between basal and stimulated NO• level, respectively). ** indicates marginally statistically significant difference (p=0.059) between native and with *P.gingivalis* infected mice. In the box plots, median and the 25th to 75th percentile are indicated by the boxes, and minimum and maximum are given by the error bars. Filled squares show mean value of the normalised EPR spectra intensity. The number of animals where NO• response was detected is indicated above each box.

A response was already present at 2.5 hours, but the level varied between animals and organs. At intermediate times between 2.5 and 25 hours the signal decreased before increasing again. The organ with the highest post infection signal was the liver, followed by thoracic aorta and lungs. The intensity of the signal was statistically significantly higher at 2.5 hours after infection in liver and at 25 hours in liver, lungs, spleen, kidneys and brain in *E.coli* infected mice compared to non-infected mice. In *P.gingivalis* treated mice there was a consistently detectable NO• response in lungs and liver while in other organs the response varied over time. The highest response was in thoracic aorta followed by lungs, both at 13 hours after infection. The maximal signal intensity for liver, kidneys and brain was nearly the same, but at different times, 7 hours, 2.5 hours and 13 hours respectively. Apart from the aorta, the maximal intensity of the signal was lower than that observed with *E.coli* innoculation. L-NAME and 1400W used in *E.coli* infected mice inhibited $FeNO(DETC)_2$ signal at 2.5 hours proving that at least some of the NO• radicals detected after infection arises from iNOS. However, at 7 hours a more intense $FeNO(DETC)_2$ signal was observed in the mice treated with 1400W, than in animals not receiving NOS inhibitors.

Discussion and Conclusions: In septic shock studies the likelihood of organs showing a NO• response to *E.coli* infection varies (Suzuki et al. 1998, Dambrova et al. 2003, Kozlov et al. 2003, Plonka et al. 2003, Hayashi et al. 2005). *P.gingivalis* LPS is reported not to stimulate isolated murine splenic cells to produce NO• (Sosroseno 2000), but it induces production of NO• in macrophages, central nervous system glial cells and cultured gingival fibroblasts (Frolov et al. 1998, Kendall et al. 2000, Shapira et al. 2002, Kim et al. 2006). Our study, however, has shown that a single peroral infection of mice with either *E. coli* or *P. gingivalis* stimulates the whole organism to produce NO•, though the principally involved organs were different in *E.coli* and *P.gingivalis* infected mice. The intensity of stimulation was much lower with *P.gingivalis* infection. This fits with the findings of Reife et al. (1995) who showed that *P.gingivalis* has a less biologically reactive LPS compared with *E.coli*. Reduced production of bactericidal NO• as detected after *P.gingivalis* infection, compared to *E.coli* infection, suggests that *P.gingivalis* can avoid innate host defense mechanisms. Moreover, it appears that LPS from *E.coli* and *P.gingivalis* activate different types of adaptive immunity in vivo (Pulendran et al. 2001). Therefore infection with *P.gingivalis* may result in greater colonization and more chronic disease than occurs with *E.coli* infection. As NO• from iNOS is reported to be an important element of the host defense against *P. gingivalis* (Alayan et al. 2006) its inhibition is not always appropriate, so the proposed therapeutic use of iNOS inhibitors may not be appropriate. What is more, NOS inhibitors are known to have side effects (Pechanova et al. 1999, Inada et al. 2002). In our study, after an initial short period of inhibition, the use of inhibitors resulted in greater NO• production associated with *E.coli* infection: this effect may be responsible for worsening the symptoms seen in some studies. The response of the organism to the treatment with NOS inhibitors in *P. gingivalis* infection remains to be elucidated.

Acknowledgements: The study was supported by grants of Slovenian Research Agency -Young Researchers' grant and a part of the grant No.P4-0053.

References: Alayan J., Ivanovski S., Gemmell E., Ford P., Hamlet S. & Farah C.S. 2006. Deficiency of iNOS contributes to Porphyromonas gingivalis-induced tissue damage. Oral Microbiol Immunol 21(6):360-365. - Berliner L.J. & Fujii H. 2004. In vivo spin trapping of nitric oxide. Antioxid Redox Signal 6(3):649-656. - Dambrova M., Kirjanova O., Baumane L., Liepinsh E., Zvejniece L., Muceniece R., Kalvinsh I. & Wikberg J.E. 2003. EPR investigation of in vivo inhibitory effect of guanidine compounds on nitric oxide production in rat tissues. J. Physiol. Pharmacol. 54(3):339-347. - Frolov I., Houri-Hadad Y., Soskolne

A. & Shapira L. 1998. In vivo exposure to Porphyromonas gingivalis up-regulates nitric oxide but suppresses tumour necrosis factor-alpha production by cultured macrophages. Immunology 93 (3):323-328. - Hayashi Y., Abe M., Murai A., Shimizu N., Okamoto I., Katsuragi T. & Tanaka K. 2005. Comparison of effects of nitric oxide synthase (NOS) inhibitors on plasma nitrite/nitrate levels and tissue NOS activity in septic organs. Microbiol Immunol 49(2):139-147. - Inada H., Ono H., Minami J., Ishimitsu T. & Matsuoka H. 2002. Nipradilol prevents L-NAME-exacerbated nephrosclerosis with decreasing of caspase-3 expression in SHR. Hypertens Res 25(3):433-440. - Kendall H.K., Haase H.R., Li H., Xiao Y. & Bartold P.M. 2000. Nitric oxide synthase type-II is synthesized by human gingival tissue and cultured human gingival fibroblasts. J. Periodontal Res. 35 (4):194-200. - Kim S. J., Choi E.Y., Cho Y.J., Lee J.Y., Choi J.I. & Choi I.S. 2006. Surface-associated material from Porphyromonas gingivalis stimulates the release of nitric oxide by inducing expression of inducible nitric oxide synthase. Microbes Infect 8 (2):470-477. - Kleschyov A.L., Oelze M., Daiber A., Huang Y., Mollnau H., Schulz E., Sydow K., Fichtlscherer B., Mulsch A. & Munzel T. 2003. Does nitric oxide mediate the vasodilator activity of nitroglycerin? Circ Res 93 (9):104-112. - Kozlov A.V., Szalay L., Umar F., Fink B., Kropik K., Nohl H., Redl H. & Bahrami S. 2003. Epr analysis reveals three tissues responding to endotoxin by increased formation of reactive oxygen and nitrogen species. Free Radic Biol Med 34 (12):1555-1562. - Miller R.A. & Britigan B.E. 1997. Role of oxidants in microbial pathophysiology. Clin Microbiol Rev 10 (1):1-18. - Pechanova O., Bernatova I. & Babal P. 1999. Structural alterations in the heart after long-term L-NAME and D-NAME treatment. Gen Physiol Biophys 18(Suppl.1):6-9. - Plonka P. M., Chlopicki S., Wisniewska M. & Plonka B. K. 2003. Kinetics of increased generation of (.)NO in endotoxaemic rats as measured by EPR. Acta Biochim Pol 50(3):807-813. - Pulendran B., Kumar P., Cutler C. W., Mohamadzadeh M., Van Dyke T. & Banchereau J. 2001. Lipopolysaccharides from distinct pathogens induce different classes of immune responses in vivo. J Immunol 167(9):5067-5076. - Reife R.A., Shapiro R. A., Bamber B.A., Berry K.K., Mick G.E. & Darveau R.P. 1995. Porphyromonas gingivalis lipopolysaccharide is poorly recognized by molecular components of innate host defense in a mouse model of early inflammation. Infect Immun 63(12):4686-4694. - Shapira L., Ayalon S. & Brenner T. 2002. Effects of Porphyromonas gingivalis on the central nervous system: activation of glial cells and exacerbation of experimental autoimmune encephalomyelitis. J Periodontol 73(5):511-516. - Sosroseno W. 2000. Nitric oxide production by murine spleen cells stimulated with Porphyromonas gingivalis-derived lipopolysaccharide. Asian Pac J Allergy Immunol 18(4):209-214. - Suzuki Y., Fujii S., Numagami Y., Tominaga T., Yoshimoto T. & Yoshimura T. 1998. In vivo nitric oxide detection in the septic rat brain by electron paramagnetic resonance. Free Radic Res 28(3):293-299. - Thippeswamy T., McKay J. S., Quinn J. P. & Morris R. 2006. Nitric oxide, a biological double-faced janus—is this good or bad? Histol Histopathol 21(4):445-458. - Ugar-Cankal D. & Ozmeric N. 2006. A multifaceted molecule, nitric oxide in oral and periodontal diseases. Clin Chim Acta 366(1-2):90-100. - Vanin A. F., Huisman A. & van Faassen E. E. 2002. Iron dithiocarbamate as spin trap for nitric oxide detection: pitfalls and successes. Methods Enzymol 359:27-42. - Venkataraman S., Martin S.M. & Buettner G.R. 2002. Electron paramagnetic resonance for quantitation of nitric oxide in aqueous solutions. Methods Enzymol. 359:3-18.

INDEX TERMS: *Porphyromonas gingivalis*, *Escherichia coli*, nitric oxide, 1400W, L-NAME.

042. Niemiec B.A. 2007. **Full mouth dental impressions and stone model fabrication.** *Pesquisa Veterinária Brasileira 27(Supl.).* Southern California Veterinary Dental Specialties, San Diego, CA, United States. E-mail: Dogbeachdr@aol.com

Introduction: Whole mouth impressions are a very common occurrence in veterinary dentistry. Typical indications include orthodontic therapy and crown fabrication (Holmstrom, Frost & Eisner 1998). They are a straight forward procedure and can be accomplished by anyone. However, to get high quality models, all steps need to be performed quickly and adroitly.

Literature Review: A type I alginate[a] is generally selected for the full mouth impressions (Wiggs & Lobprise 1997). Impression trays should be selected from the practice assortment that most closely fit the patient's jaw. The selected trays should provide complete coverage of the arch with approximately ¼ inch clearance around all areas of the mouth with a minimum of dead space. It is best to trail fit the trays prior to mixing the alginate. The alginate is first aerated by gently tumbling the container. It is then measured out and mixed with room temperature water according to package directions. Spatulation should be accomplished with a figure-8 motion using a wide buffalo spatula against the walls of a rubber-mixing bowl. Complete spatulation will be evident when it becomes a smooth creamy mixture without voids, which was no longer grainy (Wiggs & Lobprise 1997). Since this is a fast set alginate, spatulation must be accomplished in 30 seconds. The mixed alginate should be placed immediately into the impression tray by starting at the posterior segment and pushing the mixture forward to the anterior portion and forcing it firmly into the tray to avoid trapping voids. Place the patient in dorsal recumbancy for the mandible and ventral recumbancy for the maxilla. The tray is then applied to the target arcade, and held in position for 1 minute following the loss of tackiness of the impression material, which indicats complete setting. The impression is then removed from the teeth in a rapid motion to decrease the chance of tearing the impression. This is done because alginate has a higher compression and tear strength with increased rates of deformation (Craig et al. 2000). The strength of alginate will increase as the removal is delayed, however this must be balanced with continued time under anesthesia. This procedure is then repeated for the opposite arcade. Bite registration: In order for the laboratory to accurately create the model and appliance, a bite registration is necessary to align the stone models. This step can either be accomplished with a commercially manufactured bite wax[b], or the putty from a 2-step crown impression materal[c]. The wax strip is immersed in warm water to soften according to package directions. The patient is extubated, and the bite impression taken by closing the mouth on the wax and holding for a few seconds until the wax had hardened. Then the mouth was carefully opened, the wax strip removed, and the patient re-intubated. The impressions and bite registration were carefully inspected for defects, and the patient recovered from anesthesia normally. If using the crown impression material, mix according to package directions and follow the steps above for wax. This will give a more accurate impression, however it will take much longer to set up. This is a concern due to the fact that the pet is extubated at this time. Let the veterinarian make the decision as to material used. *Preparing stone models:* The stone models should be poured as soon as the patient had recovered from anesthetic. This was done to decrease the distortion of the model due to the low dimensional stability of alginate. In addition, is accomplished quickly to avoid the alginate drying out, which

would have robbed the gypsum of some of its water and weakened the resulting stone model. The dental stone[d] is measured out on a gram scale and mixed with water according to package directions. The mixing bowl should be placed on a vibrator for 15 seconds to remove the large air bubbles. The impression trays are rinsed to remove debris and the excess water shaken out. This step is important as excess water in the impression "tips" will increase the water in that area of the impression and thus weaken the resulting stone model. The trays should be placed on the vibrator with the anterior portion angled down. Very small amounts of stone should be transferred to the model using a small cement spatula or paper clip and the vibrations used to flow the stone into the voids created by the teeth to avoid trapping air bubbles. After the teeth and surface area of the impression are filled, the remainder of the tray can be filled with a large cement spatula. The stone is completely set after the heat dissipates; this is generally in approximately 60 minutes. The models should be removed soon after this to avoid drying out of the alginate. Alginate, when dried, becomes more rigid, which would increase the likelihood of model fracture during removal from the impression. The stone models should be carefully removed from the alginate to avoid breakage. If you are dealing with a subject with very long and thin canines or if crown preps are done, the canines can be strengthened by placing orthodontic wire or a paper clip in the canine.

Discussion and Conclusions: Full mouth dental impressions are straightforward procedure, but since there are numerous steps, there are numerous chances for failure. Many people can make impressions, however to create truly excellent models, each step must be performed expertly. The first step is to obtain the proper equipment. This may be difficult due to the lack of availability of proper sizes for veterinary patients however, over time, customization can be performed. By working through the procedure quickly yet fastidiously, high quality models can be made on a regular basis.

[a]Key-To® Alginate Impression Material: Teledyne Water Pik, Fort Collins, CO 80553-0001.

[b]Kerr Set Up Wax®: Kerr Laboratory Products Division, Emeryville, CA 94608.

[c]Express®: 3-M Corporation.

[d]Tru-Stone®: Miles, Inc, Dental Products, 4315 South Lafayette Blvd. South Bend, Ind. 46614.

References: Holmstrom S.E., Frost P.P.& Eisner E. 1998. Orthodontics, p.404. In: Veterinary Dental Techniques. 2nd ed. W.B. Saunders, Philadelphia, PA. - Wiggs R.B. & Lobprise H.B. 1997. Basics of orthodontics, p.468-471. In: Veterinary Dentistry: principals and practice. Lippincott-Raven, Philadelphia, PA. - Craig, Powers & Wataha 2000. Dental Materials, Properties and Manipulation. 7th ed. Mosby, St Louis, p.153-202.

INDEX TERMS: Impressions, stone models, orthodontics.

043. Niemiec B.A. 2007. **Surgical endodontics**. *Pesquisa Veterinária Brasileira 27(Supl.).* Southern California Veterinary Dental. Specialties, San Diego, CA, 92111, United States. E-mail: Dogbeachdr@aol.com

Introduction: There are several indications for surgical root canal therapy (Wiggs & Lobprise 1997). 1) Failed standard root canal, but only if you feel that you cannot perform a better conventional RCT. Poor standard root canal therapy is no reason for a surgical root canal. 2) Procedural blockage from a pulp stone, file separation, or stenotic canal (try RC prep and watch-winding first!). 3) Incomplete apex in a young patient, however we prefer to attempt apexogenesis or apexification first. 4) Apical perforation or apical disease/resorbtion, however only if severe, as these can often do very well with standard root canal therapy.

Literature Review: There are several critical pieces of equipment that are required to perform this type of therapy (Holmstrom et al. 1998). These include: a dental x-ray unit, high speed air driven unit preferably with a pediatric (mini) hand piece, a sterile surgical pack (scalpel, periosteal elevator, needle holder, burs (701, 330, 1/4), and root end filling material (MTA, IRM, amalgam). Optionally, an ultrasonic root end preparation tool may facilitate the procedure. Pre-operative testing: A minimum database should be obtained consisting of a CBC and chemistry panel including thyroid level in older patients as well as a urinalysis. In addition, this author recommends that patients over 6 years of age have 3-view chest radiographs exposed. Finally, a coagulation profile and Crossmatch should be considered. Since this is a very invasive procedure, IV Fluid therapy, balanced anesthesia, and proper pain control (NSAIDS, Opioids, regional anesthetic) and antibiotic coverage, along with monitoring should be performed in all cases. *Surgical procedure:* approach: The incision should be placed utilizing your knowledge of dental anatomy and palpating the juga (if possible) to approximate the apex. Make a curved incision to expose the apex by a wide margin avoiding the attached gingiva. The incision should be made full thickness in one deft motion to enhance healing. Following the incision, the mucosa should be elevated full thickness to reveal the bone over the apex. If there is any question as to the location of the apex, the practitioner should consider placing a radiopaque marker over the apex and exposing a radiograph to ensure that the trephination is in the correct position. Using a dental bur, the bone is carefully removed to expose the apex. This should be done in a paint brush fashion. Once the apex is identified, it is further exposed for the surgical approach. Enough of the root must be exposed to reveal 6-8mm of the apex plus a little beyond. This bone removal must be done very carefully to avoid damaging the root or entering vital tissues (nose, mandibular canal). *Apicoectomy:* Once the apex is exposed; using a high speed bur (699 normally) resect the apex. It is important to remove a minimum of 4mm of apex in order to minimize the possibility of lateral or accessory canals. If you are performing the retrograde preparation with a bur, the apicoectomy should be done at a 45 degree angle to help visualization. If utilizing an ultrasonic retropreparation tool, this can also be performed at a 90 degree angle. In fact, the 90 degree angle provides superior seal to the traditional 45 degree angle when ultrasonic units are used to

prepare the cavity (Gagliani et al. 1998). The granuloma should be debrided with a curette and a sample submitted to the lab for histopathologic analysis Following this, the defect is rinsed and packed with cotton pellets to help catch scatter. *Apical preparation:* The apical portion of the root canal system is then prepared to a minimum depth of 3mm. However, the deeper the preparation, the better the retrofill and therefore prognosis. This is classically accomplished with a small round bur. However numerous recent studies currently support the use of an ultrasonic scaler. For the studies supporting the rationale and benefits of this method see the article in the AVDC advanced section of the 2005 AVDF proceedings. Retrograde filling: Following the retrograde preparation, a dental radiograph should be exposed to ensure complete removal of the obturation material to the minimum depth. In addition, the depth should be evaluated with a periodontal probe. Providing that the radiographic and physical evidence of proper preparation exists, the apical portion of the root canal is filled. Amalgam, IRM, and EBA have been used historically; however MTA is the current treatment of choice. If there is severe inflammation and seepage, MTA use may be a concern due to the moisture. The selected material is placed with a retrograde filling instrument and packed into the canal to fully and densely fill the canal. The canal should be completely to slightly overfilled with a minimum of splash. If there is any concern of proper fill, a radiograph should be exposed at this time. *Closure:* The cotton pellets are removed and the area thoroughly cleaned and debrided. The defect is packed with an osseopromotive substance and the incision closed normally. If a post-operative radiograph has not been exposed, one should be at this point. *Post-operative care:* Proper pain medications and antibiotics are prescribed and the clients instructed to feed only soft food for 2 weeks. Recheck radiographs in six months are critical to ensure success of the procedure.

Discussion and Conclusions: There are several indications for surgical endodontic therapy. However, for many of these indications, standard root canal therapy may be preferable. In addition, debilitated patients should be treated with exodontic therapy due to the markedly decreased anesthetic time. In cases where it is indicated, however, this procedure does carry a very good prognosis if performed skillfully. Ultrasonic retro-preparation tools are commercially available and improve the prognosis in these cases. If a practitioner is performing endodontic therapy on a routine basis, this would be a wise investment. Regardless of the apparent clinical success of the procedure, recheck dental radiographs in 6-9 months are mandated to ensure that the infection has been cured.

References: Wiggs R.B. & Lobprise H.B. 1997. Advanced endodontic therapies, p.341-342. In: Veterinary Dentistry: principals and practice. Lippincott-Raven, Philadelphia, PA. - Holmstrom S., Frost P. & Eisner E. 1998. Endodontics, p.312-317. In: Veterinary Dental Techniques. 2nd ed. W.B. Saunders, Philadelphia, PA. - Gagliani M., Taschhieri S. & Molinari R. 1998. Ultrasonic root-end preparation: influence of cutting angle on the apical seal. J. Endod. 24(11):726-30.

INDEX TERMS: Surgical endodontics, retrograde, root canal therapy.

044. Okuda A.[1,2], Ichihara N.[2] & Asari M.[2] 2007. **Clinical concern of impacted teeth in dogs.** *Pesquisa Veterinária Brasileira 27(Supl.):00-00.* [1] Vettec Dentistry: 3-20-7 2B Higashimukojima, Sumida-ku, Tokyo 131-0032, Japan; [2] Dept of Anatomy, Faculty of Veterinary Medicine, Azabu University : 1-17-71 Fuchinobe, Sagamihara 229-8501, Japan. E-mail: aykvtd@sepia.ocn.ne.jp

Introduction: Impacted teeth are not completely erupted, may cease to erupt before emergence to the oral cavity fully or partially are covered by gingival and/or bone (Shafer et al. 1983, Ishikawa & Akiyoshi 1989). Impaction is an abnormality of time and/or space of eruption[1)]. Pathologically conditions of clinically unerupted teeth are often subdivided into impacted and embedded teeth; the former is obstructed by physical barriers and the latter cannot be exhibit by lack of eruptive force (Neville et al. 2002). It is not always easy for impacted and embedded teeth to be diagnosed differentially each clinical situation. Clinically impacted teeth are recognized as missing teeth. Thus, they are not always recognized until the signs of cysts or tumor are appeared or a chance is taken any examination or treatment under general anesthesia. The early clinical signs of cysts or tumor with impacted teeth are very subtle or none. In veterinary dentistry there are a few descriptions of unerupted teeth (Wiggs & Lobprise 1997). The author reviewed 46 dog cases with single or multiple impacted teeth with comparing data from human literatures.

Materials and Methods: Clinically diagnosed impacted teeth were found radiological examinations with or without clinical signs. Only impacted teeth with tumors or advanced dentigerous cysts were referred us because of obvious clinical signs, such gingival swellings or jaw swellings, recognized by clinicians or owners. Most of impacted teeth were accidentally found at routine dental prophylaxis, extraction of deciduous teeth, or non-dental conditions. Ninety eight permanent teeth and 19 deciduous teeth were impacted in 46 dogs; 5 dolicocephalic breeds (Borzoi, miniature Dachshund, Wippet,), 14 mesiocephalic breeds (Cairn terrier, Golden retriever, Labrador retriever, miniature schnauzer, Shiba-inu, Yorkshire terrier, mixed breeds) and 27 brachyocephalic breeds (Boxer, Boston terrier, Chihuahua, Pomeranian, Pug, Shih-Tzu), in which 25 cases were small brachyocephalic breeds. Ages of dogs were 4months to 12yrs. Dogs with impacted teeth were 19 males and 27 females.

Results: Impacted teeth were more frequently found in brachyocephalic breeds, rather than dolicocephalic and mesiocephalic breeds. Factors associated with impacted teeth were abnormal eruptive direction, thinckened gingival or bone, dentigerous cysts/tumors or enamel/dentin hypoplastic conditions. Multiple unerupted teeth were found in 11 cases of 18 in dolicocephic and mesiocephalic breeds, associated with enamel and/or dentin hypoplastic conditions. Most frequently impacted teeth in hypoplastic conditions were lower second, third and forth premolars. No permanent teeth (25 teeth) were erupted in one case with regional odotohypoplasia at 10 months-old. Impacted enamel hypoplastic teeth were resorbed

externally at crown or cervical area. Dentigerous cysts, including 2 cases of eruption cysts were most frequently found with impacted lower canines, and upper canines and lower first premolars in 21 dogs that were found in 16 cases of brachyocephalic breeds. Most severe pathological dentigerous cysts were associated with lower canines. Deciduous impaction was found in 4 to 5 months-old puppies, that is so-called eruption cysts. Anterior deciduous teeth, 12 incisors and 7 canines, were covered by thickened gingiva with root resorption. Ameloblastoma was associated with impacted lower canine in one case and compound odontoma was found with impacted upper deciduous canine.

Discussion and Conclusion: In human dental textbooks (Shafer et al. 1983, Ishikawa & Akiyoshi 1989, Neville et al. 2002) the causes of unerupted conditions are explained: 1) abnormal location and eruptive direction of tooth germs, 2) lack of space to erupt, 3) abnormal shape and size of teeth, 4) overlying cysts and tumors, 5) thickened bone or soft tissue, 6) abnormal development of tooth, 7) idiopathic. Cysts or tumors may also be result by impacted teeth. Upper and lower 3rd molars and upper canines are the most often impacted in human, followed premolars and supernumerary teeth. Most of 3rd molars and supernumerary teeth in human have lack of space to erupt mostly. Frequency of impacted teeth in small brachyocephalic breeds may be caused by abnormal direction of tooth germs or lack of space to erupt. Small brachyocephalic breeds have narrow rostral jaw not enough to align canines and incisors properly as well as dental alignment of premolars and molars are also crowding. Lower canines, incisors and first premolars in small brachyocephalic breeds frequently are located horizontally and rosto-lingually, make a high risk to be impacted with pushing lower incisors rostrally and forming dentigerous cyst around crown of impacted canines. Lower first premolars are often covered with thickened gingival, but not always form cyst. And developmental abnormalities, such enamel/dentin hypoplasia, make abnormal shape and size of teeth with lack of eruptive force themselves. The impacted hypoplastic teeth were submerged in the middle of mandible without any physical disturbances. Crown of impacted teeth with hypoplasia were resorbed in the jaws. Preferential teeth to be impacted are canines, premolars, and rarely incisors. Clinical concerning of impacted teeth in human are mostly 1) dislocation of proximal teeth, 2) root resorption of proximal teeth, 3) sensory loss or trismus, 4) TMJ injury, 5) alveolitis, 6) infection, 7) cysts and tumor formation (Ishikawa & Akiyoshi 1989, Neville et al. 2002). Impacted lower third molars make severe clinical conditions mostly (Shafer et al 1983, Ishikawa & Akiyoshi 1989, Neville et al. 2002). And also impacted teeth self may be resorbed in alveolar bone (Shafer et al 1983, Ishikawa & Akiyoshi 1989, Neville et al. 2002). Stafne and Austin (1945) reported that resorption started on enamel or enamel-cement junction but not on root and upper canines were the most often resorbed. Impacted teeth associated with enamel/dentin hypoplasia in dogs had enamel resorption with time, finally disappeared. The roots of the teeth were left in bone often. But abnormal shape of roots was also resorbed as well as crown and replaced by bone. Clinically concern of impacted teeth left in submerged condition, lower permanent canines may have a risk of severe pathological condition to form dentigerous cysts. Lower first premolars may also have a risk of dentigerous cyst formation. Impacted teeth with enamel or dentin hypoplasia may have a less risk to form cysts.

References: Ishikawa G. & Akiyoshi M. 1989. Developmental abnormalities of teeth, p.35-107. In: Oral Pathology. 2nd ed. Nagata shoten, Tokyo (in Japanese). - Neville B.W., Damm D.D., Allen C.M. & Bouquot J.E. 2002. Abnormalities of teeth, p.66-106. In: Oral Maxilofacial pathology. 2nd ed. W.B. Saunders, Philadelphia. - Shafer W.G., Hine M.K. & Levy B.M. 1983. Developmental disturbances in structure of teeth, disturbances of development and growth, resorption of teeth, p.51-69, 328-333. In: A textbook of Oral Pathology. 4th ed. W.B. Saunders, Philadelphia. - Stafne E.C. & Austin L.T. 1945. Resorption of embedded teeth. J. Am. Dent. Assoc. 32:1003. - Wiggs R.B. & Lobprise H.B. 1997. Dental and oral radiology, p.160. In: Veterinary Dentistry, Principles and Practice. Lippincott-Raven, Philadelphia.

INDEX TERMS: Impacted teeth, dentigerous, cysts, enamel/dentin hypoplasia, coronal resorption.

045. Okuda A.[1], Ehara T.[2], Makino H.[3] & Morozumi M.[3] 2007. **Clinical trial of a direct capping technique for extensive palatal defect with using silicon denture liner material.** *Pesquisa Veterinária Brasileira 27(Supl.).* [1]Vettec Dentistry, 3-20-7 2B Higashimukojima, Sumida-ku, Tokyo 131-0032, Japan; [2]Temma Animal Clinic, 3-11-34 Tenjinbashi, Kita-ku, Osaka, Osaka 530-0041, Japan; [3]Togasaki Animal Clinic, 2-160-4 Togasaki, Misato, Saitama 341-0044, Japan. E-mail: aykvtd@sepia.ocn.ne.jp

Introduction: Clinically we have encountered cases of unhealed extensive palatal defect caused by extensive injuries, tumor removal or radiation therapy. To close such extensive palatal defect, either surgical techniques or making a cap may use. To make a palatal cap requires two episodes of anesthesia; taking impression and setting a cap in a veterinary literature (Harvey & Emily 1993). Using human silicon-based denture liner, a palatal cap can be made directly in a mouth at one episode of anesthesia. This silicon cap stays for 3-6 months without any care in a mouth. This technique can be also available for closing surgically unclosed nasal cavity after late radiation effect.

Materials and Methods: Under general anesthesia epithelialized palatal or nasal defects are cleaned. Silicon-based denture liner material (Tokuso, human silicon denture liner, Japan) are placed on a flat silicon flat board. The amount of the material should be enough to cover the defects and overflow to make overhung inside of oral or nasal cavity. Usually it takes 4min to be hardened. Once material was hardened, it is trimmed by scissors in the cavity or outside of the cavity to be shaped.

Results: 1) A 6yrs-old, spayed miniature Pinscher had extensive palatal defect with very thin and rippable oral membrane. The silicon cap made to cover for unhealed defect. Once this silicon cap was placed on the palatal defect, it stayed for 4 to 6months. 2) A 12yrs, spayed Shetland sheepdog had necrotic bone and connective tissues after surgery and radiation therapy for removal nasal tumor on the nose. The defect after removed necrotic bone and tissues was covered by this silicon denture liner material. The nasal membrane healed well and frequent sneezing was less.

Discussion and Conclusion: To cover extensive palatal defect surgeries with using larger gingiva and labial membranous flap after all teeth extraction or with using tongue are described in text (Harvey & Emily 1993). Another way to cover a defect is to make a palatal cap, which needs two episodes of anesthesia; taking impression and setting a cap in a veterinary literature (Harvey & Emily 1993). This direct technique is easy to make at one episode of anesthesia. Silicon material has not been resolved or shrunk to change the shape for a year, but generally frequent putting-on & off makes the size of defects larger and need to make much larger cap. As this silicon is much softer than general silicon impression materials, this can be placed at the area that is thin-epithelial linings.

References: Harvey C.E. & Emily P.P. 1993. Acquired hard palate defects, in the chapter of oral surgery, p.351-354. In: Small Animal Dentistry. Mosby, Philadelphia.

INDEX TERMS: Extensive palatal defect, silicon-based human denture liner material and direct capping method.

046. Pachaly J.R. 2007. **Dissociative anesthesia applied to dentistry procedures in domestic and wild carnivores, with allometrically scaled dosage protocols.** *Pesquisa Veterinária Brasileira 27(Supl.).* Programa de Mestrado em Ciência Animal, Universidade Paranaense (Unipar), Umuarama, PR 87502-210, Brazil. E-mail: pachaly@uol.com.br

Introduction: This paper reports the results of the association of a combination of tiletamine and zolazepam to alpha-2 adrenoceptor agonists (xylazine or romifidine) and atropine in the dissociative anesthesia of domestic and wild carnivores submitted to dental procedures. The objective of this study was to evaluate both the efficacy of the drug combinations and the allometric scaling method of dosage calculation. The combination of tiletamine-zolazepam to alpha-2 adrenoceptor agonists in the chemical restraint of domestic and wild carnivores have yielded encouraging results (Pachaly 2001, 2002, Pachaly et al. 2001, 2004ab, 2006, Azzolini et al. 2005, Giacometti et al. 2006). The method of allometric scaling was recently reviewed (Pachaly & Brito 2001) and it allows extrapolation of drug doses between animals of different sizes and/or taxa, facilitating the use of data obtained in a "model animal" (animal for which the drug was developed) for the treatment of a "target animal" (wild or domestic patient).

Materials and Methods: From June 1999 to June 2006 the staffs of the Services of Dentistry and Wildlife Medicine of the Universidade Paranaense (Umuarama, PR, Brazil) anesthetized 223 domestic dogs (*Canis familiaris*), 43 domestic cats (*Felis catus*), 18 african lions (*Panthera leo*), 12 jaguars (*Panthera onca*), five pumas (*Puma concolor*), two maned wolves (*Chrysocyon brachyurus*), two brown bears (*Ursus arctos*), and one spectacled bear (*Tremarctus ornatus*) for dental procedures. The animals were anesthetized in the Veterinary School Hospital of the Universidade Paranaense and several pet clinics, zoos, and circuses. Dogs, cats, bears and wolves were anesthetized with a combination of tiletamine, zolazepam, xylazine, and atropine (TZXA), while Jaguars, pumas, and lions were anesthetized with a combination of tiletamine, zolazepam, romifidine, and atropine (TZRA). All doses were established by allometric scaling, using a 10 kg dog and a 500 kg horse as models. Using the dog model, the following doses were used: tiletamine plus zolazepam at 5.0 mg/kg; xylazine at 1.0 mg/kg; and atropine at 0.05 mg/kg. For the horse model, the used dose of romifidine was 0.08 mg/kg. In all cases the drugs were mixed and administered intramuscularly by direct injection or by darts delivered by a blowgun. All patients were carefully monitored, starting immediately after losing the righting reflex until they were fully recovered by exhibiting normal ambulation. The following physiological parameters: heart frequency, respiratory frequency, rectal temperature, and SpO_2, as well as response to painful stimuli were monitored every 10 minutes, during anesthesia.

Results: Animals anesthetized with both combinations lost the righting reflex (RR) within 2 to 11 min post-injection (MPI), and deep anesthesia occurred in all cases, beginning between 5 to 14 MPI. All patients showed excellent myorelaxation, and remained safely anesthetized under a proper anesthetic plan for 57 to 113 MPI. Conscious reactions were noted between 89 and 162 MPI, and return of RR between 120 and 225 MPI. The proposed anesthetic protocols proved to be safe and effective in all kinds of dental procedures, including periodontics, exodontics, endodontics, and restorative dentistry, as well as many other concomitant procedures as transponder placement, biological sample collection, and physical radiographic and ultrasonographic examination.

Discussion and Conclusions: The results lead to conclude that the use of the association TZXA is a good option in field anesthesia for dental procedures in domestic dogs, domestic cats, maned wolves, and bears, as well as the association TZRA is equally useful in african lions, jaguars, and pumas. Furthermore, allometric scaling proved to be a useful tool for determining a safe initial dose of the anesthetic agents in the wild felids in this study.

References: Pachaly J.R. & Brito H.F.V. 2001. Interspecific allometric scaling p.475-481 In: Fowler M.E. & Cubas Z.C. (ed.), Biology, Medicine, and Surgery of South American Wild Animals. Iowa University Press, Ames. - Pachaly J.R. 2001. General anesthesia of a jaguar (*Panthera onca* Linnaeus, 1758) with allometrically scaled doses of romifidine, tiletamine, zolazepam and atropine. Arq. Ciênc. Vet. Zool. Unipar 4:228. - Pachaly J.R. et al. 2001. General anesthesia of a jaguar (*Panthera onca* Linnaeus, 1758) with allometrically scaled doses of romifidine, tiletamine, zolazepam and atropine: case report. Arq. Ciênc. Vet. Zool. Unipar 4:244. - Pachaly J.R. 2002. Field trial on anesthetizing big wild felids with allometrically scaled doses of romifidine, tiletamine, zolazepam and atropine: preliminary report. Arq. Ciênc. Vet. Zool. Unipar 5:346. - Pachaly J.R. et al. 2004. The use of romifidine hydrochloride associated to tiletamine, zolazepam, and atropine in the chemical restraint and anesthesia of jaguars (*Panthera onca*): preliminary report. Arq. Ciênc. Vet. Zool. Unipar 7-s 1:62. - Pachaly J.R. et al. 2004. The use of romifidine hydrochloride associated to tiletamine, zolazepam, and atropine in the chemical restraint and anesthesia of lions (*Panthera leo*): preliminary report. Arq. Ciênc. Vet. Zool. Unipar 7-s1:63. - Azzolini F. et al. 2005. Contenção farmacológica e anestesia de carnívoros domésticos e selvagens e primatas pela associação de agonistas de receptores alfa2-adrenérgicos a tiletamina, zolazepam e atropina, com protocolos posológicos calculados por meio de extrapolação alométrica interespecífica. IV Encontro de Iniciação Científica e IV Fórum de Pesquisa da Unipar. UNIPAR, Umuarama, p.21. - Pachaly J.R. et al. 2006. Romifidine HCl as adjuvant to dissociative anesthesia in big wild felids in Brazil. Proc. Annu. Conf. Am. Assoc. Zoo Vet., AAZV, Tampa, p.228-230. - Giacometti C. et al. 2006. Anestesia de primatas e carnívoros selvagens pela associação de agonistas alfa2-adrenérgicos a tiletamina, zolazepam e atropina, e antagonismo pela ioimbina. V Encontro de Iniciação Científica e V Fórum de Pesquisa da Unipar. UNIPAR, Umuarama, p.25.

INDEX TERMS: Carnivores, dissociative anesthesia, dentistry, allometric scaling.

047. Pavezi K.S. & Gallo M.A. 2007. Dental radiographic study in horses using intra-oral techniques. *Pesquisa Veterinária Brasileira 27(Supl.).*

Private Practicioner, São Paulo, SP 04576-040, Brazil. E-mail: karinapavezivet@yahoo.com.br

Introduction: The radiographic evaluation of the horse's skull is extremely important, for the reason that this anatomical region is easily investigated by radiographic examination. The standard radiographs provide an excellent contrast between mineralized tissues, such as bone structures and the dental enamel, as well as the gas inside the hollow structures of the skull. By the way, it's worth mentioning that dental enamel is the most radiopaque organic substance known in the mammal's organisms. Although having the horse's skull large dimensions, portable x-ray machines are quite efficient for making such radiographs, even in the field. The use of intra-oral radiographic techniques, improve the images quality in terms of detail and resolution, avoiding the undesired superimposition over the opposite hemi-arcade, what makes this method, one of the most important auxiliary diagnostic techniques for the odontology.

Materials and Methods: For the procedure of dental intra-oral radiographic examination, either portable or stationary x-ray units can be useful, requiring a minimum output of 70 kVp, nevertheless, stationary units with output between 100 and 150 kVp produce better radiographic details. The good results in making intra-oral images depends on several radiographic accessories, made on adapted sizes, such as rigid wooden tunnel, to prevent the cassette from horse's bite; nylon water resistant flexible cassette, with reduced width, measuring 12x30 cm, to be adapted on the tongue's face of the teeth, to obtain the best radiographic images for molars and premolars teeth. Rigid cassettes, with approximately 15 cm width, are also helpful to be placed more caudally than ordinary cassettes, to achieve the best images of incisors and canine teeth. When the radiographic incidence investigates the upper dental arcade, we can see better details of the palate. The same adaptations should be done on the intensifying screens and film sizes. For the intra-oral radiographic techniques, we use compatible radiographic screens and films. The screens used in the study are regular ones (high speed). For the incisors and canine teeth, the conventional cassettes can be used, measuring 13x18cm or 18x24cm and the patient must be sedated and step square. In this case, the radiographic techniques are less penetrated because of the fragile thickness of the rostral dental and bone structures. The incidence should be dorsoventral for the upper arcade and ventrodorsal for the lower arcade. However, for molars and premolars, flexible cassettes should be used, with the patient in deep sedation or even general anesthesia, many times for surgical assistance. The best incidence to obtain a good image is the oblique view, in an angle of approximately 60° to 70° from the dorsoventral line of the skull. To avoid blood and saliva contact with the screen and film it's interesting using plastic film packed cassettes and to avoid the film chewing as well as to keep the horse's mouth open is always necessary the help of Mc Pherson's speculum. The other way to accomplish an accurate radiographic positioning is to do a lesion guided incidence of the x-rays. The external anatomical references for positioning the cassettes and shot the x-ray beams are: the second upper premolar is located just below the nasomaxillary notch; the first upper molar as well as the bony septum of the maxillary sinuses are located just below the rostral part of the facial crest of the maxillary bone; the third upper molar is located just below the medial angle of the eye, on the facial crest of the zigomatic bone. For the lower arcade, the second premolar is located below the nasomaxillary notch and the first molar, below the facial crest, both on the horizontal ramus of the mandible and finally the third molar is located on the vascular groove on the angle of the mandible.

Results: The most common intraoral radiographic findings seeing on the horses are principally the dental architectural, dental number and positioning, dental fractures, abnormalities of the lamina dura, root destruction.

Discussion and Conclusions: The intraoral dental radiographic approach in the horse is a remarkable diagnostic, assistance, prophylaxis and guiding device for veterinary odontologists in several dental disorders, providing excellent details of image and safeness in his procedures.

References: Baker G.J. 1999. Diagnosis of dental disorders, p.139-169. In: Easley K.J. & Baker G.J. (ed.), Equine Dentistry. W.B. Saunders, London. - Done S.H. 1989. Cabeça, p.2-50. In: Ashdown. R.R. & Done. S.H. (ed.), Atlas Colorido de Anatomia Veterinária, o Cavalo. Vol.1. Manole, São Paulo. - Easley K.J. 1996. Equine Dental Development and Anatomy. Proc. Am. Assoc. Equine Pract. 42:1-10. - Hillmann D.J. 1986. Osteologia equina, p.294-323. In: Getty R., Sisson S. & Grossman J.D. 1986. Anatomia dos Animais Domésticos. Vol.1. Guanabara Koogan, Rio de Janeiro. - Klugh D.O. 2003. Intraoral radiography of equine premolars and molars. Proc. 49th Congr. Am. Assoc. Equine Pract., IVIS. Disponível em www.ivis.org. Acessado em 2.12.06, 20:30h. - O'Brian R.T. 1996. Intra-oral radiography: experimental study and clinical use in two horses and a llama. Vet. Radiol. Ultrasound 37(6):412-414.

INDEX TERMS: Horses, radiography, intra-oral.

048. Pimentel L.F.R.O. 2007. **Intraoral extraction techniques in standing horse.** *Pesquisa Veterinária Brasileira 27(Supl.).* M.V., mestrando, Departamento de Cirurgia de Grandes Animais, FMVZ- USP, São Paulo, Brazil. E-mail: luizrapp@unisys.com.br

Introduction: After years of little progress, the increased interest in equine dentistry in recent years has stimulated an increased desire to develop new techniques to treat dental disease (Dixon 1993). One technique is oral extraction of diseased equine teeth. This procedure has distinct advantages as avoidance of general anesthesia, potential complications and better cosmetic results, it also has its limitations (Lowder 1999). Oral extraction techniques originally described by Merillat (1906) have been reviewed and found to be successful in both conscious sedated and anaesthetized horses. Because equine cheek teeth are hypsodont, their extraction by any techniques can be difficult (Dacre & Dixon 2004).

Materials and Methods: 1) Examination procedures; a thorough clinical examination which must include a detail intra-oral examination using a full mouth speculum should be performed in all cases, using a good light source and a dental mirror, along with digital palpation of the suspect tooth. If the horse is uncooperative, sedation must be used for this examination. If dental disorders are suspect to affect the deeper intra-alveolar aspects of the teeth (e.g., apical infections), radiographic evaluation of teeth should always be undertaken, to absolutely confirm that a tooth needs to be extracted and also to identify which tooth is diseased. Indications for radiology include impacted premolars, fractures of teeth or skull, draining tracts, painful areas in and around the mouth, abscesses, aberrant teeth, foreign objects, abnormal behavior, (biting, riding or head carriage problems) and missing, maligned or supernumerary teeth. If any doubt remains concerning whether a tooth is apically infected or not, conservative treatment and not extraction should be undertaken (Lowder 1999, Dacre & Dixon 2004). 2) Restrain; most of horses tolerate the extraction *per os* under standing chemical restraint, although general anesthesia is necessary in a small proportion of nervous or fractious hoses. (Tremaine 2005). Deep sedation and analgesia is achieved with i.v. Rofimidine (Sedivetä) (80-120μg/kg bwt) combined with Burtofanol (TorbugesicÔ) (25μg/kg bwt) and in same cases morphine (0.15mg/kg bwt). Further increments of sedatives and analgesics are administered as required. (Dixon et al. 2005). Local nerves blocks can also give good analgesia and, can be used in these cases. (Viegas Jr 2006). 3) Extraction Techniques; **3.A-Incisors**: in a standing horse with minimal restraint, retained incisors can usually be loosened with dental elevators and the extracted by means of small animal forceps. Occasionally, it is necessary to make a incision in labial aspect of the gum overlying the retained incisor to allow the incisor to be loosened with a dental elevator before it can be extracted (Dixon 1997). Supernumerary incisors occur sporadically, and more than one may be present. The occlusal surfaces of the teeth appear similar to normal incisors and they have reserve crowns, which are often equal in length and shape to normal incisors. Radiographs are useful to detect non erupted permanent incisor and discriminate between retained primary teeth and supernumerary incisors. However, despite careful examination and radiographs it can be difficult to distinguish the supernumerary teeth from the normal teeth (Tremaine & Lane 2005). The extraction of supernumerary teeth thus requires extensive surgery and also risks damaging the adjacent normal teeth. Because these supernumerary teeth are generically innocuous, they are best left alone, except perhaps in show horses (Dixon 1997). Extraction of permanent incisor may be performed under sedation with alpha-2 agonist and opiate analgesic and regional desensitization. Incisors can be removed by freeing the periodontal attachments around the whole circumference of the tooth gradually until it is sufficiently loose to remove. Teeth which cannot be sufficiently loosened can be sometimes extracted after making a gingival incision and removing part of the labial alveolar plate, using a narrow (1cm) osteotomy. Incisors which have became totally separated from their gingival attachments as a result of trauma or avulsion of the corner of incisive bone or rostral mandible should be removed. However, incisors that retain some gingival attachments may remain viable and can often be salvaged after reduction and immobilization of the fracture using stainless steel wire (Tremaine & Lane 2005). - After the teeth be removed, the alveolar space can be protected by packing it with gel foam, this promove good cicatrization and avoid the accumulation of food (Pimentel, personal communication). **3.B- First Premolars (Wolf Teeth)**: the vestigial and inconsistent first upper premolar teeth (Triadan 105 and 205 "Wolf teeth") are frequently alleged by owners and trainers to cause biting and behavioral problems. Most wolf teeth never cause a biting problem, but sharp, grossly enlarged or buccally displaced teeth often do (Dixon 1997, Easley 2004).Wolf teeth are easily extracted in the young horse. Sedatives/analgesics or local anesthesia is recommended before extraction. The gingival margins of Wolf tooth is cut free using the cylinder of the Burgess instrument. The dental root elevator is then introduced deep into the alveolus to loosen the tooth from its periodontal and alveolar attachments. If during the extraction, progress is not made loosing a tooth, radiography may be indicated. Madibular Wolf teeth can be extracted in similar manner as maxillary Wolf teeth (Easley 2004). Non erupted or blind Wolf teeth, if present, are usually detected by palpation of hard nodule in the interdental space. The technique used for removal this teeth follows the same basic principles as that for removing erupted Wolf teeth (Easley 2004). **3.C- Canine Teeth**: unless the canine are positioned abnormally, they should not interfere with the bit. Rarely, it is necessary for a mal positioned canine tooth to be extracted. Extensive lateral resection of the supporting bone and alveolus is required to remove such teeth; this usually necessitates general anesthesia (Dixon 1997). **3.D- Deciduous Cheek Teeth:** retained deciduous premolars (caps) are often detected after owner notices of abnormal eating habits, head carriage, facial swelling or blood in the mouth. A medium sized (16-in) pair of molar forceps should be used to grasp the retained deciduous premolar and rotate it in a buccal to lingual direction. In some cases, the tooth caudal to the retained deciduous tooth might impede shedding of the deciduous teeth, and strong force will be needed to remove the deciduous tooth. Excessive force is rarely indicated; if it became necessary to use excessive force, the situation should be again evaluated and a radiograph of the area is indicated (Lowder 1999). **3.E- Permanent Cheek Teeth:** this technique has the great advantage of being capable of being performed in standing horse in most cases and, thus, remove the expense of general anesthesia. A prerequisite for oral extraction of equine cheek teeth is excellent chemical restraint of the horse, which should achieved by combinations of the drugs previously mentioned and blocking the mandibular alveolar nerve (Dacre & Dixon 2004). Following the placement of a full mouth speculum, the gingival on medial and lateral aspects of affected cheek teeth are separated from the affected cheek teeth to the level of alveolar crest using a dental pick. The blades of molar spreader are pushed slowly into the interdental space, just above the gingival

margin, rostral to and then caudal to the affected tooth, and left in this position for 3-5 minutes. When extracting a Triadan 07 cheek teeth, the molar spreaders are used with caution rostral to this tooth, to prevent the adjacent, normal 06 from being displaced rostrally (Dixon et al. 2005). The molar extractors then can be placed on the tooth. Molar extractors come in different sizes and no single instrument is perfect to every tooth. Mandibular cheek teeth are nower than the maxillary counterparts and therefore require an instrument with nower space between the jaws when the hands are closed. Maxillary teeth usually require a wider instrument. Good instrument-tooth contact is essential, and instruments with toothed or knurled jaws are preferable. (Tremaine 2004). The molar extractor is then firmly attached to the crown of diseased tooth. The initial movements should be a gentle movement in latero-medial plane. The operator should continually cheek that the jaws of the extractor remain tightly fixed on the crown of affected tooth. If the forceps become loose, they may wear away the crown of the diseased tooth to a small, rounded structure and then there may not be enough occlusal left to allow the tooth to be orally extracted. The molar spreader must be intermittently used during the extraction procedure to cause a progressively degree of caudo-rostral movement of affected tooth (Dare & Dixon 2004). When the periodontal attachments are loosened, a distinctive "squelching" sound can be heard, and the resistance to oscillation of the extractor decreases. This is frequently accompanied by fresh foamy hemorrhage around the gingival margins (Tremaine 2004). In a personal communication, J.Easley, said that, "in addition to disrupting the periodontal membrane, it has been suggested that this loosing contributes to stretching the alveolus, facilitating extraction". According to J.Easley, in another personal communication, some authors recommend postponing the extraction until the following day, when alveolar hemorrhage may have contributed to further loosening of the tooth. At this stage, a fulcrum is placed on the occlusal surface of the tooth rostral to the infected tooth. If the first cheek teeth (06s) are being extracted, a 5cm deep wooden block can be placed in interdental space ("bars of mouth") to act as a increasing vertical pressure is now exerted on the forceps, drawing the intact affected tooth from the alveolus into the cavity (Dare & Dixon 2004). In case of doubt post operative radiographs must be taken to confirm that diseased tooth has been extracted completely. After curettage, the the alveolar space is washed with 0.5 % chlorhexidine solution using a Water-PickÔ with 7 bar of pressure. The alveolar space is dry up. A 37,5 % ortophosphoric acid paste is applied over mesial proximal and mesial distal borders of teeth surrounding the alveolar space. After 2 minutes the alveolar space is cleaned. In the bottom of alveolar space gel foam impregnated with metronidazole antibiotic is applied to promote increased cicatrization. Over the gel foam and 2cm above the occlusal surface the alveolar space is packed with methylmethacrylate plug. If dental disease associated with an external sinus tract or secondary paranasal sinusitis may require drainage from maxillary sinus into nasal cavity. Through a drill hole in frontal or rostral sinus a window is make in the less -vascular dorsal aspect of ventral concha. Even at site, severe hemorrhage usually occurs and requires nasal packing. A catheter is sutured into the frontal sinus through the hole (to allow post operative irrigation of caudal maxillary sinus) or into the rostral maxillary sinus (if a more rostral cheek tooth was extracted and the septum between maxillary sinuses is intact). After sinus irrigation with 5 liters of dilute, lukewarm povidine-iodine, a solution of 100ml of D.M.S.O., 100ml of Neomycine (40mg/ml) and 800ml of Ringer's solution is used make the irrigation of the sinus. 100ml this solution through the catheter i s put into the sinus twice a day for approximately 6 weeks or until the malodorous nasal discharges ceases.

Results: a 100% of the intra-oral extractions of Incisors, First Premolars and Deciduous Cheek Teeth were successful. The success rate of intra-oral extractions of Permanent Cheek Teeth is 70%.

Discussion and Conclusions: Tooth removal should be considered after other more conservative treatments have failed or offer poor prognosis. Advantages of extraction *per os* has been technique as avoidance of general anesthesia, lower costs, potential complications and better cosmetic results, it also has its limitations (Lowder 1999, Dixon et al. 2005). The most common reasons for dental exodontia include: retained deciduous incisors or premolars, teeth affected by severe periodontal disease, loose teeth, fractured teeth, displaced or maligned teeth, supernumerary teeth, dental impaction, teeth with apical abscesses, teeth devitalized as a consequence of mandibular or maxillary fracture, dental overgrowths resulting of soft-tissue trauma, sinusitis caused by diseased teeth (Lowder 1999, Tremaine & Lane 2005). Potential disadvantages associated with this procedure include the potential for fracturing the diseased tooth, inability to remove the affected tooth and laceration or bruising the oral cavity (Lowder 1999).The actual oral extraction technique and instrumentation as described by Merillat (1906) and O'Connor (1942) have largely unchanged, but the advent of safe and effective alpha-agonist tranquilizers (in combination with i.v. Analgesics) has facilitated the reintroduction of this technique for use in the standing horse (Dixon et al. 2005). In according to related by Treamine (2004), extraction *per os* has been technique of my choice for dental removal and has been associated with a considerably reduced incidence of complications than that associated with repulsion. The costs and risks associated with equine general anesthesia mean that the ability to extract cheek teeth in conscious sedated horses offers considerable advantages. Even if attempted exodontia in sedated horses is unsuccessful, extraction *per os* performed under anesthesia general has advantages over other techniques in view of reduced incidence of complications and post operative care. In those horses where the initial attempt at extraction *per os* is unsuccessful, subsequent repulsion is greatly facilitate by weakening of some of periodontal attachments, thereby reducing the enormous forces needed to repulse a tooth with intact periodontal attachments (Tremaine 2005).

References: Dacre I. & Dixon P.M. 2004.Oral extraction of cheek teeth in standing horse: indications and techniques. Am. Assoc. Equine Pract. 50:405-409. - Dixon P.M. 1993. Equine dental disease: a neglected field of study. Equine Vet. J. 5:317-353. - Dixon P.M.1997. Dental extraction and endodontic techniques in horses. Compend. Cont. Educ. Pract. Vet. 19:628-637. - Dixon P.M. et al. 2005. Standing oral extraction of cheek teeth in 100 horses. Equine Vet. J. 37(2): 105-112. - Easley K.J.2004. Equine canine and first premolar (wolf) teeth. Am. Assoc. Equine Pract. 50:402-404. - Lowder M.Q. 1999. How to perform oral extraction of equine cheek teeth. Am. Assoc. Equine Pract. 45:131-136. - Tremaine W.H. 2004. Oral extration of equine cheek teeth. Equine Vet. Educ. 16(3):151-158. - Tremaine W.H. & Lane J.G. 2005. Exodontia, p.151-169. In: Easley K.J. & Baker G.J. (ed.), Equine Dentistry. 2nd ed. W.B. Saunders, London. - Viegas Jr C.R. 2006. Bloqueios anestésicos perineurais utilizados em odontologia eqüina. In: 7º Congr. Bras. Cirur. Anest. Vet., Mini-Curso de Odontologia Eqüina, p.39- 49.

INDEX TERMS: Intraoral extraction, oral exodontia.

049. Ramos-Silva M., Gioso M.A. & Sá F.B. 2007. **Clinic and histological characterization of gingival epithelium of periodontal disease in dogs.** Pós-Graduação em Ciência Veterinária, UFRPE, Recife, PE 52171-900, Brazil. E-mail: odontologiavet@yahoo.com.br

Introduction: Periodontal disease is clinical and histological characterized by the degradation of extracellular matrix components associated with a gingival infiltration of inflam-matory cell populations. The purpose of the present study was to characterize the inflammatory stages in gingival epithelium of the first upper molar according to the number of cells (mono and polymorfo-nuclear), concentration of collagen fibers, vascularization and gingival thickness (Payne 1975, Schroeder 1975, Page 1997, Lindhe 1999).

Materials and Methods: Samples of free buccal gingiva of 21 dogs with different degrees of periodontal disease were collected. One fragment for each animal was compared in order to characterize the different stages of each sample through histological analysis of biopsy from the marginal gingival epithelium. For a precise study and to compare each fragment and each portion of the fragment they were subdivided into three portions: I -coronal, II - medium, III - apical. The cuts were evaluated histologically by hematoxylin and eosin staining and Gomori's trichromic. We took as reference the thickness of the gingival epithelium and the distance between basal layer and the epithelial surface to measure the degree of destruction. These measures were expressed in millimeters. The counting of the blood vases, mononuclear and polymorphonuclear cells was carried out choosing three random areas of each segment with the objective of 100x.

Results: Our results showed significant differences in the number of inflammatory cells of Groups I, II and III in the same sample according to severity of periodontal disease and suggest that its progression can be directly related with loss of collagen fibers and decrease in epithelium thickness, observed in different stages of the disease. Finally quantitative evaluation of the fraction containing gingival collagen fibers may reflect severity in periodontal clinical disease.

Discussion and Conclusions: Although part of the animals presented clinically signals of initial gingivitis, histological results showed that there was an invasion of inflammatory cells in the connective tissue characterizing advanced disease, according to Page (1997); he affirms that clinical alterations may seem subtle in the initial periods of gingivitis, however the underlying histopathological alterations are already sufficiently accented. One of the most important events in the pathogenesis of periodontal disease is the alteration of the constituents in the connective tissue in relation to the gingival epithelium. Examining the connective tissue area it's important to evaluate the development of cellular infiltration and the structural and cellular composition of the tissues which suffered alterations (Schroeder 1975, Lindhe 1999). Two types of established injury seem to exist. In the first one, the injury remains steady and does not progress for months or years (Harvey 1975, Payne et al. 1975); the second one can become more active and result into gradual destructive injury. This could be observed in our study in different segments of one same sample. Therefore, we look for correlations of the variable of the three segments (I, II and III) of the collected gingival sample, trying to establish interrelationships of the progressive inflammatory process. The objective was to promote early diagnosis or to give individually a prognostic for the progression of the injury in each segment of each sample. We know that the periodontal disease can persist for much time as initial injury and the variability of time necessary to produce an established inflammation can reflect in the variation of the individual susceptibility and between different individuals. This study reflects the importance of implementing the histopathological diagnosis as an additional tool in the early diagnosis of perio-dontal disease in dogs.

References: Harvey C.E. 1998. Periodontal disease in dog: etiopathogenesis, prevalence and significance. Vet. Clin. North Am. Small Anim. Pract. 28(5):1111-1128. - Lindhe J. 1999. Tratado de Periodontia Clínica e Implantologia Oral. 3ª ed. Guanabara Koogan, Rio de Janeiro, p.127-152. - Page R.C., Offenbacher S., Schroeder H.E., Seymour G.J. & Kornman K.S. 1997. Advances in the pathogenesis of periodontitis: summary of developments, clinical implications and future directions. Periodontol. 14:216-248. - Payne W.A., Page R.C., Ogilvie A.L. & Hall W.B. 1975. Histopathologic features of the initial and early stages of experimental gingivitis in man. J. Periodont. Res. 10:51-64,. - Schroeder H.E., Beer Graf de M. & Attstrom R. 1975. Initial gingivitis in dogs. J. Periodont. Res. 10:128-142.

INDEX TERMS: Veterinary dentistry, gingiva, periodontophaty, dogs.

050. Reiter A.M. 2007. **Masticatory muscle myositis (MMM) in dogs: etiology, pathogenesis, diagnosis and treatment.** *Pesquisa Veterinária Brasileira 27(Supl.).* Department of Clinical Studies, School of Veterinary Medicine, University of Pennsylvania, Philadelphia, PA 19104, USA. E-mail: reiter@vet.upenn.edu

Introduction: Masticatory muscle myositis (MMM) is an autoimmune disease affecting the muscles of mastication in dogs (temporal, medial and lateral pterygoid, and masseter muscles). Eosinophilic myositis and atrophic myositis have been described in the past as two separate disorders, but it is likely that they are the acute and chronic stages of MMM (Shelton et al. 1987, Gilmour et al. 1992). MMM most commonly affects young adult, large breed dogs (Gilmour et al. 1992). History and clinical signs of acute MMM include lethargy, fever, reluctance to eat, masticatory muscle swelling, exophthalmos (from enlarged pterygoid muscles), mandibular lymphadenopathy, pain on yawning or palpation of masticatory muscles, and difficulty to open the mouth. In chronic MMM, dogs may appear to be systemically normal, but there is progressive atrophy of masticatory muscles (Gilmour et al. 1992). Hematological and serum chemistry findings of dogs with MMM may include elevations in total protein, creatine kinase, and liver enzymes, but eosinophilia is not considered to be a consistent hematological finding (Gilmour et al. 1992). Antibodies against type 2M fibers may be detected in serum of over 80% of dogs with MMM (Shelton et al. 1987). Dogs diagnosed with MMM should be treated with immunosuppressive doses of prednisone (1-2 mg/kg PO BID) (Gilmour et al. 1992). The dose can be decreased after 2-4 weeks and is then slowly tapered to the lowest possible alternate-day effective dosage over

several months (Shelton & Cardinet, 1989). Inadequate dosing or treatment for an insufficient period of time will result in a high rate of relapses. Dogs should be reinstituted at the initial treatment dose if relapses occur. Dogs that do not respond or show unacceptable side effects to oral prednisone may benefit from treatment with other immunosuppressive drugs such as azathioprine (Gilmour et al. 1992). The long-term prognosis is usually good if aggressive treatment with corticosteroids is instituted. Affected dogs should frequently be monitored for relapses during tapering of the prednisone. Some dogs may require life-long, low-dose, alternate day prednisone therapy to prevent relapses (Gilmour et al. 1992).

Discussion: The etiology of MMM is unknown. One hypothesis suggests that antibodies are produced in response to an infectious agent, and then these antibodies start cross-reacting with self-antigens (Melmed et al. 2004). Masticatory muscles are mainly made up of type 2C fibers (called type 2M [masticatory] fibers which contain a unique myosin component). In MMM, the immunological attack is limited to these fibers (Shelton et al. 1985). Intense multifocal, perivascular infiltration of lymphocytes, plasma cells, and macrophages and atrophy, necrosis of type 2M fibers, and peri- and endomysial fibrosis are common histological findings in masticatory muscle specimens of dogs with MMM. In most cases, eosinophils are either absent or present in low numbers (Gilmour et al. 1992, Shelton et al. 1987). Staining of immune complexes in masticatory muscles can be detected in over 80% of dogs with MMM (Shelton et al. 1988). Differential diagnoses of MMM are several head and neck disorders that can make a dog unwilling or unable to open its mouth, including maxillofacial trauma, temporomandibular joint disease, bone and soft tissue neoplasia, ocular and space-occupying retroorbital pathology, ear disease, and other neuromuscular conditions such as trigeminal neuropathy, polymyositis, extraocular muscle myositis, dermatomyositis, laryngeal myositis and myositis ossificans. MMM should be suspected if clinical and histological signs of myositis are restricted to masticatory muscles. Electromyography (EMG) is of help to differentiate MMM from polymyositis in that electrical activity in MMM occurs only in masticatory muscles, while other skeletal muscles remain electrically silent (Shelton & Cardinet 1989). Advanced imaging procedures (magnetic resonance imaging and computed tomography) can detect edema and inflammation in muscle tissue, with contrast enhancement being limited to masticatory muscles in MMM, and permit ruling out most differential diagnoses (Reiter 2001).

Conclusion: A confirmative diagnosis of MMM can be made if antibodies against 2M fibers in serum or immune complexes in masticatory muscles can be identified (Gilmour et al. 1992, Melmed et al. 2004).

References: Gilmour M.A., Morgan R.V. & Moore F.M. 1992. Masticatory myopathy in the dog: a retrospective study of 18 cases. J. Am. Anim. Hosp. Assoc. 28:300-306. - Melmed C., Shelton G.D., Bergman R. & Barton C. 2004. Masticatory muscle myositis: pathogenesis, diagnosis, and treatment. Comp. Cont. Ed. Pract. Vet. 26:590-604. - Reiter A.M. 2001. An unusual presentation of masticatory muscle myositis in a Brittany spaniel. Proc. 15th Annu. Vet. Dent. Forum, p.147-148. - Shelton G.D. & Cardinet GH. 1989. Canine masticatory muscle disorders, p.816-819. In: Kirk R.W. (ed.), Current Veterinary Therapy X. W.B. Saunders, Philadelphia. - Shelton G.D., Cardinet G.H. & Bandman E. 1988. Expression of fiber type specific proteins during ontogeny of canine temporalis muscle. Muscle Nerve 11:124-132. - Shelton G.D., Cardinet G.H. & Bandman E. 1987. Canine masticatory muscle disorders: a study of 29 cases. Muscle Nerve 10:753-766. - Shelton G.D., Cardinet G.H., Bandman E. & Cuddon P. 1985. Fiber type-specific autoantibodies in a dog with eosinophilic myositis. Muscle Nerve 8:783-790.

INDEX TERMS: Masticatory, myositis, 2M fiber, canine.

051. Reiter A.M. 2007. **Radical resection of oral and maxillofacial tumors – are there any limits?** *Pesquisa Veterinária Brasileira 27(Supl.).* Department of Clinical Studies, School of Veterinary Medicine, University of Pennsylvania, Philadelphia, PA 19104, USA. E-mail: reiter@vet.upenn.edu

Introduction: The treatment of choice for most oral and maxillofacial tumors is wide surgical excision. Large portions of upper and lower jaws and associated soft tissues can be removed without compromise of quality of life. Preoperative workup includes routine blood tests, blood type determina-tion and cross-matching, coagulation profiles, buccal mucosa bleeding time, regional lymph node aspirates, and diagnostic imaging (thoracic radiographs, abdominal ultrasound, head computed tomography). The client must be informed about intra- and postoperative complications, follow-up care, long-term function and quality of life, and prognosis. A biopsy should always be taken in a location that can be incorporated in the definitive resection. Histopathological examination allows the clinician to establish a diagnosis, formulate a treatment regimen, and give the owner a better prognosis. If the biopsy result does not correlate with the clinical findings, a second biopsy specimen is obtained. Surgical biopsy under general anesthesia and microscopic examination of a formalin-fixed specimen are more accurate than cytological techniques. Parotid, mandibular, and medial and lateral retropharyngeal lymph nodes should preferably be evaluated histologically. A negative lymph node biopsy does not preclude the possibility of regional metastasis, which may occur along perineural or vascular routes, or metastasis to other less accessible lymph nodes.

Literature Review: Conservative resection should be restricted to gingival hyperplasia and viral papillomas. Peripheral odontogenic fibromas (previously called fibromatous and ossifying epulides) are removed together with the tooth and its periodontium from which they arise. The practical limits for maxillectomy range from partial resection of the rostral upper jaw on one or both sides (rostral maxillectomy), a central or caudal portion of the maxilla (central or caudal maxillectomy), the entire dental arcade on one side including the palate to the midline (total maxillectomy) to the entire palate and both entire dental arcades. For more caudally located lesions that extend onto the side of the face, the bones forming the ventral and lateral limits of the orbit can be resected (partial orbitectomy). In cats the relatively

small size of the skull and the short, tighter upper lip compared with that of dogs make radical maxillectomy far more challenging. The practical limits for resection of the lower jaw range from partial resection of the mandible on one or both sides (unilateral or bilateral rostral mandibulectomy and partial mandibular body resection), one entire mandible (total mandibulectomy) to one entire mandible and a portion of the mandible on the other side. For caudally located lesions the mandibular ramus or a portion of it can be resected by means of a dorsolateral approach through the zygomatic arch and the masseter and temporal muscles. Bilateral rostral mandibulectomy to the level of the first premolars provides good function and esthetics. Bilateral resection caudal to this level results in progressively greater problems with tongue retention, eating and grooming. Resection of the symphysis causes the two remaining mandibular sections to 'float,' which is functionally and esthetically acceptable. Resection should include at least 1-2cm of apparently healthy tissue surrounding the tumor. The use of electrocoagulation along the incised mucosal edges that will be sutured is to be avoided. Bone is cut with power instruments (rotating burs; sagittal and oscillating saws) or an osteotome and mallet. It is often safer to 'break out' the piece to be resected than to bur or saw through any remaining bony attachments. The wound is closed with a buccal flap that is undermined until it can cover the defect without tension. In the case of maxillectomies, a two-layer closure is preferred, with the first layer apposing connective tissues of the flap and palate, to relieve tension on the epithelial edges. Lingual tumors are resected with good results if the resection can be confined to the free rostral or the dorsocaudal portions of the tongue. Clamping the tongue caudal to the excision site with non-crushing forceps greatly aids in control of bleeding. Surgical principles for resection of tumors of the lip and cheek include maintenance of a functional lip commissure so that the mouth can open adequately, separate closure of mucosal and skin incisions, avoidance of parotid and zygomatic salivary gland ducts or ligation of ducts when avoidance is not possible, and cosmetic closure of resulting facial defects by advancing or rotating tissue from the lower lip and side of the face, head or neck.

Discussion: Hemorrhage is controlled by means of digital compression or vessel ligation. Diffuse bleeding may respond to surface application of a mixture of phenylephrine/lidocain. Other hemostatic materials include gelatin sponges, thrombin, and polysaccharide beads. Dilute epinephrine is to be avoided. Unilateral carotid artery ligation is recommended if hemorrhage continues and cannot be controlled. After total mandibulectomy the opposite mandible will swing over toward the midline, which may result in the remaining mandibular canine tooth to impinge on the palate when the mouth is closed; to prevent this, the tooth is extracted or its crown surgically reduced. After more involved mandibulectomy procedures, the tongue will lose its ventral support and often hangs out of the mouth, resulting in drooling and chronic dermatitis. This can be partially corrected by rostral advancement of the lip commissure on one or both sides to form a fold that contains the tongue (commissuroplasty). Wound dehiscence 2 to 3 days after surgery usually results from tension on suture lines or compromised vascularity of flaps. Dehiscence of maxillectomy sites carries more serious consequences, as an oronasal defect may develop. Dehisced flaps are resutured after further undermining to eliminate tension. Closure of a chronic oronasal fistula should be performed after complete healing of surrounding soft tissues has occurred. Postoperative pain control is achieved with a combination of intraoperatively given longer-acting local anesthetics, centrally acting opioids, and NSAIDs. Patients undergoing radical resective surgery invariably benefit from placement of a transdermal fentanyl patch plus injectable opioid supplementation until the patch achieves adequate blood levels. Antibiotic treatment is not required after oral and maxillofacial surgeries in the otherwise healthy patient. Broad-spectrum antibiotics are given perioperatively in debilitated and immunosuppressed patients and those suffering from organ disease, endocrine disorders, cardiovascular disease, severely contaminated wounds and systemic infections. Water is offered once the animal has recovered from anesthesia. Soft food is offered 12-24 hours after surgery and maintained for about 2 weeks. Dogs usually eat the same or following day; cats may take several days to adapt. Cats may benefit from placement of an esophagostomy tube to ensure proper nutrition and medication during the immediate postoperative period. Chlorhexidine digluconate solution or gel (0.1-0.2%) is administered into the mouth for 2 weeks. Elizabethan collars, tape and nylon muzzles, or other restraining devices may be used in some animals to prevent disruption of the surgical sites. Displacement of a ligature is the most common cause of bleeding in the immediate postoperative period. Hemoclips should not be used to ligate significant vessels due to their tendency to fall off or tear the vessel. Reexaminations are scheduled at 2 weeks (removal of skin sutures) and at 2, 6 and 12, 18, and 24 months postoperatively. Collaboration with an oncologist is helpful after histopathological results return to discuss the need for further treatment (surgery, radiation therapy and/or chemotherapy). Palpation of nonresected lymph nodes (with cytological or histopathological examination of enlarged nodes) and thoracic radiographs should be performed to monitor for regional and distant metastasis.

Conclusion: Radical resective surgery often provides a cure in patients with oral and maxillofacial malignancy and is tolerated surprisingly well by dogs and cats. The quality of life provided by maxillectomy and mandibulectomy procedures is excellent. The multiple anesthesia episodes required for radiation therapy and the systemic sickness and multiple office visits required for chemotherapy are avoided. Combined therapy may be indicated, particularly for lesions with regional or distant metastasis.

References: Booth P.W., Schendel S.A. & Hausamen J.-E. 2007. Maxillofacial Surgery. 2nd ed. Churchill Livingstone, St Louis. – Harvey C.E. & Emily P.P. 1993. Small Animal Dentistry. Mosby-Year Book, St Louis.

INDEX TERMS: Oral, maxillofacial, tumor, mandibulectomy, maxillectomy.

052. Reiter A.M. 2007. **Update on the etiology of tooth resorption in cats.** *Pesquisa Veterinária Brasileira 27(Supl.).* Department of Clinical Studies, School of Veterinary Medicine, University of Pennsylvania, Philadelphia, PA 19104, USA. E-mail: reiter@vet.upenn.edu

Introduction: Feline odontoclastic resorptive lesions (FORL) represent the most common dental disease in domestic cats, affecting multiple if not all teeth.

Literature Review: The prevalence of FORL ranges from 25 to 75%, dependent on the diagnostic procedures applied. Disease below the gum line and along the root surface cannot be detected without the use of dental radiography or histological examination. There is no gender or breed predisposition, but prevalence increases with age (Reiter & Mendoza 2002). If resorption progresses into crown dentin, enamel may get undermined, and a pink discoloration is observed at the crown surface. FORL that emerge at the gingival margin were originally referred to as *neck lesions*. Exposure to the oral environment results in formation of inflamed granulation tissue. Such defects often are painful and bleed easily when probed with a dental instrument. Some cats show repetitive lower jaw movements, spontaneously or upon probing of the defects. Alveolar bone adjacent to *inflammatory root resorption* is also resorbed. The crowns of teeth with *dentoalveolar ankylosis* and *root replacement resorption* often break off, leaving resorbing root tissue behind (Reiter & Mendoza 2002). FORL develop anywhere on the root surface and not just close to the cementoenamel junction. Resorption often starts on the same tooth at various root surfaces simultaneously, progressing from cementum apically into root dentin, as well as coronally into crown dentin. Inflammatory root resorption has radiographically been categorized as *type 1 root lesion*, with unaffected root areas surrounded by a detectable periodontal space. Root ankylosis and replacement has been categorized radiographically as *type 2 root lesion*, with no or an inconsistently detectable periodontal space present (DuPont & DeBowes 2002). Attempts at repair include production of bone- or cementum-like material, but resorption usually continues until the roots are completely resorbed or the crown breaks off, leaving resorbing root tissue behind (Reiter & Mendoza 2002). A recent histological study of clinically and radiographically normal teeth from cats with FORL on other teeth revealed that the early FORL is non-inflammatory in nature. These teeth showed hyperemia, edema and degeneration of the periodontal ligament with marked fiber disorientation, increased osteoid formation along alveolar bone surfaces (*hyperosteoidosis*), increased cementum formation along cervical and apical root surfaces (*hypercementosis*), a narrowing of the periodontal space and areas of fusion between the tooth and alveolar bone (Gorrel & Larsson 2002). Because bone is in a constant state of remodeling, ankylosed teeth are at risk to be resorbed and replaced by bone. Many cats also show *abnormal tooth extrusion* and *alveolar bone expansion*. Both conditions are commonly observed in canine teeth and may occur together. Abnormal tooth extrusion leads to exposure of the root surface. Alveolar bone expansion causes a thickening of bone along the alveolar margin or the surfaces of alveolar plates (Reiter et al. 2005a).

Discussion: Tooth resorption is caused by odontoclasts, whose precursors derive from hematopoietic stem cells and migrate from blood vessels toward the external root surface. Mononuclear odontoclasts then fuse with other cells to become multinucleated mature odontoclasts, which are capable of resorbing tooth tissue. The vitamin D metabolite 1,25-dihydroxyvitamin D_3 [$1,25(OH)_2D_3$] is important in recruiting hematopoietic stem cells to become resorbing clastic cells (Reiter et al. 2005a). The etiology of FORL is unknown. The increased prevalence of FORL since the 1960s may not be due to increased awareness and improved diagnostic procedures, but could be associated with aspects of domestication, such as altered feeding practices. The diet represents the only source of vitamin D in cats which are unable to produce vitamin D in skin. About one third of commercial cat foods contain vitamin D in excess of maximal allowances, and a direct linear relationship exists between 25-hydroxyvitamin D (25OHD) concentrations in serum and dietary intake of vitamin D (Morris, 1996; Morris et al. 1999). Cats have also been reported with vitamin D toxicosis following consumption of commercial foods (Morita et al. 1995), showing decreased urine specific gravity and mineralization of various soft tissues, particularly kidneys and walls of large blood vessels. Cats with FORL were also reported to have significantly lower urine specific gravity and significantly higher serum concentration of 25OHD, compared to cats without FORL, though the means of both parameters remained within physiological range (Reiter et al. 2005b). The possibility of gradual impairment of renal function suggests that FORL might not have a local cause but could be manifestation of a systemic insult. Daily masticatory stress may be the reason why chronic increased vitamin D intake manifests sooner and is more pronounced in periodontal tissues compared to other soft tissues, and FORL may therefore occur prior to the development of obvious signs of vitamin D-induced systemic disease. Evidence for a possible role of vitamin D in the development of FORL comes from studies that evaluated the effect of administration of excess vitamin D or its metabolites in experimental animals. Changes of dental and periodontal tissues in these animals include periodontal ligament degeneration, hypercementosis, hyperosteoidosis, narrowing of the periodontal space, dentoalveolar ankylosis, and root resorption (Becks et al. 1946a,b, Moskow & Baden 1964, Ratcliff & Itokazu 1964, Bernick et al. 1971). Vitamin D-induced periodontal degeneration and alveolar bone expansion could result in coronal displacement of the gingival fiber apparatus and subsequent reduction of the *biologic width* (the dimension of space occupied by junctional epithelium and gingival connective tissue). Abnormal extrusion of teeth in cats with increased vitamin D activity may be a failed attempt at maintaining biologic width (Reiter et al. 2005a).

Conclusion: Extraction of affected teeth is the treatment

of choice. Crown amputation with intentional root retention may be utilized for ankylosed teeth and those with root replacement resorption. 'Pulverizing' roots with a round bur on a water-cooled, high-speed handpiece should be avoided, as serious complications can occur with this technique (Reiter & Mendoza 2002). If increased vitamin D activity proves to be the causative factor of FORL, feeding a diet less rich in vitamin D would be recommended.

References: Becks H., Collins D.A. & Axelrod H.E. 1946a. The effects of a single massive dose of vitamin D_2 (D-stoss therapy) on oral and other tissues of young dogs. Am. J. Orthod. Oral Surg. 32:452-462. - Becks H., Collins D.A. & Freytag R.M. 1946b. Changes in oral structures of the dog persisting after chronic overdosis of vitamin D. Am. J. Orthod. Oral Surg. 32:463-471. - Bernick S., Ershoff B.H. & Lal J.B. 1971. Effects of hypervitaminosis D on bones and teeth of rats. Int. J. Vit. Nutr. Res. 41:480-489. - DuPont G.A. & DeBowes L.J. 2002. Comparison of periodontitis and root replacement in cat teeth with resorptive lesions. J. Vet. Dent. 19:71-75. - Gorrel C. & Larsson A. 2002. Feline odontoclastic resorptive lesions: unveiling the early lesion. J. Small Anim. Pract. 43:482-488. - Morris J.G., Earle K.E. & Anderson P.A. 1999. Plasma 25-hydroxyvitamin D in growing kittens is related to dietary intake of cholecalciferol. J. Nutr. 129:909-912. - Morris J.G. 1996. Vitamin D synthesis by kittens. Vet. Clin. Nutr. 3(3):88-92. - Morita T., Awakura T., Shimada A., Umemura T., Nagai T. & Haruna A. 1995. Vitamin D toxicosis in cats: natural outbreak and experimental study. J. Vet. Med. Sci. 57:831-837. - Moskow B.S. & Baden E. 1964. The effect of chronic dihydrotachysterol overdosage on the tissues of the periodontium. Periodontics 2:277-283. - Ratcliff P.A. & Itokazu H. 1964. The effect of dihydrotachysterol on the teeth and periodontium. J. Periodontol. 35:320-325. - Reiter A.M., Lewis J.R. & Okuda A. 2005a. Update on the etiology of tooth resorption in domestic cats. Vet. Clin. North Am. Small Anim. Pract. 35:913-942. - Reiter A.M., Lyon K.F., Nachreiner R.F. & Shofer F.S. 2005b Evaluation of calciotropic hormones in cats with odontoclastic resorptive lesions. Am. J. Vet. Res. 66:1446-1452. - Reiter A.M. & Mendoza K. 2002. Feline odontoclastic resorptive lesions. An unsolved enigma in veterinary dentistry. Vet. Clin. North Am. Small Anim. Pract. 32:791-837.

INDEX TERMS: Odontoclastic, resorption, feline, FORL, vitamin D.

053. Rezende A. P.C., Rocha M.S.T. & Galera P.D. 2007. Making of intra-radicular nucleus and dental crown with acrylic resins reinforced by ribbond® tape on boxer bitch: case report.

Pesquisa Veterinária Brasileira 27(Supl.). Hospital Veterinário de Pequenos Animais da Universidade de Brasília, FAV-UnB, Brasília, DF 70910-900, Brazil. E-mail: protevet@hotmail.com

Introduction: Traditional root channel treatment is an alternative for teeth whose endodontic system is endangered due to pulpitis or fractures with or without pulp exposure (Gioso 2001, Leon-Roman et al. 2002). Extensive coronary destruction after endodontic treatment usually need intra radicular preparation prior to the setting of pins or cast nuclei that will serve as a support base for retention and fixation of coronary prostheses (Gomes et al. 1999, Leon-Roman et al. 2002, Leirião et al. 2003, Wanderley 2003). Both teeth that have undergone endodontical treatment and teeth prepared for nuclei formation may remain in the mouth cavity for varied periods until they are prosthetically restored, being their post-restoration durability long and effective (Gomes et al. 1999, Ribeiro et al. 2000).This report aims to assess the workability of an intra radicular nucleus and dental crown built on a Boxer bitch, making use of acrylic resins reinforced by heavy-duty interwoven polyethylene fibers.

Material and Methods: The experiment was made on an adult Boxer bitch that had suffered total fracture of the left lower canine tooth due to biting trauma. The fracture being located in the cervical region of the dental crown, with the presence of intense painless scarring reaction of clinic assessment and record, chronicity of a dental lesion was found.

Results: In virtue of a worsening clinic situation, endodontic treatment was carried out. The animal was laid in right lateral decubitus and the region of the fracture was exposed through gengivoctomy. The remaining root was endodontically treated. Twenty days after the treatment, the animal was sent back to surgery to get an intra radicular pin, a nucleus with autopolymerizable acrylic material, methylmethachrylate, chemically activated acrylic resin and a dental crown with photopolymerizable acrylic. Inlay material of the radicular canal was removed up to the depth necessary to the making of the intra radicular pin and removal of angles at the opening of the canal. Soon afterwards, a cut of the Ribbond® was made, longer than the depth of the canal and as high as the nucleus to be restored and acid conditioning of the canal walls with its rinsing and drying. After drying, autopolymerizable acrylic resin was injected into the canal. The Ribbond® tape was applied on it for compression to assure dense concentration. The animal was examined on a weekly basis for one month after 12 months from surgery. The prosthesis had been preserved with proper dental occlusion, to demonstrate the effectiveness of the technique.

Discussion and Conclusion: Among different alternatives to endodontic therapy and the choice for the most proper procedure, the peculiarities of the patient, duration of affection and clinical signs should be taken into consideration (Gomes et al. 1999, Ribeiro et al. 2000, Leon-Roman et al. 2002, Valle et al. 2003). In the above case a disinfectant penetration treatment or conventional canal treatment was used. This procedure is often employed to treat irreversible injury to the endodontic system in case of pulpar necrosis, usually together with endangerment of the periapical part of permanent teeth (Vasconcelos et al. 2001, Leon-Roman et al. 2002). The Ribbond® tape is produced from high molecular weight polyethylene and has as its main features inertia and biocompatibility (Simamoto et al. 2003, Ribbond® THM 2004). The combination of fiber and weave makes this tape ductile, no memory, and very useful in dental treatment on human beings (Gomes et al. 1999, Ribbond® THM 2004). The tips of the Ribbond® tape that were left out of the radicular canal on purpose were used with the help of the photopolymerizable acrylic resin for reconstruction of both the nucleus and a small dental crown to make better tape adherence to the resin after fixation in order to avoid its weakening. Aiming to reduce

prosthesis fracture and prolong its maintenance a dental crown smaller than the original one was made. Results from experimental conditions described above have led to the conclusion that the use of endodontic prosthesis through the technique of making intra radicular nuclei and dental crown is effective and feasible in veterinarian dental treatment.

References: Gioso M.A., Vianna R.S., Venturini M.A.F.A., Correa H.L., Venceslau A. & Araújo V.C. 2001. Análise clínica e histológica da utilização da resina acrílica autopolimerizável nas fraturas de mandíbula e maxila e separação da sínfise mentoniana em cães e gatos. Ciência Rural, Santa Maria, 31:291-298. - Gomes A.P.M., Oliveira L.C.; Camargo C.H. & Balducci I. 1999. Avaliação da infiltração marginal por corante em obturações de canais radiculares preparados para núcleo, em virtude do material de preenchimento ou impermeabilização do remanescente radicular. Revta Odontol. Unesp 28:147-160. - Leirião F.P., Brito L., Mory L. & Gioso M.A. 2003. Histological study of the periodontal structures, comparing gingival displacement by use of copper band and by cotton string, in dogs. Braz. J. Vet. Res. Anim. Sci. 40:382-388. - Leon-Roman M.A. & Gioso M.A. 2002. Tratamento de canal convencional: opção à extração de dentes afetados endodonticamente: uma revisão. Clín. Vet. 40:32-44. - Ribeiro R.A., Myaki S.I., Gioso M.A. & Araújo N.S. 2000. Pulpal response of dogs primary teeth to an adhesive system or to a calcium hydroxide cement. Pesq. Odontol. Bras. 14:47-52. - Ribbond® THM 2004. About us Ribbond®? http://www.ribbond.com. Acess in 19.11.2006. - Simamoto Junior P.C., Silva M.R., Mota A.S., Fernandes Neto A.J. & Martinez T.S. 2003. Avaliação da técnica ultra-sônica na remoção de pinos intra-radiculares em canais previamente estandardizados. XVI Jornada Odontológica de Bauru, São Paulo, p.238. (Resumo) - Valle C.V.M., Pinzan A. & Valle-Corotti 2003. O tratamento ortodôntico e o paciente periodontal: relato de um caso clínico. XVI Jornada Odontológica de Bauru, São Paulo, p.235. (Resumo) - Vasconcelos B.C.E, Filho J.R.L., Fernandes B.C. & Aguiar E.R.B. 2001. Dental reimplantation. Revta Cirur. Traumatol. Buco-Maxilo-Facial 1:45-51. - Wanderley M.T. 2003. Como tratar dentes traumatizados ou perdidos traumatismo em dentes decíduos e suas repercussões para as dentições. Anais 15º Conclave Odontológico Internacional de Campinas, São Paulo, p.142.

INDEX TERMS: Odontology, ribbond®, root canal therapy.

054. Ribeiro M.G. & Ribeiro L.V.P. 2007. **Main advanced techniques and indications of premolar and molar exodontias in equines**. *Pesquisa Veterinária Brasileira 27(Supl.).* DZO, College of Veterinary Medicine, State University of Maringá (UEM), Umuarama Campus, Umuarama, PR, Brazil. E-mail: mgrvet@bol.com.br

Introduction: Dental diseases in equines, especially those that affect the cheek teeth, are usually not diagnosed in time to avoid weight loss, decreased performance and sub-clinical diseases. As well as that, it is important to mention that dental abnormalities may also cause paranasal infections of the sinus, increased volume of the mandible and the maxilla, abscess formation, esophagi obstruction, colic and eventually the death of the animal. The most significant dental diseases in equines are infundibular necrosis and periapical lesions. Generally, these diseases have more severe consequences in equines than in men, and are more difficult to be treated when compared with similar conditions on domestic carnivores. In some cases endodontic therapy is possible, but usually extraction of the affected teeth is the norm. Extraction, however, when not carried out adequately, may bring some problems such as: alveolar infection, presence of bone fragments in the alveolus and bone sequestrum. These are just some examples of cases that may cause the formation of fistula, which may remain for many weeks or even many months on end (Baker 1982, Mueller 1991, Kirkland 1994, Gorrel 1997, Mueller & Lowder 1998).

Literature Review: Historically, equine cheek tooth removal has been thought of and referred to by many professionals in the area as unsophisticated surgery, leaving the impression among many in the profession that this work is beneath their level of expertise. This may, in part, account for the lack of progress in equine dental extraction techniques and the disgusting rate of postoperative complications reported in the literature. At any rate, dental exodontia via buccotomy with the cheek's lateral incision followed by alveolus lateral wall osteotomy with the exposure of the affected tooth is the technique of choice to gain access to the maxillary third premolar tooth or the mandibular premolar teeth. In the normal course, after the extraction, the vacant alveolus fills with a sterile hematoma. This blood clot, protected from oral contamination, is the framework for a vascularized bed of granulation tissue that migrates inward from the outside margins of the wound, filling the void left by the removal of the dental crown and roots. The mucosa of the oral cavity, paranasal sinus, nasal passages or skin adjacent to the wound migrates over the bed of granulation tissue and, along with wound contraction, covers the alveolus with a layer of epithelium to complete socket healing. Many factors, however, can delay or completely interrupt this healing process, causing long-term problems for the horse and in some cases the need for further corrective surgery. Therefore, for a long time, the necessity of more efficient bone defect reparation has motivated researchers interest in developing materials that present acceptable biological characteristics to be used as a surrogate to bone tissue. To be considered a bone replacement, a material must be compatible, non-antigenic, non-carcinogenic, of low cost, promote its slow replacement for bone tissue, and possess osteoconductor and osteoinductor properties. Compatibility is mainly related to the material's inertness, in other words, it must not produce or maintain inflammatory reaction for a extended period of time (Evans et al.1981, Baker & Easler 1999). Extraction by oral cavity: The first method of equines dental extraction was executed by oral cavity, having been practiced per centuries in animals with dental affection. For its accomplishment it was needed appropriate instrument, like oral speculum and forceps. The oral extraction is indicated in cases that need economic advantages, because it is not necessary general anesthesia, being able to be used for extraction of molar teeth, premolars, but especially for the incisors. This technique is more indicated in patient that presents teeth of supernumerary deciduous or aged due the small fang, being particularly recommended when there is indication of extraction of multiple teeth. The technique is

contraindicated in cases of evidence of serious dental caries or fracture, especially in aged patients, when the extraction can cause the break of the tooth and, consequently, the incomplete retreat. The oral extraction is less appropriate in cases that is present fistula between the tooth and the sinus, in sinusitis secondary to dental abnormalities where is indicated to realize a curettage of the alveolar, in cases of periapical infection of new animals and patients where there are the possibility of having more than 30 minutes of considerable work to extract the tooth. Extraction by repression: Repression or repulsion is the most used technique to dental extraction when there is compromising in the molar and premolar teeth. It can be used to the removal of the forth premolar tooth, first, second and third molars of the superior arched, all the premolars of the inferior arched and the second and third molars of the inferior arched, especially in cases of advanced caries and dental fractures, when the oral extraction is not possible. The main problem of the repulsion, the alveolar infection, that is associate to fragments leaved in the alveolar bone, and happens in 47% of the cases of superior tooth repression and 35% in others teeth. It is necessary a lot of careful in this procedure (Evans et al. 1981, Baker & Easler 1999,). Extraction by buccotomy: The technique of dental extraction involving the removal of the lateral alveolus, described for the first time by Merillat (1906), was modified by Evans, that incorporated buccotomy in order to obtain better exposition of the affected tooth, it was modified again by Ribeiro (2003), that realized a osseous window minimizing some undesirable effects of the traditional buccotomy, With the evolution of the sedatives and anesthetics, the surgeries procedures with general anesthesia have became more popular. The buccotomy is indicated to the extraction of the molars and premolars teeth of both arched (Evans et al. 1981, Dixon 1997, Gaughan 1998, Auer & Stick 1999, Baker & Easler 1999, Lowder 1999). Advances technician in the recovery after exodontia: Castor bean oil polyurethane is a bioactive non-toxic polymer with elasticity similar to the human bone. It is the result of the addition of two basic components: poliol and pre-polymer. Special techniques of urethane activation are used for the extraction of these two elements, both obtained by a modification of the castor oil, which is extracted from castor beans (*Ricinus communis*, dicotyledonous class, geraniaceous order, euphorbiaceous family). It has been recommended for the fixation of prostheses, and the reconstitution and filling of bone and alveolar spaces. Castor oil resin implants of different forms and sizes have already shown to be biocompatible in different experimental conditions: intra-bone and intra-articulations in rabbits, in the alveolus of rabbits, in the alveolus of rats, in the anterior chamber of mice, in subcutaneous dorsal implants in rats, in the cornea of rabbits, as partial replacement for the common calcaneum tendon in rabbits, in *in-vitro* biocompatibility, in the reconstruction of bone defects in humans, and in bone defects in dogs , and in alveolus of equines after extraction of the mandibular third premolar tooth. Other studies have also stated that the polyurethane derived from castor oil is a new biomaterial for the filling of bone defects or bone loss, as there is a gradual replacement of this polymer by neoformed bone. Azevedo et al. (1997) in three cases of use of castor oil polymer membrane in guided bone regeneration in defects around osteointegrated implants in humans, concluded that the castor oil polymer contributed to bone healing. In addition to that, castor oil polyurethane used in the reconstitution of bone defects has been demonstrated to be biocompatible and have osteointegrating action. In a histological study, after exodontia and poliuretana of castor bean implanted in the alveoli of the third inferior premolar of 8 equines and biopsy after 120 days, the author discloses that histological analysis of the material that filled the alveoli showed that it is constituted, in its larger part, of compact or trabecular osseous or mature fibrous connective tissue. In none of the animals, inflammatory reaction was proven directly in the presence of the poliuretana remaining portions. The author concludes that poliurertana of the castor bean is inert, biocompativel, and when implanted in the alveolar socket, it results in osteointegration and assists the fulfilling of the osseous alveolar socket tissue (Ribeiro 2003). Use of Methyl-methacrylate and Acid Conditioning: The technology of the adhesives progressed a lot in the last 25 years, due the use on a large scale and stimulated by ample application in the aerospace and automotive industries. These investigations contributed notably to the development of studies in the odontological area. In 1955, Buonocore developed a simple technique to unite acrylic resins the surface of the human enamel. The acid attack and the simple and composed resins initially were proposed to seal fissures. Currently they are used for estoration of cavities, topic fluorine application and cementation. The acid attack is made with an acid phosphoric solution on the enamel, in order to create micro-porosities for the penetration of fluid resins which, after polymerization, propitiate retention and marginal sealing. Basically, the technique of acid conditioning consists in the application of ortho-phosphoric acid at the concentration of 30-50%, during 1 or 2 minutes, on the enamel external surface. The acid acts in selective way on the prismatic structure of the enamel, promoting a preferential dissolution of the prisms head center or the periphery, when originates a surface rich in micro-porosities. The product of the enamel dissolution by the acid is a soluble salt that must be removed with water or air, in order to let the resins penetrate in the micro-porosities and polymerize this site. This procedure make possible that the polymerized resins stay mechanically restrained in the enamel. The factors that determinate the quality of the acid conditioning of the enamel are characteristics of the enamel surface; enamel type, acid type used, acid concentration, duration of application, and way of acid application. Resuming, the enamel should as clean as possible, the phosphoric acid must be used in a concentration of 30-50%, and must remain at least per one minute. It is also indicated that the ortho-phosphoric acid at 36%, remaining generally about 15 seconds in dogs, must be increased in aged animals. In the end of the acid attack technique the tooth must be washed abundantly per 20 seconds and dried with compressed air. The acrylic resins of methyl-methacrylate, in

the veterinary medicine, are used especially in reconstructed and orthopedic surgery, for orbital prosthesis in dogs, for reparation of the mandibular and maxilla fractures of dogs and cats; in oro-nasal fistulas in dogs, for facial reconstitution and reparation of the lumbar vertebra fracture in dogs. These resins are classified as resins of type I, they are found in powdered (polymer) and liquid (monomer) form and its mixture forms the methacrylate of the methyl product or methyl-methacrylate. The mixture of the two materials forms an exothermic reaction that polymerizes the product and "hardens" the material. In horses, the methyl-methacrylate is very much used in the reconstitution of cranium, maxilla and mandibular fractures. The resins must be used intra-orally. To minimize the effects of the temperature produced in the moment of drying of the acrylic methyl-methacrylate resins due to the exothermic reaction, a surgery compress soaked in physiologic solution must be used. By this way tissue alteration is not observed adjacent to the acrylic resins, besides the one that results from accumulation of alimentary residues (Gioso 2003, Ribeiro 2003).

Discussion and Conclusions: The oral cavity of equines must be always examined in the search of some dental affection. When one chooses to extract the affected tooth, it should be done with care, because there are several complications after an inadequate dental extraction as hemorrhage, wrong removal of the tooth, damage to adjacent structures as para-nasal sinus, alveolar bone, adjacent tooth, naso-lachrymal duct, salivary parotitic duct and facial nerve. Complications associated with the surgical wound include wound dehiscence, permanent formation of a fistula following incomplete removal of the tooth, osseous sequester, infection of the gingiva and presence of a range body.

References: Aguiar M.C.M., Navarro F.L., Ishikiriama A., Galan Junior J., Mondelli J. & Lopes E.S. 1975. Efeito do ataque ácido na retenção de restaurações de resina acrílica e resina composta. Estomatologia e Cultura 9(2):213-219. - Auer J.A. & Stick A. 1999. Equine Surgery. 2nd ed. W.B. Saunders, London, p.936. - Baker G.J. 1982. Dental disorders in the horse. Contin. Educ. 4(12):507-514. - Baker G.J & Easley J. 1999. Equine Dentistry. London: W.B. Saunders, London, p.278. - Dixon P.M. 1997b. Dental extraction and endodontic techniques in horses. Contin. Educ. 19(5). - Dixon P.M. 1997a. Dental extraction in horses: Indications and preoperative evaluation. Contin. Educ. 19(3). - Evans L.H, Tate L.P. & Ladow C.S. 1981. Extraction of equine 4th upper premolar and 1st and 2nd upper molar through a lateral buccotomy. Proc. 27th Annu. Meet. Am. Assoc. Equine Pract., New Orleans, Louisiana, p.249. - Gaughan E.M. 1998. Dental surgery in horses. Vet. Clin. North Am. Equine Pract. 14(2):381-397. - Kirkland K.D., Marretta S.M., Inoue O.J, & Baker G.J. 1994. Surgery of equine dental disease and associated oral pathology. Proc. 40th Annu. Meet. Am. Assoc. Equine Pract., Vancouver, p.119-120. - Gorrel C. 1997. Equine dentistry: evolution and structure. Equine Vet. J. 29(3):169-170. - Lowder M.Q. 1998. Tooth removal, reduction and preservation, p.245-254. In: White N.A. & Moore J.N. (ed.), Current Techniques in Equine Surgery and Lameness. W.B. Saunders, Philadelphia. - Merillat L.A. 1906. Equine dentistry and diseases of the mouth. Tooth removal. In: O'Connor J.J. (ed.), Veterinary Surgery. Vol.1. Alex Eber, Chicago. - Mueller O.E. 1991. Equine dental disorders: cause, diagnosis, and treatment. Contin. Educ.13(9):1451-1460. - Mueller O.E. & Lowder M.Q. 1998. Dental sepsis. In: Gaughan E.M. & DeBowes R.M. (ed.), Dentistry. Vet. Clin. North Am. 14(2):349-363. - Ribeiro M.G. 2003. Avaliação clínica e histológica do implante de poliuretana de mamona (*Ricinus communis*) no espaço alveolar após exodontia do terceiro pré-molar inferior: estudo experimental em eqüinos. Tese de Doutorado em Cirurgia Veterinária, Faculdade de Medicina Veterinária e Zootecnia, Universidade de São Paulo, São Paulo. 94.p. - Gioso M.A. 2003. Odontologia para o Clínico de Pequenos Animais. I Editora, São Paulo. 202p.

INDEX TERMS: Techniques of exodontias, equine, dentistry.

055. Rocha L. 2007. **What can be done, using marketing techniques, to increase the acceptance of you recommendation to your clients**. *Pesquisa Veterinária Brasileira 27(Supl.).* Dental Pet Mobile Services. 5241 SW 132 Avenue Miramar, FL 33027 USA 33027. E-mail: DentalPet@aol.com

Introduction: Many veterinarians are able to perform different procedures in the area of veterinary dentistry. This lecture shows you how different techniques can increase the acceptance of your recommendations, such h as digital photography, videos, brochures, telephone conversation, report preparation and others.

Literature Review: Marketing in the veterinary dentistry, is an area that have been growing fast in the last several years. There are many published papers in the Veterinary community, Veterinary dental Community, as well as in the general marketing. The author used the literature from the Veterinary Dental Forums and North American Veterinary Conferences.

Discussion: The first contact with your client, either a referral or your regular client, is usually by a phone call through the receptionist. It is imperative that this experience goes smoothly. If the receptionist is not well trained to answer these calls, the client should be transferred to someone well trained, so your clients can receive the proper information. Most owners have similar questions:

- How much is it going to cost?
- Do you have to put my pet under general anesthesia? I heard general anesthesia is very risky.
- Will my pet be able to go home the same day?
- Will my pet be able to eat after the procedure?

If this first call doesn't go well the client may not come for a consultation. Efforts are made to bring the patient for an office visit. The most common mistake at this point is to give the owners more information than they need, such as creating different scenarios of possible diagnosis and treatment. Some clients are very concerned with the cost of the treatment. The answer for the concern is always, "we don't know, but we will be more than happy to fax or e-mail our fee list", the office visit is US$ x.xx and we need anesthesia, blood work, oral x-ray, etc. As clients enter in the clinic for the first time, they should have a positive customer experience:

- Clean parking lot, free of dog excrements.
- Well-trained and friendly staff.
- A TV playing Animal Channel (or something similar), if not, a soft music.
- Poster/photos should be framed.
- Water and coffee available.

After the check-in by the receptionist, a technician gets the basic information (history, weight, temperature, etc.); play a video, if you have one regarding the problem they came for. The veterinarian introduces him or herself saying the first and last name and shake hands. Say Hello to the client and pet. Get more history if necessary. Oral examination is done. Use magnifiers to get a better view of the problems. Take digital pictures, or use a Polaroid camera. Show them to the client by putting them on the screen of the computer in the room (if you don't have a computer in the room use a laptop). Give the picture to the client to take home or e-mail them. Show brochures, literature (books, magazines, and articles). Show different cases, either in the computer or photo paper. In addition, a complete physical examination should be done. Plan to expend at least 20-30 minutes with this client; usually it takes twice the amount of time or more in a regular general practice consultation. - Clients need to sign permission for the procedure, which itemizes everything that is going to be done. Some of the procedures should have a canned estimate, for example a root canal, crown, orthodontic care etc. Give the client a rough estimate in the room, so the client doesn't have a surprise when the receptionist handles the estimate. Treatment plan for periodontal disease can only be given after oral x-rays and examination under anesthesia. If there are any issues regarding payment for the initial workup, arrangements are done with someone in the front desk. Payment plans such as Carecredit helps clients that can't afford treatment. - Call the client when the treatment plan is ready. The best person to call is the veterinarian who can medically explain the problems, the focus should be on what is best for the patient, don't let yourself to be intimidated by the bill. You have to offer what is best for your patient. Give all your recommendations and at the end tell how much it will cost. Get pictures before, during and after, be careful with pictures that may be too graphic. Some clients may not handle it well. - After the animal is awake, is time to do a "go home report", which should include several pictures with a brief description of what was done. Make sure the patient is well awake, as the owner does not want to take home a pet that is half asleep. Dry and brush the patient's face. - When the owners come to get the patient, give them the "go home report" while they are in the receptionist area. It's always good if other clients see the report as well. Talk to the owners without the patient, explain any questions that they may have and give written instructions. - To finalize the day call the client before 9:30PM to make sure everything is going well.

Conclusions: Those techniques described work in different clinics as well as in mobile dental services. Proper equipment and training is a must. Remember an excellent stuff and a team spirit is fundamental.

References: Beckman B. 2002. Maximizing client compliance with digital imaging. Proc. 17th Annu. Vet. Dental Forum, San Diego, CA, p.65. - Bellows J. 1999. Small animal dental equipment, materials, and techniques. 1st ed. Iowa State University Press, Ames. – Bellows J. 2007. How to Overcome Client Dental Objection. NAVC Press, Orlando, FL. - Bellows J. 2007. Creating a Five-Star Dental Practice. NAVC Press, Orlando FL. - Pannekkoek S. 2005. Proc. IX World Vet. Dental Congr., Orlando, FL, p.385-389.

INDEX TERMS: Marketing, veterinary dentistry.

056. Roscoe M.P., Alves G.E.S, Pagliosa G.M., Schwarzbach S.V., Leal B.B., Bordin A.I., Faleiro, R.R., Araújo D.K.G. & Lima J.T.M. 2007. **Evaluation of six sedative protocols aiming to permit dental procedures in standing horses.** *Pesquisa Veterinária Brasileira 27(Supl.).* Departamento de Clínica e Cirurgia Veterinária, UFMG, Belo Horizonte, MG 31270-901, Brazil. E-mail: marcelaroscoe@yahoo.com.br

Introduction: The domestication of the horse changed its feeding habits and diet, having an influence in the increasing frequency of abnormal dental wear. The oral and dental physical health is a vital condition to the horse vitality, performance and longevity (Pagliosa et al. 2006). To perform dental exams and treatments, the efficient chemical restrain of the horse is an essential need. During the sedation the horse must remain standing and, although slight ataxia is acceptable, a motionless horse is the ideal (Taylor 1985). The association of opioids and sedatives is a routine practice. Muir (1991) defined the primary reasons for association of two or three drugs together to produce standing chemical restraint in horses as to increase sedation or enhance analgesia, increase muscle relaxation and prolonged duration of action can also occur.

Materials and Methods: Five geldings were sedated in random order on separate occasions at least seven days apart. The animals were restraint in stocks and were administered: medetomidine (MD) (0.01mg/kg iv), xylazine (X) (1.0mg/kg iv) alone or xylazine (1.0mg/kg iv) followed immediately by butorfanol (XB) (0.01mg/kg iv) or pethidine (XP) (1.1mg/kg im) or tramadol (1.0mg/kg im) (XT) or fentanil (XF) (0.001mg/kg iv). The variables studied were: *restlessness score, ataxia score, head position, respiratory rate; heart rate (HR), mucous membranes collor, refill time; mouth speculum reaction, tongue tonus, pain sensibility of the periodontum, water stimuli, power dental float auditory stimuli (before introducing in to the mouth) and e power dental floating the tooth tissues*. Ataxia was also measured by time in minutes. The inspection and physical examination variables were measured ten minutes before (T0) and every ten minutes (T1 to T5) after the drugs administration, with total time of 50 minutes. The dental procedures variables were measured every ten minutes after the drugs administration until the mouth speculum was removed (T1 to T4), with total time of 30 minutes. The Friedman and Tukey tests were used to compare treatments statistically ($P < 0.05$).

Results: The ataxia began 2.00 ± 0.53 minutes after the drugs administration. In the X, XB and XP treatments T0 and T1 had different ataxia scores. The mean ataxia time was 36.10 ±3.35 minutes. The treatments XP and MD produced different times of ataxia, being the XP the longest (43.40 ±11.84) and MD the shortest (23.80 ±15.51). The treatments X and XP induced lower respiratory rate at T1, compared to the XB treatment. The smallest respiratory rate was found in T1 of

XP (6.40 ±2,19 mov./min.) and the biggest in T0 of XB (19.04 ±5,46 mov./min). No difference was found to all dentistry procedures studied. Clinically the XP treatment resulted in higher degree of tongue relaxation and less response to power dental floating to the tooth tissues, although these results were not statistic significant. This fact can be related to the small group size.

Discussion and Conclusions: Was concluded that all the sedation protocols used in this study were effective to promote sedation and analgesia in horses necessary to dentistry procedures in standing position, for about 30 minutes. The collateral excitatory effect caused by the administration of iv pethidine in horses reported by Clark & Paton (1988), Clutton (1987) and Alexander & Collett (1974) were not observed, problably due previous administration of xylazine and the use of im route, slowing down the absorption of the pethidine and affording more time to the sedative take action. Compared to all the protocols studied, XP produced more ataxia time compared to the MD, although this effect did not hinder the dental procedures and the duration of the ataxia was clinically proportional to the other sedative effects. None of the protocols caused danger cardio-circulatory effects. The X and XP protocols caused more respiratory depression compared to the other treatments. The tramadol (1,0mg/kg im) can be used after xilazina (1.0mg/kg iv) to produce neroleptanagesia in horses, but its antagonist $á_2$-adrenenoreceptor effect described by Faron-Gorecka et al. (2004) and Berrocoso et al. (2006) in rats, can reduce the sedative effects of xylazine when administrered together.

References: Alexander F. & Collet R.A. 1974. Pethidine in the horse. Res. Vet. Sci. 17(1):136-137. - Berrocoso E., Mico J.A. & Ugedo L. 2006. *In vivo* effect of tramadol on locus coeruleus neurons is mediated by alpha2-adrenoceptors and modulated by serotonin. Neuropharmacology 51(1):146-153. - Clark K.W. & Paton B.S. 1988. Combined use of detomidine with opiates in the horse. Equine Vet. J. 20(5):331-334. - Clutton R.E. 1987. Unexpected responses following intravenous pethidine injection in two horses. Equine Vet. J. 19(1):72-73. - Faron-Gorecka A., Kusmider M., Inan S.Y. et al. 2004. Effects of tramadol on alpha2-adrenergic receptors in the rat brain. Brain Res. 1016(2):263-267. - Muir W.W. 1991. Standing chemical restraint in horse, p.247-281. In: Muir W.W. & Hubbel J.A.E. (ed.), Equine Anesthesia: monitoring and emergency therapy. Mosby, St Louis. - Pagliosa G.M., Alves G.E.S. & Roscoe M.P. et al. 2006. Odontologia eqüina: alterações dentárias freqüentes que podem prejudicar a sanidade e performance do cavalo. Revta Bras. Med. Eqüina 1:6-12. - Taylor P.M. 1985. Chemical restraint of the standing horse. Equine Vet. J. 17(4):269-273.

INDEX TERMS: Horse, sedation, dentistry.

057. Rossi Jr J.L. 2007. **Main oral illnesses in great neotropicals felids in captivity and free ranging in Brazil.** *Pesquisa Veterinária Brasileira 27(Supl.).* Laboratory of Comparative Dentistry, Surgery Department, FMVZ-USP, São Paulo, Brazil. E-mail: vetjrossi@gmail.com

Introduction: Species as the jaguar (*Panthera onca*) and puma (*Puma concolor*) have an accentuated decrease in their populations due to the indiscriminate hunt associated with the loss of the main ecosystems where they are inhabitate. One of the aspects of this problem that has frequently been accentuated is the constant attacks of these species to domestic animals of economic importance as cattle, sheep ands horses. It happens because, with the expressive reduction of the wild populations, these predators have to satisfy their nutritional needs attacking domestic stocks. It is aimed to compare the conditions of the stomatognathic system of free ranging *Panthera onca* and *Puma concolor* originating from areas of Pantanal, Amazon Forest, and Brazilian Atlantic Forest.

Materials and Methods: A total of 42 jaguars (*Panthera onca*) and 36 pumas (*Puma concolor*) belonging to Zoos and Forests of the State of São Paulo, with ages varying from six months to 25 years of age, born or not in captivity were studied. They ranged in age from 6 months to 25 years. We studied also 4 individuals of *Panthera onca* and 4 of *Puma concolor*, with estimated age varying between 6 months to 8 years, that were captured in Fazenda Sete, city of Miranda, State of Mato Grosso do Sul, in the South Pantanal, which were free-wild animals. One animal was captured in Atlantic Forest, city of Viçosa, State of Minas Gerais, and one jaguar captured in the Amazon Forest, city of Jacareacanga, State of Pará. The methodology used for all the animals, whether kept in captivity or not, was to administer an injectable general anesthesia, perform a physical examination and an oral examination, document the clinical findings in dental charts, and photograph and film all the studied animals.

Results: All animals kept in captivity presented some type of oral disease, varying from light to severe, that might have resulted in varying degrees of injury to the stomatognathic system. Abnormalities included: failure in dental eruption, anatomical defects of teeth, dental wearing, malpositioning of teeth, dental mobility, dental trauma, caries, odontoclastic resorptive lesion, periodontal disease, and oral manifestations of viral disease (Table 1, 2 and 3).

Table 1. Prevalence of oral lesions in captive jaguars (*Panthera onca*)and pumas (*Puma concolor*) in the State of São Paulo, Brazil

Oral lesion	Prevalence in *Panthera onca*[b]	Prevalence in *Puma concolor*[c]
Bacterial plaque[a]	3 (7.14%)	0%
Gingivitis	21 (50%)	12.55%
Dental calculus	42 (100%)	83.33%
Furcation exposure	6 (14.28%)	4.16%
Dental mobility	0 (0%)	8.33%
Gingival recession	6 (14.28%)	16.66%
Periodontal pocket	14 (33.33%)	12.50%
Dental wearing	35 (85.71%)	70.83%
Dental staining	5 (11.90%)	8.33%
FORL	12 (28.57%)	4.16%
Dental fracture	32 (76.19%)	58.33%
Pulp exposure	18 (42.85%)	12.50%
Caries	0 (0%)	4.16%
Gingival hyperplasia	3 (7.14%)	4.16%
Malocclusion	20 (47.61%)	0%
Dental absence	14 (33.00%)	20.83%
Oral ulcers	0 (0%)	16.64%
Total	42	30

[a] No staining solution used, [b],[c] Number of cases and percentage.

Table 2. Prevalence of oral lesions in wild jaguar (*Panthera onca) captured* in the Atlantic Forest, State of Minas Gerais, Brazil

Oral lesion	Classification of the oral lesions according to severity and location [a]
Gingivitis	Grau II na região do dente CSD e Grau I no 4 PMSD
Dental calculus	Degree II at RUCT region and degree I at RUFPT, Degree I at RUCT region and degree II at RUFPT
Gingival recession	3 mm recession at the mesial aspect of LUCT
Dental wearing	Teeth cuspids: LUCT, RLCT, LI (all incisiors)
Dental fracture	Cuspids of RUCT and LLTC
Pulp exposure	RUCT and LLCT, with tertiary/reparative dentine

[a] Right upper canine teeth (RUCT), Left upper canine teeth (LUCT), Lower incisor (LI), Right lower canine teeth (RLCT), Left lower canine teeth (LLCT), Right lower canine teeth (RLCT), Right upper fourth premolar teeth (RUFPT), Right lower molar (RLM).

Table 3. Prevalence of oral lesions in wild jaguar (*Panthera onca) captured* in the Amazon Forest, State of Pará, Brazil

Oral lesion	Classification of the oral lesions according to severity and location [a]
Bacterial plaque[b]	Degree I at RUCT region
Gingivitis	Degree I at RUCT and RUFPT region
Dental calculus	Degree I at RUCT and RUFPT region
Gingival recession	3 mm recession at the vestibular aspect of RUCT and LUCT
Dental wearing	Cuspids of canine, premolar and molar teeth
Dental fracture	Cuspid of RLCT and longitudinal fracture of RLMT
Pulp exposure	RUCT with deposition of terciary dentin
Malocclusion	Lower incisors with cranio-caudal displacement

[a] Right upper canine teeth (RUCT), Left upper canine teeth (LUCT), Right upper fourth premolar teeth (RUFFT), Right lower molar (RLM), [b] No staining solution used.

Discussion and conclusion: All these diseases could result in the affected individuals suffer an altered homeostasis and possibly death. The syndromes and diseases found seem to be associated with the living conditions to which these individuals were submitted (stress, nutritional imbalance, dietary texture, or environmental adaptation). The animals captured in free wild life presented subtle degrees of oral diseases that did not compromise the function and health of the stomatognathic system, however we do not know if these diseases can develop throughout their lives.

References: Rossi Jr J.L., Silva J.C.R., Marvulo M.F.V. & Gioso M.A. 2000. Prevalência de doença periodontal em onça-pintada (*Panthera onca*) e suçuarana (*Puma concolor*) mantidas em cativeiro no Estado de São Paulo. IV Congresso e XI Encontro da Associação Brasileira de Veterinários de Animais Selvagens, Águas de São Pedro, São Paulo. - Gioso M.A., Silva J.C.R., Marvulo M.F.V. & Rossi Jr J.L. 2000. Prevalência de fratura dental em onça-pintada (*Panthera onca*) e suçuarana (*Puma concolor*) mantidas em cativeiro no estado de São Paulo. IV Congresso e XI Encontro da Associação Brasileira de Veterinários de Animais Selvagens, Águas de São Pedro, São Paulo. - Rossi Jr J.L. & Gioso M.A. 2001. Prevalência de desgaste dental em onça-pintada (*Panthera onca*) e suçuarana (*Puma concolor*) mantidas em cativeiro no Estado de São Paulo. I Congresso Paulista de Clínicos Veterinários de Pequenos Animais, Anclivepa-SP., Águas de Lindóia, São Paulo. - Rossi Jr J.L. & Gioso M.A. 2001. Prevalence of oral lesions in *Puma concolor* and *Panthera onca* in the state of São Paulo, Brazil. 15th Annual veterinary dental forum, Texas, USA. - Rossi Jr J.L. & Gioso M.A. 2003. Comparative study and prevalence of periodontal disease in *Panthera onca* keept in captive and in wild life, Congresso Mundial de Odontologia Veterinária, Japão. - Rossi Jr J.L. & Gioso M.A. 2003. Avaliação estomatognático de *Panthera onca* em vida livre na Amazônia. Anais VII Congresso e XII Encontro da Associação Brasileira de Veterinários de Animais Selvagens, Águas de São Pedro, São Paulo. - Rossi Jr J.L. & Gioso M.A. 2003. Estudo comparativo sobre prevalência de doença periodontal em *Panthera onca* mantidas em cativeiro e em indivíduos de natureza. Anais VII Congresso e XII Encontro da Associação Brasileira de Veterinários de Animais Selvagens, Águas de São Pedro, São Paulo.

INDEX TERMS: *Felidae,* jaguar, puma, animal handling, captivity animals, animals at extinction, stomatognathic system, diseases, mouth, biologic conservation.

058. Rossi Jr J.L. 2007. **Ramphothec repair in birds and shell damage in chelonians**. *Pesquisa Veterinária Brasileira 27(Supl.).* Laboratory of Comparative Dentistry, Surgery Department, FMVZ-USP, São Paulo, Brazil. E-mail: vetjrossi@gmail.com

Introduction: The birds and chelonians are different on several physiologic aspects of mamiferos. Injuries in the ramphotheca of these animals or in the chelonian shell can cause problems in homeostasis, difficulties in food apprehension and locomotion. The early diagnosis and a fast clinic and surgical intervention are necessary for the treatment success.

Literature Review: The beak of birds is a dynamic structure in constant growth, constituted by upper bones, the maxilla (pre-maxilla and nasal bone and lower jaw, covered by keratinized epidermis, denominated ramphotheca (Ritchie et al. 1994, Rupley 1999). Other structures also compose the beak as nervous-vascular bunches, articulations and germinative sheathes (Rossi et al. 2005). Anatomically, the ramphoteca is subdivided in rhinotheca (upper) and gnatotheca (lower) (Rupley 1999). The mucosa of the oral cavity and of the tongue the birds is covered by stratified epithelium and the keratinization degree varies according to the location of the epithelium in the oral cavity (Rossi et al. 2005). The consistency of the ramphoteca varies among the species. It is strong in Psittaciformes (parrots, parakeets and macaws) and soft and flexible in Anseriformes (geeses) (Rossi et al. 2005). The ramphoteca can be considered as horny stratum of the beak and the derm is well vascularized and connected to the periosteum. Trauma or necrosis of the derm can frequently result in lesions that induce deformities of the beak (Ritchie et al. 1994). The ramphoteca has several functions in different species of birds, as food apprehensions, preparation of the food for deglutition, defense and attack, social and sexual interaction, locomotion and construction of nests (Ritchie et al. 1994, Rupley 1999, Rossi et al. 2005). The growth of keratin of the beak happens whenever there is a underlying germinative layer (attached to the periosteum, but the incremental growth in the direction of tip of the beak (Getty 1989). The time of replacement of keratin of the ramphoteca

is intimately linked to the use of the beak. In great macaws the complete substitution of the ramphoteca happens in approximately six months, while in the *Ramphastidae* there is an approximate growth rate of 0.5cm in a period of two years (Rossi et al. 2005). The keratin of the gnatotheca is usually substituted two to three times faster than the rhinotheca (Rossi et al. 2005). Several portions of the digestive system of the birds, including the beak, they are adaptative modifications in function of the diet. The size of the beak is an important factor in the regulation of the ingested food, showing that birds present great difficulties in consuming larger or smaller alimentary items than the anatomical dimension of the beak, having a direct relationship between the anatomy of the beak and the alimentary preference of each species (Rossi et al. 2005). Studies state that the alimentary preference for items of different sizes can occur in function of the age of the bird, in agreement with the size of the beak, and not of the chemical composition of the food (Getty 1989). In the birds, the oral cavity and the pharynx connect to form the oropharynx. The orofaringe communicates with the nasal breasts through the medium fissure in the palate, called choana. There are several papilas caudally located, associated to the choana. The glottis is located directly behind the tongue, and the birds do not have epiglottis (Rupley 1999). The tongue of the Psittaciformes is muscular and blunt. Most of the Passeriformes (little birds) present a narrow and triangular tongue, and the color varies from white to black, depending on the species involved (Ritchie et al. 1994). The oropharynx is covered again by a stratified epithelium which keratinized in the areas subject to abrasion. There are several salivary glands that secrete mucus at the oropharynx coat. Those glands can suffer metaplasis the cases of vitamin A deficiency, resulting in formation of cists filled with keratin and residues, which can be infected (Rupley 1999). To accomplish the physical exam of the oral cavity, it is necessary that the bird it remains contained appropriately. This is particularly important because it is possible to worsen the lesions in the ramphoteca at the moment that the bird is contained inside the cage or enclosure. Once contained, the mouth is opened using a speculum for birds or a gauze is placed in the gnatotheca and rhinotheca (Ritchie et al. 1994). Werther (2004) describes the following questionnaire for the accomplishment of the inspection of the beak in birds:

- are colors characteristics for the specie involved and age group? In some species the beak changes its colors with ageing.
- are there presence of necrotic areas, wounds, cracks, fractures, perforations?
- is there beak bleeding?
- is there lesion in the horny layer when the animal tries to open the beak?
- is the excessive growth of the beak extension?
- is there irregular or accentuated growth on one side than on the other?

The same author suggests the following questionnaire and observations during the physical exam of the oral cavity of the birds:

- Which is the coloration of the mucosa? Hiperemic? Anemic? Cyanotic?
- Tongue: shape and color (they also vary among species).
- Internal surface of the cavity (to verify the presence of masses, tumors, swelling and parasites).
- Larynx (to verify coloration and presence of swelling).
- Choana (to verify if there is obstruction, swelling, foreign bodies, fowlpox, wounds).

The variation of congenital and acquired defects can interfere in the normal function of the beak. In Galliformes (peacock, curassow, *Penelope sp.*), the rhinotheca deformity can be associated to embryogenic deficiencies of acid folic, biotin and pantothenic acid. Examples of acquired problems include malformations or necrosis of the beak, including perforations, lacerations, cracks and avulsions. Traumatic fractures, especially of the jaw frequently happen in Psittaciformes that get caught in hooks suspended in the roof of the cage or as a result of figth (Ritchie et al, 1994). In this last case, it is observed that the incidence of fractures of Psittaciformes beak is larger during the months of Spring and Summer, due to the reproductive behavior of the animals. During the courting, if the male is aggressive, the female is not skilled and associated to these factors, the enclosure is small, and the female is available to escape from the courting. The male, by trying to hold the female, uses too much force and then the fracture of the female beak happens. Ford (1998) reports that prey birds in nature have their beaks worn down naturally because of the habit of hunting and ingesting preys (in some cases the bird partially removes flesh from the prey and the attrition of the beak against the bones causes the wearing). In captivity, the beak tends not to wear away and the animal needs aid for that. The abnormalities of the beak may happen as a result of deficient nutrition; non-appropriated incubation; viral, bacterial, fungal and parasitic infection and traumas[2]. Those factors can cause exaggerated growth of the beak, rhinotheca and gnatotheca ("scissors beak"), shortening of the superior beak ("relative prognathism"), infections, necrosis and fractures (Ritchie et al. 1994, Rupley 1999, Rossi et al. 2005).

Discussion and Conclusions: in accordance with literature, some surgical techniques can be used for the restoration of ramphothec of birds and chelonians. Surgical techniques had been adapted some and equipment that had become surgical act faster e diminishes costs. It better had adaptation of the birds and chelonians after the procedures, allowing better adaptation of the animals the new condition of life.

References: Rupley A.E. 1999. Manual de Clínica Aviária. Roca, São Paulo. - Ritchie B.W., Harrison G.J. & Harrison L.R. 1994. Avian Medicine: principles and application. Wingers Publ., Florida. - Rossi J.R., Baraldi-Artoni S.M., Oliveira D., Cruz C., Franzo V.S. & Sagula A. 2005. Morphology of beak and tongue of partridge *Rhynchotus* rufescens. Ciência Rural, Santa Maria, 35(5):1098-1102. - Getty R. 1989. Anatomia dos Animais Domésticos. Vol.2. 5ª ed. Guanabara Koogan, Rio de Janeiro. - Macari M. 1994. Anatomia e histopatologia funcional do trato digestivo, p.1-18. In: Fundação Apinco de Ciência e Tecnologia Avícolas (ed.), Fisiologia da Digestão e Absorção das Aves. Apinco, Campinas. - Werther K. 2004. Semiologia de animais silvestres, p.723-792. In: Feitosa F.L.F. (ed.), Semiologia Veterinária. Roca, São Paulo. - Ford, E. 1998. Falconry: art and practice. Blandford, London, p.28-31.

INDEX TERMS: Veterinary dentistry, wild animals, avian, chelonians, fracture, ramphothec, repair.

059. Scatena D.A. & Venturini M. 2007. **Survey of feline odontoclastic resorptive lesion at the Veterinary Dentistry Center, from 1994 to 2004.** Research performed as course finals' assigment for Veterinary Medicine by the first author, in the Veterinary Dentistry Centre (Odontovet), USP, São Paulo, SP, Brazil. E-mail: dani.scatena@uol.com.br

Introduction: During the felines' oral cavity exam or during the prophylaxis some lesion can be found on the surface of their teeth. The resorptive lesion in cats is known by many names. In articles and annals, it has been reported as a lesion of the cervical line, erosion of the cervical line, resorption of the cervical line, odontoclastic resorptive lesion, feline odontoclastic resorptive lesion (FORL), feline's dental resorption lesion, cervical resorption buccal of the root, among others (Wiggs & Lobprise 1997). The first description of the disease was made in 1955, when it was presumed as being decay on the root. The lesion was described again in the middle of 1970s, when a new description was published and the disease appearead with great incidence. Retrospective evaluation of the cats' cranium found in 1800 revealed a small incidence of the disease, and in a text by Colver (1936) the discovering of this lesion's nature failed. A reevaluation in 1991 of 80 craniums originally inspected by Clover in 1936 revealed a cranium with resorptive lesion (1.25%). The resorption is characterized by a defect of the enamel, dentin and cementum. This lesion is always referred to as a cervical lesion or a lesion of the cervical line, because the rustic defect is observed more frequently in the cervical area of the tooth. Due to the lesion being more common in premolars and molars covered by plaque or gingivitis and stomatitis, these lesions are frequently associated (Harvey 1993). The lesion was initially described as decay, due to the radiographic similarity of the lesion with the decay and the clinic similarity (radiolucency) with the contact of the decay in human teeth. However since Schneck & Osborne (1976) related this lesion in the teeth of cats with periodontitis resulting from the resorptive odontoclastic lesion, the defect has been included within the category of periodontal disease (Harvey 1993).

Materials and Methods: It was made a survey about FORL at the Veterinary Dentistry Center (ODONTOVET) in 1994-2004 with the purpose to observe the incidence of the lesion in cats through the comparison with breed, sex and age. The research is based on the clinical file card of the local, noticing the animal's data and its affections. Some tables were developed in Excel and after their analysis, it was observed that the total number of the cats attended during this period was 1,233 (760 Mongrel, 261 Siamese, 166 Persian, 13 Birman, 5 Angora, 6 British shorthair, 5 Maine coon, 4 Oriental, 2 Ragdool, 2 Himalayan, 2 Abysinnian, 2 Exotic, 2 Russian Blue, 1 Egipsy, 1 Tortoiseshells, 1 Wild cat). Through these data, the animals were divided into affected animals by FORL and healthy animals. To develop a comparative research, the affected animals were divided into breed, sex, age, allowing this way the development of graphics and the index.

Results and Discussion: From the total of 1,233 animals, 567 animals (46%) have FORL, but it wasn't possible to compare the number of lesions and their extension, because many file cards didn't have complete data (Fig.1). Between the animals that presented the disease, 307 (54%) were females and 260 (46%) were males (Fig.2). As there were 645 (52%) females and 588 (48%) males from a total of 1,233 animals, this shows that females are more presisposed to FORL.

The second topic analyzed was the prevalence of the lesion compared to the breeds. Based on the data, the breeds with higher incidence during the period were Persian, Mongrel and Siamese, and the breeds with lower incidence were considered in a single group, called others. From the total of 1,233 animals, 760 (62%) were Mongrel, 261 (21%) were Siameses, 166 (13%) were Persian, and 46 (4%) were others. By this way, 367 (48%) Mongrel have FORL, and 126 (48%) of the Siameses, 53 (32%) of the Persian and 21 (45%) of the others haad the lesion. It can be concluded

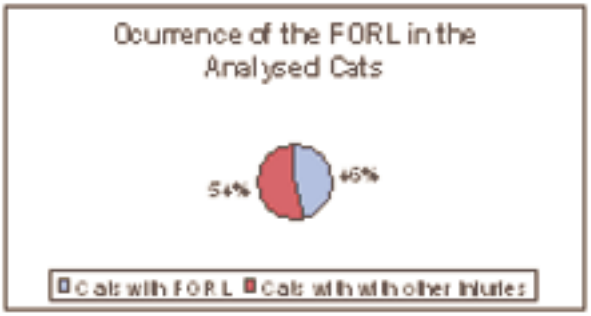

Fig.1



Fig.2



Fig.3

that Mongrel and Siameses are among the most predidposed breeds for FORL, compared with Persian and other investigated ones, despite that the samples of Mongrel and Siameses were more numerous. It can be suggested then that both the Mongrel and Siamese breeds have the same predisposition for developing FORL (Fig.3).

Another topic investigated during the survey was regarding the cats' age of the sample. According to Pollard (2003), the cats reach their maturity within 1 year, becoming adult with 8 years, and from 9 years on they are considered elderly. In this way, the samples were divided into 0-1 year, young (138 animals), from 2-8 years (712 animals) adult, and after 9 years elderly (383 animals). All the animals were computed and the following sampling was determined: 5% (7 animals) of the young ones have the lesion. Among the adults, 44% (318) have the lesion, and 63% (241) of the elderly were charged too (Fig.4, 5 and 6) as follows:

The prevalence of FORL was compared between the breeds and their ages, what resulted in a demonstrative index.

Examining the figures and the table related to the animals' age, we can conclude that the animals of 9 years are more predisposed to FORL independent of the breed. Comparing this study with other researchers, it can be seen that Wessun et al. (1992) showed in their study that the males and animals with advanced age were more easily affected. Ingham et al. (2001) demonstrated that the females and animals with advanced age were the more affected. Our research shows that the females and animals with advanced age were the more affected. Regarding the breeds, there can't be a comparison, because most of the researches are from other countries and they don't have Mongrel breed to compare; so it becomes more difficult to know if they really are more affected. What has been already demonstrated is that the Asian breeds like Siamese and Persian have more

Fig.4

Fig.5



Fig.6

Table 1. Comparison of the FORL by breed and age

Breeds	0 -1 yrs old			2 - 8 yrs old			9 yrs and older		
	No FORL	With FORL	%	No FORL	With FORL	%	No FORL	With FORL	%
Persian	49	1	2%	57	39	40%	6	14	70%
Siamese	18	1	5%	77	50	39%	42	73	63%
Mongrel	59	5	8%	242	219	47%	92	143	61%
Others	5	0	0%	18	10	37%	2	11	85%

predisposition for FORL. The results above show that these breeds are plenty affected, but it can't be concluded which of the breeds have a higher prevalence. There must a more detailed research be done involving other institutions to come to a coherent conclusion.

Conclusion: The felines' odontoclastic resorptive lesion is a disease with a still uncertain etiology, so that many researchers try to solve its mystery. The disease is quite common in the feline's odontology, making the animals feel great pain and their owners look for a veterinary frequently. But many times, because of the lack of information, the disease is wrongly treated and mostly the problem isn't solved. Therefore, it is important to orientate the owners about the conditions of the treatment, because many of the cats become reluctant to the treatment due to the excessive loss of teeth. However, the disease is common, it isn't the more severe of the oral pathologies, being easy to treat and having a good prognosis. With the survey made at ODONTOVET, it is possible to conclude that the lesion has higher prevalence in females, where it reaches higher significance in Mongrel and Siameses. The more affected animals are the ones with advanced age, from 9 years on. We can say that it was a survey of great importance for the study of the lesion, because there are few investigatins about this kind of affection in cats.

References: Gioso M.A. 2003. Odontologia para o Clínico de Pequenos Animais. 5ª ed. i@ditora, São Paulo. - Harvey E.C. 1985. Veterinary Dentistry. W.B. Saunders, Philadelphia. - Harvey E.C. 1993. Feline dental resorptive lesions. Semin. Vet. Med. Surg. Small Anim. 8(3). - Ingham K.E. et al. 2001. Prevalence of odontoclastic resorptive lesions in a population of clinically healthy cats. J. Small Anim. Pract. 42. - Lyon F.K. 1992. Subgingival odontoclastic resorptive lesions: classification, treatment, and results in 58 cases. J. Vet. Clin. North Am. Small Anim. Pract. 22(6). - Pettersson A. et al. 2003. Prevalence of dental resorptive lesion in Swedish cats. J. Vet. Dent. 20(3). - Pollard M. 2003. The Encyclopedia of the Cat. Barnes and Nobles Books, New York. - Wessum V.R. et al. 1992. Feline dental resorptive lesions. Vet. Clin. North Am. Small Anim. Pract..22(6). - Wiggs R.B. & Lobprise H.B. 1997. Veterinary Dentistry: principles and practice. Lippincott-Raven, Philadelphia.

INDEX TERMS: Lesion, teeth, cats.

060. Stegmann G.F. 2007. **Local anesthetic toxicity and treatment.** *Pesquisa Veterinária Brasileira 27(Supl.).* Department of Companion Animal Clinical Studies, University of Pretoria, Private Bag X 04, 0110 Onderstepoort, South Africa. E-mail: frik.stegmann@up.ac.za

Introduction: "Prevention is better than cure", a statement that should be applied when local anaesthetic drugs are administered. Accidental intravenous (IV) injection is the most common cause of systemic local anaesthetic toxicity in man. Just as doses are calculated before anaesthetic drugs are administered, should maximum doses be calculated before the administration of local anaesthetics. Reported clinical toxicity cases in veterinary science are rare but does not imply that it does't occur. The use of dogs as laboratory models for local anaesthetic toxicity is common (Groban et al. 2001). A possible scenario for such toxicity in veterinary practice is the local infiltration for the suturing of large skin wounds in a toy dog breed.

Literature Review: Mechanism of action: Local anaesthetics block impulse conduction (depolarization) in various tissues such as nervous tissue, but also cardiac tissue. Non-ionised drug molecules diffuse from extracellular fluid through the cell membrane to the intracellular fluid in nervous tissue to block the Na-channel, thus preventing depolarization. Factors affecting toxicity: (i) Dose (i.e. mass). Fourty ml of a 1% solution (=400mg) = 20ml of a 2% solution (= 400mg). Toxicity may occur after administering an overdose (max. dose not calculated) or as result of accumulation during continuous administration. (ii) Rate of absorption as influenced by the route of administration; and in decreasing order from IV, intercostal, interpleural, epidural, brachial plexus, and peripheral tissue. (iii) Distribution and metabolism. Ester local anaesthetics are metabolized in peripheral tissues and toxicity is rarely seen. Amide local anaesthetics are primarily metabolized in the liver. (iv) Acidosis (as induced by hypoxia or hypercarbia) increases intracellular ionized local anaesthetic and therefore prevents its removal from the cells (Wildsmith 2003). Nervous system: Early signs reported in man are numbness of the tongue and lips, light-headedness, or tinnitus, followed by slurred speech - all signs that may go unnoticed in veterinary patients. Sympathetic nervous activation results in an increase in heart rate, cardiac output and blood pressure. Onset of drowsiness is a sign of severe toxicity. Muscle twitching, loss of consciousness, convulsions (associated with excessive oxygen consumption) and apnoea rapidly result in acidosis and hypoxia. If resuscitation measures are not expediently applied, cardiac arrest is imminent. In laboratory models of toxicity the cumulative dose required to induce convulsive activity in dogs is 22 mg/kg for lidocaine and 5mg/kg for bupivacaine. The dose for irreversible cardiovascular depression is 3.5-6 times higher (Liu et al. 1983). Cardiovascular system: Local anaesthetics are just as toxic to cardiac tissue and may result in direct cardiac arrest without preceding nervous symptoms (Rosenblatt et al. 1980). Ventricular fibrillation was observed in man after accidental IV injection of the long acting local anaesthetic bupivacaine. This is somewhat contradictory to the traditional perception of local anaesthetics as anti-arrhythmics. As the QT interval is prolonged this may be a contributory factor in initiating ventricular fibrillation. Tissue toxcicity: Nerve damage from the local anaesthetics is rare. Preservatives added to solutions such as sodium bisulphate may result in nerve damage. Trauma to the nerve may occur from mechanical damage of the needle or direct intraneural injections. Injection into a canal (e.g. infraorbital nerve block) should be done slowly to prevent pressure damage to the nerve. Prevention of toxicity: Maximum doses should be pre-calculated. Aspiration test should be performed before injection commences, and when large volumes are involved, should the aspiration test be repeated during injection. Continuous monitoring of the animal is essential for the early detection of adverse reactions. Treatment of local anaesthetic toxicity: signs of nervous excitation may be treated with a benzodiazepine such as diazepam or midazolam. Propofol may be considered but is limited by its cardiorespiratory depression. Administer oxygen with a mask and when consciousness is lost, intubate en ventilate. In the event of cardiac arrest should external cardiac massage be applied. To increase cardiac conduction, should adrenaline be administered. Intralipid may be administered as a 4ml/kg bolus followed by an infusion of 0.5ml/kg/min. for 10min. (Weinberg et al. 2003)

Discussion and Conclusions: High plasma concentrations of local anaesthetics may result in toxicity associated with neurological and cardiovascular dysfunction. Systemic local anaesthetic toxicity although rare in veterinary science may be fatal from cardiorespiratory collapse. Expedient treatment is necessary that may include cardiopulmonary resuscitation and Intralipid administration.

References: Groban L., Deal D.D., Vernon J.C., James R.L. & Butterworth J. 2001. Cardiac resuscitation after incremental overdosage with lidocaine, bupivacaine, levobupivacaine, and ropivacaine in anesthetized dogs. Anesth Analg. 92(1):37-43. - Liu P.L., Feldman H.S., Giasi R., Patterson M.K., Covino B.G. 1983. Comparative CNS toxicity of lidocaine, etidocaine, bupivacaine, and tetracaine in awaking dogs following rapid intravenous administration. Anesth Analg. 62(4)375-379. - Rosenblatt R.M., May D.R. & Barsoumian K. 1980. Cardiopulmonary arrest after retrobular block. Am. J. Ophthalmol. 90(3):425-427. - Weinberg G., Ripper R., Feinstein D.L. & Hoffman W. 2003. Lipid emulsion infusion rescues dogs from bupivacaine-induced cardiac toxicity. Reg. Anesth. Pain Med. 28(3):198-202. - Wildsmith J.A.W. 2003. Clinical use of local anaesthetic drugs. In: Wildsmith J.A.W., Armitage E.N. & McClure J.H. (ed.), Principles and Practice of Regional Anaesthesia. 3rd ed. Churchill Livingstone.

INDEX TEMS: Local anaesthetic, toxicity, intralipid.

061. Stegmann G.F. 2007. **Regional nerve blocks for oral surgery**. *Pesquisa Veterinária Brasileira 27(Supl.).* Department of Companion Animal Clinical Studies, University of Pretoria, Private Bag X04, 0110 Onderstepoort, South Africa. E-mail: frik.stegmann@up.ac.za

Introduction: Regional nerve blocks provide perioperative analgesia as an adjunct to general anaesthesia for painful oral procedures. Nerves that innervate oral tissues include the mental, inferior alveolar, infra-orbital, and maxillary nerves. The majority of dental procedures produce strong noxious stimuli that influence general anaesthesia

and postoperative recovery. Indications for oral pain control include, but are not limited to tumors, reconstruction surgery, oral trauma, jaw fractures, root canal treatment, pulpotomies, extractions, and palatal defects (Goldstein 2002). The maxillary and mandibular nerves originate form the trigeminal nerve and supplies sensory fibers to bone, soft tissue and teeth. Regional nerve blocks allow reduction in the concentration of inhalant anaesthetic, which minimize the risk for hypotension, bradycardia and hypoventilation. This provides for a safer option, especially for geriatric patients that often require dental surgery. Patients recover faster, especially in day cases where the animals are to be send home on the same day. Pre-emptive analgesia furthermore decreases the requirement for systemic pain medication and improves postoperative comfort (Beckman & Legendre 2002, Skarda 1996).

Literature Review: Local anaesthetic drugs: Bupivicaine (0.5%). Rapid onset (10-15min), long duration (3-10 h) of action. Volume administered 0.1-0.5ml for dogs and 0.1-0.3ml in cats. The maximum total dose is 2mg/kg (Beckman & Legendre 2002). Ropivicaine (0.75%) is less cardiotoxic and should be safer to use, but no published data exists in animals. Mental Nerve Block: Bone, teeth and soft tissue rostral to the second premolar is affected. The mental foramen location varies depending on breed, size and species. In dogs it is found just caudal to the mandibular labial frenulum in the ventral third of the mandible on the buccal aspect. The foramen is normally easy to palpate. Aspirate and inject very slowly. Digital pressure for 60 seconds will ensure caudal diffusion of the drug into the mandibular canal. In cats, the middle mental foramen is located at the level of the mandibular labial frenulum and cannot be readily palpated (Beckman & Legendre 2002). Mandibular Nerve Block: The mandibular nerve supplies the bone, teeth, soft tissue, and tongue on the ipsilateral side. The madibular foramen can be palpated intra-orally while the needle is advance extra-orally (Beckman & Legendre 2002). Cranial infra-orbital nerve block: The area affected will be dependant on the volume injected. The bone, soft tissue and teeth rostral to the maxillary first molar will be affected. The infra-orbital nerve branches from the maxillary trunk of the trigeminal nerve at the ptergopalatine fossa. The infra-orbital nerve gives off the caudal superior alveolar nerve before entering the infra-orbital canal. The caudal superior alveolar nerve then branches to supply the maxillary fourth premolar and molars. Once it enters the infra-orbital canal, the infra-orbital nerve branches into the middle superior alveolar nerve that innervates the premolars. The rostral superior alveolar nerve branch just before the infra-orbital nerve exits the infra-orbital canal to innervate the canine and incisor teeth. Unless the agent diffuses beyond the caudal borders of the infra orbital canal, adequate anaesthesia cannot be provided to the maxillary fourth premolars and molars. If anaesthesia to the caudal cheek teeth is required, the maxillary nerve block is used. It also provides anaesthesia to the hard and soft palate (Beckman 2002). The infra-orbital foramen is palpated as a bony ridge in the maxilla dorsal to the distal root of the third maxillary premolar in dogs, and is halfway between a line drawn from the apex of the canine tooth to the dorsal border of the zygomatic arch. In cats, the site of the infra-orbital foramen is palpated as a bony ridge dorsal to the second premolar just ventral to the eye, where the zygomatic arch meets the maxilla (Goldstein 2002). In cats the needle should not be advanced into the foramen as the feline infra-orbital canal is short, and the needle may cause trauma to the orbit (Carmichael 2004). Maxillary nerve block: The maxillary nerve supplies the fourth premolar, molars, soft tissue and palatal tissue caudal to the maxillary premolars. The nose is supplied as well (Beckman 2002). The maxillary nerve enters the maxillary foramen and the infra-orbital canal from the pterygopalatine fossa. The needle is inserted perpendicular to the horizontal line of the palate directly adjacent to the bone at the ventral border of the zygomatic arch. In a dorsal and medial direction, walk the needle slightly rostral along the rostral side of the maxilla to a level just beyond the root tips of the last molar (Goldstein 2002). Alternatively - as for the infra-orbital nerve block, but additional bupivicaine is used. Inject slowly and apply digital pressure to encourage caudal flow to reach the mandibular nerve where it enters the infra-orbital canal. Even though this is easier, damage to the maxillary artery, vein and nerves may occur. With inadequate infiltration - only the soft tissue and teeth cranial to the 4th premolars will be blocked (Goldstein 2002). Palatine block: The palatine nerve innervates partially the maxillary incisors, canines and premolars. This block is recommended in cats. Most of the innervation to the maxillary arch comes from the infra-orbital nerve, and the palatine block only offers some degree of anaesthesia. This block in dogs should be combined with the infra-orbital block. The foramen is found at a midpoint between the mesial aspect of the maxillary carnassial tooth and the palatal midline (Carmichael 2004). Additional drug therapy: For post operative pain control (Rochette 2001), the analgesic should vary depending on the anticipated level of discomfort. Stomatites, multiple extractions, hard or soft palate manipulation should be assumed to have a high level of pain. Opioids are excellent in controlling severe pain. Butorphanol has a duration of 1–2 h, morphine 2-4 h, buprenorphine 8–10 h. Fentanyl patches are an option in severe pain. NSAIDS. Carprofen is a popular choice.

Discussion and Conclusion: With frequent use, regional nerve blocks can become a valuable part of the anaesthetic protocol, improving patient safety and comfort.

References: Beckman B. & Legendre L. 2002. Regional Nerve Blocks for Oral Surgery in Companion Animals. Compend. Cont. Educ. 24(6):439-442. - Carmichael D.T. 2004. Dental Corner: using intra-oral regional anesthetic nerve blocks. www.vetmed pub.com (1 Sept 2004). - Goldstein G.S. 2002. Regional nerve blocks offer pain relief for dental procedures. www.dvmnews.magazine.com 1 Aug. 2002: 1-3. - Rochette J. 2001. Local anesthetic nerve blocks and oral analgesia. Proc. World Small Anim. Vet. Assoc., Vancouver. - Skarda R.T. 1996. Local and Regional Anesthetic and Analgesic Techniques: dogs. In: Lumb and Jones' Veterinary Anesthesia. 3rd ed., p.431-432.

INDEX TERMS: Bupivacaine, dental nerve blocks, ropivacaine.

062. Stepaniuk K.S. 2007. **General anesthesia for the canine and feline dental patients.**
Pacific Veterinary Dental Services P.S., Silverdale, WA 98383, USA. E-mail: kevindentdvm@earthlink.net

Introduction: Anesthesia is relatively safe in the 21st century; even for the most debilitated patients. Some veterinarians do not perform oral procedures due to perceived anesthetic risks for patients with systemic disease. Paradoxically, these are probably the patients that need the treatment the most. Veterinary dentistry requires general anesthesia and intubation. Perioperative planning for systemic medical issues, anticipated pain, duration of the procedure, risks to animal and veterinarian, species differences, and post-operative treatments are necessary. Multimodal-balanced anesthesia to maximize analgesia/anesthesia and minimize the deleterious individual drug side effects is recommended. Selecting and individualizing patient drug protocols is essential. Anesthesia trend monitoring with equipment and physical parameters can maximize patient safety. Thermo-regulation is necessary to maintain patient warmth and prevent sequelae to hypothermia.

Literature Review: Planning begins with principles of multimodal pain management (Ko 2004, Beckman 2006) and balanced anesthesia(Thurmon 1996) to minimize individual drug side effects and maximize each drug benefit.(Woolf 1993) Balanced anesthesia is a state of unconsciousness, muscle relaxation, and analgesia. Neuroleptanalgesia (Muir 1998) involves choosing a combination of a neuroleptic and an analgesic in order to obtain hypnosis and analgesia for chemical restraint. There is no excuse for not having an appropriate armamentarium of anesthetic medications. Patient assessment involves signalment, duration of disease, concurrent disease, previous anesthetic history and physical exam.(Thurmon 1996) The body condition score needs to be considered.(Morgan 1997) Obese patients have diminished ventilatory function and need to be dosed on estimated lean body weights. The cachexic, anorexic patient is physiologically stressed and may have little metabolic reserves for anesthesia. The cardiovascular system should be evaluated for murmurs, pulse deficits, arrhythmias, mucous membrane colour, and capillary refill time. Abnormalities necessitate further diagnostics such as thoracic radiographs, echocardiography, and/or electrocardiogram. The pulmonary system needs to be evaluated for rate, character, and effort. Abnormalities may warrant further diagnostics with thoracic radiographs. Brachycephalic airway syndrome (elongated soft palate, stenotic nares, collapsing trachea, and everted laryngeal saccules) (Koch 2003) is common. Due to the malocclusion and rotation and crowding of the teeth, these patients often present for periodontal abscessation and airway surgery. The hepatic and renal systems must be evaluated in all patients since these organ systems are involved in clearance of medications associated with anesthesia. All patients should have their packed cell volume, total protein, blood urea nitrogen, and glucose evaluated. Obviously, older and more debilitated patients should have a complete blood count, chemistry panel, and urinalysis to screen for underlying conditions. The nervous system, gastrointestinal system, endocrine, integumentary, ophthalmic, and musculoskeletal system need evaluation. Finally, the temperament of the patient must be known. The physical status of the patient can be categorized by the American Society of Anesthesiologists classification scheme (I, II, III, IV, V, E) (Muir 1995). The feline and canine patient should be fasted for 8-12 hours to diminish the likelihood of regurgitation and aspiration. Water can be allowed up to the time of anesthesia. There are few dental and oral surgery emergencies. Therefore, the patient should have preexisting abnormalities corrected prior to anesthesia. Preanesthetic medications decrease patient anxiety, provide chemical restraint, diminish dosages of other drugs, provide pre-emptive analgesia, and block adverse effects of other drugs. Classes of preanesthetic drugs (Brock 1998) include major tranquilizers such as phenothiazines (acepromazine), minor tranquilizers (benzodiazepines) such as diazepam, midazolam, and zolazepam, alpha-2 agonists (medetomidine) (Paddleford 1999), opioids (pure agonists: morphine, oxymorphone, fentanyl, and hydromorphone), (partial agonists: butorphanol and buprenorphine (Taylor 1999)), and dissociative anesthetics (ketamine and tiletamine). An anticholinergic such as glycopyrrolate or atropine can be chosen to counteract the bradycardic effects of opioids and to decrease oral salivary secretions for the dental procedure. Induction agents(Brock 1998) include propofol (Branson 1994, Bufalari 1998, Short 1999, Matthews 2004), ketamine/diazepam, tiletamine/zolazepam, etomidate, and opiod inductions. Better yet, combinations of low dose ketamine, diazepam, and a touch propofol can provide smooth inductions as well as act in multimodal analgesia with ketamine preemptively blocking the NMDA central receptors (Wagner 2002, Beckman 2006). Propofol is a good induction agent for outpatient dental procedures. However the apneic and negative inotropic effects must be taken into consideration. Cardiac patients may experience the negative inotropic effects and have difficulties with blood pressure. An etomidate or opiod induction is a better alternative in the cardiac patient. (Brock 1998, Harvey 1999, Pablo 1999) Prior to induction the anesthetic machine should be checked for proper function. Anesthetic machine maintenance is necessary for delivery of safe anesthesia. Carbon dioxide absorbing granules must be changed frequently. Gas anesthetics include halothane, isoflurane, and sevoflurane. (Clarke 1999, Harvey 1999, Galloway 2004). If using halothane, intraoral analgesia and gingival retraction cords should not contain epinephrine since catecholamine induced arrhythmias may occur (Mealey 1999). Local analgesia should be utilized for all dental procedures. Intraoral analgesia is part of a multimodal pain approach and decreases inhalant gas anesthetic requirements (Beckman 2002, Lantz 2003, Carmichael 2004). Post-operative pain can be controlled by diminishing central sensitization in the spinal cord before a painful stimulus occurs (Woolf 1993, Wolfe 2003, Savage &Henry 2004). Regional analgesia will decrease transmission of painful stimuli to the central nervous system from surgical pain

stimulation (Beckman 2006). Intravenous catheter placement must occur in each patient. The catheter provides access for administration of anesthetic medications, intravenous fluids(Brock 1998, Broadstone 1999), and emergency situations. Crystalloid solutions are administered intravenously to all dental patients. A starting guideline is to administer crystalloids at 10ml/kg/hr during anesthesia. Additionally, colloidal solutions such as hetastarch may be necessary in uncorrectable hypotensive patients. Blood products such as packed red blood cells may be necessary for surgeries where the major palatine, infraorbital, or mandibular artery may be compromised. Anesthetic monitoring is important to prevent critical changes in a patient's physiological status. It is recommended to address physiological and pathological complications before they happen rather than when they happen. Particular areas of concern include hypoxia, hypercapnia, hypotension, and hypothermia which increase the risk for deaths as well as post-surgical secondary complications. Many anesthetic medications depress the respiratory and cardiovascular systems. Subjective evaluations include jaw tone, palpebral reflex, mucous membrane and capillary refill time (only estimates perfusion - anemic and poorly perfused animals can have relatively normal mucous membranes and CRT and be in serious danger), respiratory rate and character, and heart rate and rhythm. Objective anesthesia monitoring [pulse oximetery (SpO_2), capnography (End Tidal CO_2), blood pressure, electrocardiogram (ECG), and blood gas analysis) is available in most hospitals. However, it is the author's pet peeve when veterinary technicians and veterinarians spend several minutes after induction setting up the electronic monitoring devices without patient assessment. SpO_2 is a mathematical calculated estimate of hemoglobin-oxygen saturation measured by infrared light (indirect measurement of oxygen saturation) (Wright 1996, Grosenbaugh 1998b). Hypovolemia, motion, pigment, placement, and anemia can result in inaccurate readings. The $SpO-_2$ should be between 95-100% in patient breathing oxygen under anesthesia. End Tidal CO_2 is a graphic display of carbon dioxide pressure over time (indirect measurement of carbon dioxide partial pressure) that allows assessment of ventilation, the breathing circuit, and ventilation-perfusion function in the lungs (Wright 1996, Grosenbaugh 1998c). End Tidal CO_2 should be between 35-45 mmHg. Blood pressure can be measured indirectly (via cuff) or directly (via arterial catheter attached to a transducer) (Meurs 1996, Grosenbaugh 1998a). Pressure changes are as important as the actual pressures. Blood pressure can be related to the depth of anesthesia, blood volume, strength of cardiac contraction, and systemic vascular resistance. The minimum mean arterial blood pressure should not drop below 60 mmHg in order for the kidneys, brain, lungs, and heart to maintain perfusion. Blood gas analysis to assess pH, PaO_2, $PaCO_2$, bicarbonate, and electrolytes can be assessed with an ARTERIAL blood sample evaluated on an ISTAT machine. The ECG allows assessment of electrical activity of the heart not the mechanical function. It allows for identification of specific arrhythmias. Thermoregulation is important in the dental patient. The patients are often small, under anesthesia for 1-2 hours, and experiencing coolant from ultrasonic scalers and high speed dental drills. Heat is lost via radiation, convection, evaporation, and conduction. Hypothermia(Muir 1995, Thurmon 1996) can affect the central nervous system (prolonged recovery), cardiovascular bradycardia (not anticholinergic responsive), gastrointestinal (ileus), respiratory (depression, acidosis, apnea), and metabolic systems (decreased clotting and decreased immune system functions). Rectal temperature is affected by regional blood flow and may be 1 degree Celsius less than the core temperature. Esophageal temperature monitors may more accurately reflect core temperature. PREVENTION of hypothermia is the best treatment. Force air heating systems, circulating water blankets, and intravenous fluid warmers can be utilized for prevention of heat loss. Ambient temperature should be considered. A cool room with the air conditioning vent near or over the dental area can dramatically cause hypothermia despite warming devices. Electrical heating pads, heat lamps, and radiating heaters should not be utilized due to the risks of thermal burn injuries.

Discussion and Conclusions: Anesthesia can be performed safely on most, if not all, dental and oral surgery patients. Patient assessment and balanced-multimodal anesthesia is critical to outcome. Assessment of the anesthetic patient is a dynamic process. Changes in monitoring parameters are as important, or more important, than the actual parameters at any given time. Infrequent and limited monitoring can be detrimental to the patient. Consultation with a veterinary anesthesiologist can assist with high risk patients. Anesthesia is a team approach. A veterinarian and a veterinary technician should be present for the entirety of each procedure to perform the dental and anesthesia safely.

References: Beckman B. 2006. Pathophysiology and management of surgical and chronic oral pain in dogs and cats. J. Vet. Dent. 23:50-60. - Beckman B. & Legendre L. 2002. Regional nerve blocks for oral surgery in ccmpanion animals. Compend. Cont. Educ. Pract. 24:439-442. - Branson K.R. & Gross M.E. 1994. Propofol in veterinary medicine. J. Am. Vet. Med. Assoc. 204:1888-1890. - Broadstone R.V. 1999. Fluid terapy and newer blood products. Vet. Clin. North Am. Small Anim. Pract. 29:611-628. - Brock N. 1998. Veterinary Anesthesia Update: guidelines and protocols for safe small animal anesthesia. Vol.1 and 2. NW, Richmond, BC. - Bufalari A., Miller S.M., Giannoni C. & Short C.E. 1998. Veterinary Anesthesia: the use of Propofol as an induction agent for Halothane and Isoflurane anesthesia in dogs. J. Am. Anim. Hosp. Assoc. 34:84-91. - Carmichael D. 2004. Using intraoral regional anesthetic nerve blocks. Vet. Med. Vol. **???** :766-770. - Clarke K.W. 1999. Desflurane and Sevoflurane. Vet. Clin. North Am. Small Anim. Pract. 29:793-810. - Galloway D.S., Ko J.C., Reaugh H.F., Mandsager R.E., Payton M.E., Inoue T. & Portillo E. 2004. Anesthetic indices of sevoflurane and isoflurane in unpremedicated dogs. J. Am. Vet. Med. Assoc. 225:700-704. - Grosenbaugh D.A. & Muir W.W. 1998a. Blood pressure monitoring. Vet. Med. Vol. **???** : 48-59. - Grosenbaugh D.A. & Muir W.W. 1998b. Pulse oximetry: a practical, efficient monitoring method. Vet. Med. Vol **???** January:60-66. - Grosenbaugh D.A. & Muir W.W. 1998c. Using end-tidal carbon dioxide to monitor patients. Vet. Med. Vol. **???** :67-74. - Harvey R.C. & Paddleford R.R. 1999. Management of geriatric patients. Vet. Clin. North Am. Small Anim. Pract. 29:683-699. - Ko J. 2004. Acute pain management protocols. Ettinger's Insights in Intern. Med. 2:1-10. - Koch D.A., Arnold S., Huble, M. & Montavon P.M. 2003. Brachycephalic syndrome in dogs. Compend. Cont. Educ. Pract. 25:48-54. - Lantz G.C. 2003. Regional anesthesia for dentistry and oral surgery. J. Vet. Dent. 20:181-186. - Matthews N.S., Brown R.M., Barling K.S., Lovering S.L. & Herrig B.W. 2004. Repetitive Propofol administration in dogs and cats. J. Am. Anim. Hosp. Assoc. 40:255-260. - Mealey K.A.M. 1999. Drug interactions during anesthesia. Vet. Clin. North Am. Small Anim. Pract. 29:629-643. - Meurs

K.M., Miller M.W. & Slater M.R. 1996. Comparison of the indirect oscillometric and direct arterial methods for blood pressure measurements in anaesthetized dogs. J. Am. Anim. Hosp. Assoc. 32:00-00 **???**. - Morgan R.V. 1997. Handbook of Small Animal Practice. W.B. Saunders Company, Philadelphia. - Muir W.W. 1998. Anesthesia for dogs and cats with cardiovascular disease. Part II. Compend. Cont. Educ. Pract. Vet. 20:473-484. - Muir W.W.I. & Hubbel J.A.E. 1995. Handbook of Veterinary Anesthesia. Mosby, St. Louis. - Pablo L.S. & Bailey J.E. 1999. Etomidate and Telazol. Vet. Clin. North Am. Small Anim. Pract. 29:779-792. - Paddleford R.R. & Harvey R.C. 1999. Alpha$_2$ agonists and antagonists. Vet. Clin. North Am.: Small Anim. Pract. 29:737-745. - Savage M.G. & Henry M.A. 2004. Preoperative nonsteroidal anti-inflammatory agents: review of the literature. Oral Surg. Oral Med. Oral Pathol. Oral Radiol. Endod. 98:146-152. - Short C.E.B. 1999. Propofol anesthesia. Vet. Clin. North Am. Small Anim. Pract. 29:747-778. - Taylor P.M., 1999. Newer analgesics. Vet. Clin. North Am. Small Anim. Pract. 29:719-735. - Thurmon J.C., Tranquilli W.J. & Benson G.J. 1996. Lumb and Jones' Veterinary Anesthesia. Williams and Wilkins, Baltimore. - Wagner A.E., Walton J.A., Hellyer P.W., Gaynor J.S. & Mama K.R. 2002. Use of low doses of ketamine administered by constant rate infusion as an adjunct for postoperative analgesia in dogs. J. Am. Vet. Med. Assoc. 221:72-75. - Wolfe T.M. & Muir W. 2003. Local Anesthetics: Pharmacology and novel applications. Compend. Cont. Educ. Pract. 25: 916-924. - Woolf C.J. & Chong M. 1993. Preemptive analgesia-treating postoperative pain by preventing establishment of central senisitization. Anesth. Analg. 77:362-379. - Wright B. & Hellyer P.W. 1996. Respiratory Monitoring during Anesthesia: pulse oximetry and capnography. Compend. Cont. Educ. Pract. 18:1083-1097.

INDEX TERMS: Dental anesthesia, anesthesia monitoring, balance anesthesia, multimodal anesthesia.

063. Stepaniuk K.S. 2007. **Oronasal fistula repair with a single buccal mucoperiosteal sliding flap or a double inverted palatal flap and buccal sliding flap.** *Pesquisa Veterinária Brasileira 27(Supl.).* Pacific Veterinary Dental Services P.S., Silverdale, WA 98383, USA. E-mail: kevindentdvm@earthlink.net

Introduction: An oronasal fistula (ONF) is a communication between the oral and nasal cavity. A fistula is defined as a communication between two epithelial surfaces (Noden 1985). Communication with the oral cavity and nasal cavity can occur with periodontal disease, loss of any of the maxillary teeth, trauma, electrical burns, cleft palates, neoplasia, and/or maxillectomy site dehiscence. The communication most often occurs with the loss of the maxillary canine teeth (Harvey 1985). Anatomically the maxillary teeth are closely associated with the nasal cavity (Evans 1993). A vertical periodontal palatal pocket of 104 and 204 can lead to destruction of the thin bone separating the root apices and the nasal cavity (Manfra-Marretta 1992). Oral stratified keratinized squamous epithelium and the nasal stratified cuboidal to nonciliated pseudostratified columnar and ciliated pseudostratified columnar epithelium line the maxillary and nasal sides of the defect, respectively (Dellman 1993, Wiggs 1997). Without correction of the fistulae, oral bacteria, food, and fluids will communicate with the nasal cavity and cause a chronic rhinitis, infection, and morbidity. Repair techniques of ONF include single buccal mucoperiosteal sliding flaps, palatal inverted and buccal sliding flaps, palatal and labial buccal pedicle flaps, split U-flaps, rotational palatal flaps, and advancement flaps (Marretta 1988, Smith 2001, Holmstrom 2004, Marretta & Smith 2005, Van de Wetering 2005). For oronasal defects secondary to periodontal disease of teeth 104 and 204, a single buccal mucoperiosteal flap is adequate for primary repair. With large defects or failures, an inverted double palatal and buccal sliding flap can be utilized to close the defect. With large defects secondary to cleft palates, trauma, burns, and neoplasia other aforementioned techniques are often utilized.

Literature Review: A single buccal mucoperiosteal flap is utilized when attached gingiva remains to provide strength for suturing. A periodontal flap creates visibility of the underlying bone and root surface by surgically separating gingiva or mucosa from the underlying tissues.(Newman 2002) Visualization of the bone defect into the nasal cavity is necessary to debride the necrotic bone margins and to remove communicating epithelium. A full thickness flap includes all the overlying soft tissue and the periosteum (Newman 2002). Full thickness flaps are stronger, less painful, and have less post-operative swelling (Eisner 1997). The goal of surgical intervention is to provide an epithelial surface on the nasal and oral sides of the flap (Smith 2000). Migration of nasal epithelial cells is necessary to cover the nasal surface of the flap. During creation of periodontal flaps, vascularization must be preserved to ensure appropriate healing. The dorsal and ventral labial arteries and the angular artery provide vascularization of the buccal mucosa (Smith 2000). Long narrow flaps may have inadequate blood supply and lead to necrosis of tissue at the tip of the flap(Luskin 2000). A broad based flap would help preserve vascularization to the tissue. The margins of the ONF are excised using a scalpel blade to remove the epithelium and create fresh bleeding margins for reattachment. Fresh vascularized margins will allow first intention healing to occur. Creating fresh margins with scissors can bluntly crush tissue (Luskin 2000) and damage the microvascular supply leading to delayed second intention healing. The mucoperiosteal flap is elevated using a periosteal elevator directed toward the bone and moving in an apical direction. Care is taken not to perforate the mucosa which will diminish the success of the procedure (Bojrab 1990). Closure of flaps without tension is very important. Tension can be released by harvesting a large broad based flap, releasing underlying connective tissue and periosteum, and using a walking suture technique (Luskin 2000). A broad flap is created from distal 103/203 to distal 105/205. The periosteal flap is released by carefully transecting the periodontal ligament fibers at the base of the flap. Transection of these fibers allows the alveolar mucosa to stretch and the mucoperiosteal flap to cover the defect without tension. The flaps are initially apposed and sutured at the vertical margins to the palatal mucosa. After the flap is anchored, the fresh margins of the palatal mucosa and free margin of the mucoperiosteal flap are sutured. Finally, the vertical releasing incisions are sutured in apposition. The simple interrupted sutures are placed approximately 2-3mm apart and no less than 2-3mm from the incision (Newman 2006) Closure of the flap is achieved with poliglecaprone, polyglactin 910, or

chromic gut. Polyglactin 910 is a braided multifilament (Slatter 1993) which has the potential to wick bacteria. Monofilament sutures withstand bacterial contamination from surgical sites better than multifilaments (Boothe 1998). Polydioxanone is not an appropriate suture for the oral cavity due to its long degradation time and potential to cause foreign body reactions.(Slatter 1993, DeNardo 1996, Boothe 1998) Normally, poliglecaprone on a precision point-reverse cutting needle is chosen for oral surgery by the author. - The double-flap technique is often utilized following a previous single flap failure, to cover large defects, or when insufficient attached gingiva is present for suture anchorage. However, if the previous single flap failure was due to inappropriate flap size or disregard for flap principles, a broader based flap with adherence to principles can often resolve the defect without a double-flap technique. The double-flap provides and epithelial surface to the nasal cavity. With this technique, a full thickness palatal flap is created by incising the palatal mucosa parallel to the mesial and distal margins of the defect near or past the midline of the palate.(Holmstrom 2004) The midline incisions are extended bucally toward the fistula. Hemorrhage will occur due to a branch of the palatal artery (Evans 1993). Digital pressure is often sufficient to control the minor hemorrhage. If necessary, the branch can be ligated. The palatal flap is elevated with a periosteal elevator and inverted to cover the fistula. The hinge of the inverted flap is adjacent to the palatal margin of the fistula. A buccal mucoperiosteal flap is then created, as above, and sutured to the palatal flap. The palatal defect is allowed to heal by second intention. Care should be taken with a full thickness flap in the rostral oral cavity to not expose the nasopalatine foramen. If necessary, a partial thickness flap may be needed in the region. - If there is insufficient tissue to create the buccal mucoperiosteal flap to cover the palatal flap, a partial thickness sliding buccal pedicle flap can be created (Holmstrom 2004). Two distal to mesial incisions can be created in the alveolar mucosa. The more apical incision should be made just coronal to the mucogingival junction. The width between the two incisions should be 1.5 to 2 times the diameter of the defect to cover. The incisions are extended mesially to obtain the appropriate length and connected mesially with a perpendicular incision (apical-coronal). Care should be taken to preserve the vascular supply in the flap. The pedicle flap is rotated and sutured over the palatal flap. The mucosal defect is then sutured closed. - Regardless of the flap repair, the patient should receive antibiotics for 10 days, soft food for 14 days, 0.12% chlorhexidine rinse for 10-14 days, no toys for 14 days, minimal client and handling of the flap, and an Elizabethan collar to prevent the patient for pawing at the incisions. A recheck to evaluate the flap in 14 days is recommended. (Holmstrom 2004)

Discussion and Conclusions: Success of periodontal flaps is contingent on proper surgical techniques and understanding principles of periodontal surgery. Attached gingiva, incorporated periosteum, tension free flaps, and no sutures over bone defects are necessary to increase success of mucoperiosteal flaps.(Eisner 1997; Newman 2006) Furthermore, owner and patient compliance is an additional factor that must be considered. Oronasal fistulas are common findings in canine patients with severe periodontal disease of the maxillary canine teeth. Appropriate extraction techniques and mucoperiosteal flap repair will often solve the pathological communication. However, if the owner and patient are noncompliant, principles of periodontal surgery are not followed, and inappropriate suture materials are selected, the patient may develop a communication between the oral and nasal cavity.

References: Bojrab M.J.T. 1990. Small Animal Medicine and Oral Surgery. Lea and Febiger, Philadelphia, p.91-95. - Boothe H.W. 1998 Selecting suture materials for small animal surgery. Compend. Contin. Educ. Pract. Vet. 20:155-163. - Dellman H.D. 1993. Textbook of Veterinary Histology. Lea and Febiger, Philadelphia, p.136-141, 153-158. - DeNardo G.A., Brown N.O., Trenka-Benthin, S. & Maretta S.M. 1996. Comparison of seven different suture materials in the feline oral cavity. J. Am. Anim. Hosp. Assoc. 32:164-172. - Eisner E.R. 1997. Nonsurgical and surgical tooth extractions and oronasal fistula repair, Part 2. Canine Pract. 22:5-9. - Evans H.E. 1993. Miller's Anatomy of the Dog. W.B. Saunders, Philadelphia, p.145-148, 165-166, 618-620. - Harvey C.E. 1985. Veterinary Dentistry. W.B. Saunders, Philadelphia, p.345-349. - Holmstrom S.E., Fitch P. & Eisner E.R. 2004. Veterinary Dental Techniques for the Small Animal Practitioner. W.B. Saunders, Philadelphia, p.329-335. - Luskin I.R. 2000. Reconstruction of oral defects using mucogingival pedicle flaps. Clin. Techn. Small Anim. Pract. 15:251-259. - Manfra-Marretta S. 1992. Chronic rhinitis and dental disease. Vet. Clin. North Am. Small Anim. Pract. 22. - Marretta S.M. 1988. The diagnosis and treatment of oronasal fistulas in three cats. J. Vet. Dent. 5:4-5. - Marretta S.M. & Smith M.M. 2005. Single mucoperiosteal flap for oronasal fistula repair. J. Vet. Dent. 22:2000-2005. - Newman M.G., Takei H.H. & Carranza F.A. 2002. Carranza's Clinical Periodontology. W.B. Saunders, Philadelphia, p.762-764. - Newman M.G., Takei H.H., Klokkevold P.R. & Carranza F.A. 2006. Clinical Periodontology. W.B. Saunders, Philadelphia, p.931. - Noden D.M. 1985. The Embryology of Domestic Animals: developmental mechanisms and malformations. Williams and Wilkins, Baltimore, p.277. - Slatter D. 1993. Textbook of Small Animal Surgery. W.B. Saunders, Philadelphia, p.204-211. - Smith M.M. 2000. Oronasal fistula repair. Clin. Techn. Small Anim. Pract. 15:243-250. - Smith M.M. 2001. Island mucoperiosteal flap for repair of oronasal fistula in a dog. J. Vet. Dent. 18:127-129. - Van der Wetering A. 2005. Repair of an oronasal fistula using a double flap technique. J. Vet. Dent. 22:243-245. - Wiggs R.B. & Lobprise H.B. 1997. Veterinary Dentistry: principles and practice. Lippincott-Raven, Philadelphia, p.74-76.

INDEX TERMS: Oronasal fistula, single buccal mucoperiosteal flap, double inverted palatal flap.

064. Surgeon T.W. 2007. Indications planning and ethical considerations for orthodontic treatment. *Pesquisa Veterinária Brasileira 27(Supl.).*

ANC Veterinary Center, 1 Cottage Place, New Rochelle, New York 10801, USA. E-mail: surgeon668@cs.com

Introduction: The identification of an orthodontic problem rests with both the Veterinarian and the client. In early puppy or kitten life a number of genetic/ developmental conditions may be manifest. Frequent oral examinations during this early phase will dictate the need for Guidance of the occlusion (interception).

Literature Review: The indication for orthodontic intervention is based on an understanding of the accepted nor-

mal anatomical variance among the breeds and the sequence of dentinal events that occur in the early stages of a pets life. Timing of orthodontic intervention is an important consideration. There are instances in which early orthodontic therapy is justified, necessary and prudent. However the tendency of early termination necessitating retreatment is higher when the early intervention option is chosen, thereby lengthening the treatment period. Guidance of occlusion by the timed extraction of primary teeth so that the permanent teeth can erupt into a favorable occlusion, intercepting in part , the occurrence of a major malocclusion. A malocclusion may contribute to both oral discomfort and periodontal disease. In areas that are out of occlusal alignment, making the self cleaning mechanism dysfunctional, excessive plaque accumulation occurs. Although a malocclusion can compromise oral function, this condition is of minor consequence for the 21st century pet which has all its food provided by the owner. Malocclusion is not a disease, rather is a disability with a potential influence on physical health which can be averted by appropriate therapy. Treatment Planning: The initial step in treatment planning is prioritizing the existing problems and deciding in which order to strategize the procedures. Force application needs to be determined, whether to use continuous, intermittent or interrupted force duration. The goal in treatment planning is to predict accurately the final resting position of the tooth/ teeth that are to be moved and the need for retention until both the soft and hard tissues have stabilized. The visualization of this goal can be accomplished using models or computer generated imaging modalities photography and radiography to facilitate a three dimensional conceptualization of the task ahead. The ultimate objective of orthodontic Therapy is to obtain an optimal occlusion that facilitates normal function and physiologic adaptation. A good working knowledge of the biomechanics and physiologic principles governing tooth movement is essential for success. It is also imperative to understand the genetic, developmental and environmental forces that can impact the functional occlusion of our patients so that an autonomous rather than a paternalistic approach can be taken during the dialog with clients. The eventual outcome is invariably more predictable when the client is an integral part of the decision making process. Ethical Considerations: The obligation of the orthodontist as stipulated in the American Association of Orthodontists Code of Ethics (1998) is "to perform the highest quality orthodontic service within his /her power while respecting the patient's right to decide the treatment best suited to personal needs". The ADA (1998) Principles of ethics state, "The Dentist's primary professional obligation shall be service to the public. The competent and timely delivery of quality care within the bounds of the clinical circumstances presented by the patient, with due consideration being given to the needs and desires of the patient shall be an important aspect of that obligation". The AVMA Principles of Professional Ethics states, "It is unethical to perform a procedure for the purpose of concealing a congenital or inherited abnormality that sets the animal apart from the normal as described for the breed. Any procedure that will alter the natural dental arcade is unethical. Should the health and welfare of the individual patient require correction of such genetic defects, it is recommended that the patient be rendered incapable of reproduction". Ethical and Professional Standards Statement: AVDC endorses the AVMA Principles of Veterinary Medical Ethics and the American Board of Veterinary Specialties statement that members of ABVS-recognized colleges are to "Demonstrate unquestionable moral character and ethical professional behavior".

Discussion and Conclusions: The early recognition of occlusal problems and the early intervention to correct them will result in a more comfortable lifestyle for the pet and a worry free existence for the owner. It is an Ethical obligation. It is our collective responsibility to ensure that undesirable genetic traits are not perpetuated in the species that we service.

References: Goldstein G.S. 1990. Diagnosis and treatment of orthodontic problems. In: Marretta S.M. & Proffit W.R. (ed.), Contemporary Orthodontics. Problems in Veterinary Dentistry. Vol.2. 2nd ed. - Wiggs R.B. & Lobprise H.B. 1997. Veterinary Dentistry Principles and Practice. - Harvey C.E. & Emily P.P. 1993. Small Animal Dentistry. - Graber T.M. & Vanarsdall Jr R.L. 2000. Orthodontics Current Principles and Techniques. 3rd ed Mosby, St Louis. - Hale F.A. 2005. Juvenile veterinary dentistry. Vet. Clin. North Am. Small Anim. Pract. Dent. 35(4):789-817. - Surgeon T.W. 2005. Fundamentals of small animal orthodontics. Vet. Clin. North Am. Small Anim. Pract. Dent. 35(4):869-889.

INDEX TERMS: Orthodontics, treatment planning, ethics.

065. Surgeon T.W. 2007. **The most useful orthodontic devices in dogs and cats.** *Pesquisa Veterinária Brasileira 27(Supl.).* ANC Veterinary Center, 1 Cottage Pl, New Rochelle, NY 10801. E-mail: surgeon668@cs.com

Introduction: There are numerous options relative to the orthodontic movement of teeth in dogs and cats. This lecture will cover the most frequently encountered conditions and examine the treatment modalities in current usage. A unique feature of orthodontics is the ability to achieve a desirable end result utilizing a wide variety of options. One of the most frequently encountered orthodontic problems in the dog is base narrow canines, which can be treated by: 1) Coronal amputation with vital pulp therapy, 2) Tooth Extraction, 3) Tooth Extenders, 4) Bite wing appliances, 5) Palatal Incline planes (acrylic or metal), 6) Memory wire, 7) Screw Expansion Devices, 8) Spring loaded devices, 9) Ball, 10) Quad helix device, 11) Wedges, 12) Laser or diamond bur Gingivoplasty, 13) Surgical maxillary bone recontouring, 14) Partial extraction and repositioning techniques. This list of possible treatment options I am sure is incomplete. Similarly in the cat the occurrence of lance canines can be corrected with mesal power chains and reinforced anchorage.

Discussion and Conclusions: this lecture will look at the most frequently encountered orthodontic problems in the dog and cat, and formulate the most expeditious methods of treating the problem. Chairside application of some devices

is not only more economically feasible for the client but involves less anesthetic episodes for the patient. Clients that must travel long distances are truly appreciative of having the consultation the impression and device placed at a single visit. Edge wise nickel titanium (NiTi) memory wire, Tooth extenders, Bite wing Appliances, maxillary and mandibular based Inclined Planes (ICPs), Mesal Power Chains (MPC). Elastics can all be placed on the initial visit. Lab Fabricated devices on the other hand require an additional anesthesia for the impression and model with subsequent anesthesia for placing of the appliance when it returns from the lab. A third anesthesia episode is required to remove the appliance.

References: Goldstein G.S. 1990. Diagnosis and Treatment of Orthodontic Problems. In: Problems in Veterinary Dentistry Vol.2. - Marretta S.M. & Proffit W.R. 1990. Contemporary Orthodontics. 2nd ed. - Wiggs R.B. & Lobprise H.B. 1997. Veterinary Dentistry: principles and practice. Lippincot-Raven Publ., Philadelphia. - Harvey C.E. & Emily P.P. 1993. Small Animal Dentistry, L. Mosbym St Lowis. – Graber T.M. & Vanarsdall Jr R.L. 2000. Orthodontics Current Principles and Techniques. 3rd ed. Mosby, St Louis. - Hale F.A. 2005. Juvenile veterinary dentistry. Vet. Clin. North Am. Small Anim. Pract. Dent. 35(4):789-817. - Surgeon T.W. 2005. Fundamentals of small animal orthodontics. Vet. Clin. North Am. Small Anim. Pract. Dent. 35(4):869-889.

INDEX TERMS: Orthodontics, chairside appliances, laboratory fabricated appliances.

066. Valduga M.I.R. 2007. **Pets Dental Care Campaign: dream or reality?** *Pesquisa Veterinára Brasileira 27(Supl.).* Odontocão, Curitiba, PR, Brazil. E-mail: bel@odontocao.com.br

Introduction: Odontocão, a Veterinary Dental Care Clinic, in the course of 10 years taking care of dental problems in dogs and cats noted that owners don't know that the majority of their pets have some kind of dental disease. To help clarify and spread the need to take care of the pets' oral health, Odontocão developed in 2006, from May to August a dental care campaign in Curitiba, Paraná, Brazil. The campaign goals were make a study about the dental condition of the pet population in Curitiba, inform about the importance of dental care and clarify that pet life quality is connected to oral health.

Materials and Methods: Twenty pet shops were selected to participate in the campaign. The shops received the campaign materials as follow: banner about the campaign that had the number of participants and the name of the pets that were selected in the contest to receive the weekly prizes; folders about the campaign (prevention tips, how-to's, teeth brushing tips, etc); and coupons to identify the pets and to be used as a ticket to participate in the contest. The pet that was selected received a dental care kit and oral exam at Odontocão. Every pet that brushed their teeth were then add to the campaign numbers showed in the banners.

Results: During the campaign period 7,440 pets had their teeth brushed. From the pets that received the oral exam: 1.5% had good oral health, 2% neck lesion, 2.5% dental fracture, 11% persistent deciduous and 83% periodontal disease. From the 1.5% pets that had good oral health, 98% of then were less than one year old.

Discussion and Conclusions: Periodontal disease was the most common problem in oral cavity of the pets studied in this campaign. These results follow the same conclusions of other authors (Bojrab & Tholen 1989, Emily & Penman 1990, Harvey & Emily 1993, Marretta 1994, Gioso 1994, Valduga 1996, Domingues et al. 1997, Valduga 1997, Debowes 1998, Román 1999, Apollo 2002).

References: Gioso M.A. 1994. Odontologia Veterinária para o Clínico de Pequenos Animais. 3ª ed. Ed. leditora, São Paulo. - Valduga M.I.R. 1996. Relatório de estágio curricular apresentado para a conclusão de curso. Faculdade de Medicina Veterinária, UFPR, Curitiba. - Valduga M.I.R. 1997. Anais XIX Congr. Bras. Clín. Vet. Peq. Animais, Curitiba, PR. - Domingues L.M., Alessi A.C., Canola J.C. et al. 1999. Arq. Bras. Med. Vet. Zootec. 51(4):323-328. - Apollo F.H. 2002. Relatório de estágio curricular apresentado para conclusão de curso, Faculdade de Veterinária, UFRGS, Porto Alegre. - Bojrab M.J. & Tholen M. 1989. Small Animal Oral Medicine and Surgery. Lea and Febiger, Philadelphia. - Emily P. & Penman S. 1990. Handbook of Small Animal Dentistry. 2nd ed. Pergamon Press, Oxford. - Harvey C.E.& Emily P.P. 1993. Small Animal Dentristy. Mosby, St Louis. - Marretta S.M. 1994. Current concepts in canine and feline dentistry. In: Bonagura J.D. (ed.), Current Veterinary Therapy, XII. W.B. Saunders, Philadelphia. - Debowes L.J. 1998. The effects of dental disease on systemic disease. Vet. Clin. North Am. Small. Anim. Pract. 28:1057-1062. - Román F.S. et al. 1999. Periodontia. Enfermidade periodontal, p.111-125. In: Román F.S. (ed.), Atlas de Odontologia de Pequenos Animais. Manole, São Paulo.

INDEX TERMS: Dental care, campaign, periodontal disease.

067. Viegas C.A.A., Dias M.I.R., Thams U., Binder do Prado A.M., Watzek G., Rodrigues J.A., Llorens P. & San Román F. 2006. **Platelet Rich Plasma: an useful, economic and safe add in Veterinary Dentistry.** *Pesquisa Veterinária Brasileira 27(Supl.).* Department of Veterinary Sciences, UTAD, Ap.1013, 5001-801 Vila Real, Portugal. E-mail: cviegas@utad.pt

Introduction: The goal of periodontal therapy is to protect and maintain the patient's natural dentition over his lifetime for optimal comfort, function and esthetic appearance (Zander et al. 1976, Carranza et al. 2002). After periodontal or oral surgery, healing proceeds by repair or regeneration. Repair is the healing of a wound by tissue that does not fully restore the architecture or function of the affected unit, whereas regeneration is reproduction or reconstitution of a lost or injured part (American Academy of Periodontology 2001). The aim of regenerative periodontal procedures is to induce regeneration at the alveolar bone and cementum and to develop a new functional periodontal ligament (Giannobile et al. 1996, Camargo et al. 2002, Carranza et al. 2002).

A recent innovation in dentistry is the preparation and use of platelet-rich plasma (PRP), a concentrated suspension of the growth factors found in platelets. These growth factors

are involved in wound healing and are postulated as promoters of tissue regeneration, including those in the periodontal area (Anitua et al. 1999, Man et al. 2001, Petrungaro et al. 2001, Aghaloo et al. 2002, Camargo et al. 2002, Carlson et al. 2002, Lekovic et al. 2002). This review focuses on PRP, an autologous, economic and safe substance with significant benefits in Dentistry on several fields as implantology, periodontology, oral and maxillofacial surgery, among others, to enhance wound healing and regeneration (Pierce et al. 1991, Marx et al. 1998, Man et al. 2001, Kim et al. 2002).

Materials and Methods: *Preoperative PRP preparation.* PRP is prepared in a laboratory or a surgical suite from blood collected from a venous puncture in the immediate preoperative period because surgery itself leads to platelet activation of the coagulation system (Marx et al. 1998, Man et al. 2001, Gonshor et al. 2002). Recent publications have indicated that PRP prepared from 8 to 10 mL of whole blood is sufficient for periodontal regenerative therapies (Weibrich et al. 2001, Camargo et al. 2002, Lekovic et al. 2002). However, in oral and maxillofacial reconstruction, 8 to 500 mL of whole blood should be drawn, so as to obtain the greater amounts of PRP needed for larger surgical defects (Marx et al. 1998, Man et al. 2001, Gonshor et al. 2002), The blood sample is drawn into a citrated tube (1 mL of citrate phosphate dextrose to 5 mL of blood) (Marx et al. 1998). If more than 8mL is needed (e.g., for larger defects), more than one tube of blood should be drawn. The sample tube is then spun in a standard centrifuge (gradient density centrifugation process) for 10min at 3,500rpm to produce platelet poor plasma (PPP), red blood cells and buffy coat or platelet rich plasma (it contains between three to tenfold over baseline native concentration of platelets) that contains platelets and leucocytes, acting like an autologous antibiotic. Because of differential densities, the red blood cell layer forms at the lowest level, the PRP layer in the middle, and the PPP layer on the top (Marx et al. 1998). The PPP is taken up into a syringe with a long cannula and an additional air-intake cannula. Than we removed the supernatant (upper platelet poor plasma zone) and the centrifuge speed is lowered to 2,400rpm (14 minutes) to obtain a real separation between the red blood cells on the bottom and the buffy coat on the supernatant. The second supernatant is also taken up by a long cannula and an air-intake cannula. For each 8mL of blood, the volume of supernatant is about 0.6-0.7mL; this is the PRP, to be used for the surgical procedure. At the time of the application, the PRP is combined with an equal volume of a sterile saline solution containing 10% calcium chloride (a citrate inhibitor that allows the plasma to coagulate) and 5,000 U of sterile bovine thrombin (an activator that allows polymerization of the fibrin into an insoluble gel, which causes the platelets to degranulate and release the indicated mediators and cytokines); the result should be a sticky gel that will be relatively easy to apply to the surgical defects (Man et al. 2001, Camargo et al. 2002, Lekovic et al. 2002). The PPP can be stored for use as a protective barrier over the wound. The addition of thrombin and calcium to PRP results in activation of the clotting cascade with conversion of fibrinogen to fibrin, and also the activation and subsequent degranulation of the platelets.

Results: the platelets become trapped in the fibrin mesh, secreting their contents and stabilizing the clot via receptors for fibrin, collagen and adhesive glycoproteins. The fibrin matrix that results is that of a native fibrin clot, allowing normal cellular infiltration of monocytes, fibroblasts and other cells critical to wound healing. A number of substances released by degranulated platelets contribute to their role in primary haemostasis. They include: serotonin, catecholamines, ADP, ATP, fibrinogen, fibrinectin, factor V, Von Willebrand factor VII, Thromboxane A_2, and calcium. Of equal and perhaps greater importance is the release by platelets of a number of growth factors that enhance body's wound healing. They include: Platelet-Derived Growth Factor (PDGF), Transforming Growth Factor-alpha and beta and (TGF-â) (TGF-á), Platelet-Derived Endothelial Cell Growth Factor (PD-ECGF), Platelet-Derived Angiogenesis Factor (PDAF), Insulin Like Factors I and II (IGF I), (IGF-II), Acid and Basic Fibroblasts Growth Factors (aFGF) (bFGF), Bone Morphogenetic Proteins (BMPs 1-15), Epidermic Growth Factor (EGF), Interleukins (IL-1-22), Parathyroid Related Protein (PTHrP), Cement-Derived Growth Factor (CDGF), Adhesion Factors (fibronectina, osteopontina, bone sialoprotein), Conjunctive Peptide III Activator (CTAP-III), Vascular Endothelial Growth Factor (VEGF) and Colony Stimulation Growth Factors (CSF-G; GM and M) (Appel et al. 2002).

Discussion and Conclusions: PRP is a new application of tissue engineering and a developing area for clinicians and researchers. It is a storage vehicle for growth factors, especially PDGF and TGF-â, both of which influence bone regeneration. Although the growth factors and the mechanisms involved are still poorly understood, the ease of applying PRP in the dental clinic and its beneficial outcomes, including reduction of bleeding and rapid healing, hold promise for further procedures. Most important, this autologous product eliminates concerns about immunogenic reactions and disease transmission. Animal studies and recently published human trials have demonstrated successful results. More welldesigned and properly controlled studies are needed to provide solid evidence of PRP's capacity for and impact on wound healing, soft-tissue reconstruction and (in combination with bone grafts) augmentation procedures, especially in oral and periodontal therapy.

References: Aghaloo T.L., Moy P.K. & Freymiller E.G. 2002. Investigation of platelet-rich plasma in rabbit cranial defects: a pilot study. J. Oral Maxillofac. Surg. 60(10):1176-1181. - American Academy of Periodontology 2001. Glossary of periodontal terms. 4th ed. Chicago, p.44. - Anitua E. 1999. Plasma rich in growth factors: preliminary results of use in the preparation of future sites for implants. Int. J. Oral Maxillofac. Implants 14(4):529-535. - Appel T.R., Pötzsch B., Müller J., Lindern J.J.von, Berge S.J. & Reich R.H.. 2002. Comparison of three different preparations of platelet concentrates for growth factor enrichment. Clin. Oral Implants Res. 13(5):522-528. - Camargo P.M., Lekovic V., Weinlaender M., Vasilic N., Madzarevic M. & Kenney E.B. 2002. Platelet-rich plasma and bovine porous bone mineral combined with guided tissue regeneration in the treatment of intrabony defects in humans. J. Periodontal Res. 37(4):300-306. - Carlson N.E. & Roach R.B. Jr 2002. Platelet-rich plasma: clinical applications in dentistry. J. Am. Dent. Assoc. 133(10):1383-1386. - Carranza F.A., McLain P.K. & Schallhorn R.G. 2002. Regenerative osseous surgery, p.804-824. In: Newman M.G., Takei H.H. & Carranza F.A. (ed.), Clinical Periodontology. 9th ed. W.B. Saunders Company, Philadelphia. - Giannobile W.V. 1996. Periodontal tissue engineering by growth factors. Boné 19(1, Suppl):23S–37S. - Gonshor A. 2002. Technique for producing platelet-rich plasma and platelet concentrate: background and process. Int. J. Periodontics Restorative Dent. 22(6):547-557. - Kim S.G., Chung C.H., Kim Y.K., Park J.C. & Lim S.C. 2002. Use of particulate dentin-plaster of Paris combination with/without platelet-rich plasma in the treatment of bone defects around implants. Int. J. Oral Maxillofac. Implant 17(1):86-94. - Lekovic V., Camargo P.M., Weinlaender M., Vasilic N. & Kenney E.B. 2002. Comparison of platelet-rich plasma, bovine porous bone mineral, and guided tissue regeneration versus platelet-rich plasma and bovine porous bone mineral in the treatment of intrabony defects: a reentry study. J. Periodontol. 73(2):198-205. - Man D., Plosker H. & Winland-Brown J.E. 2001. The use of autologous

platelet-rich plasma (platelet gel) and autologous platelet-poor plasma (fibrin glue) in cosmetic surgery. Plast. Reconstr. Surg. 107(1):229-237. - Marx R.E., Carlson E.R., Eichstaedt R.M., Schimmele S.R., Strauss J.E. & Georgeff K.R. 1998. Platelet-rich plasma: growth factor enhancement for bone grafts. Oral Surg. Oral Med. Oral Pathol. Oral Radiol. Endod. 85(6):638-646. - Petrungaro P.S. 2001. Using platelet-rich plasma to accelerate soft tissue maturation in esthetic periodontal surgery. Compend. Contin. Educ. Dent. 22(9):729-732, 734, 736. - Pierce G.F., Mustoe T.A., Altrock B.W., Duel T.F. & Thomason A. 1991. Role of platelet-derived growth factor in wound healing. J. Cell Biochem. 45(4):319-326 - Zander H.Á., Polson A.M. & Heijl L.C. 1976. Goals of periodontal therapy. J. Periodontol. 47(5):261-266. - Weibrich G., Kleis W.K., Kunz-Kostomanolakis M., Loos A.H. & Wagner W. 2001. Correlation of platelet concentration in platelet-rich plasma to the extraction method, age, sex, and platelet count of the donor. Int. J. Oral Maxillofac. Implants 16(5):693-699.

INDEX TERMS: Blood platelets, growth factors, periodontal regeneration.

068. Viegas C.A.A., Muñoz F., Thams U., Rodrigues J.A. Dias M.I.R., Binder do Prado A.M., Watzek G., Llorens P. & San Román F. 2007. **Periodontal regeneration with PRP (Platelet Rich Plasma): experimental study in Beagle dogs.** Department of Veterinary Sciences, UTAD, Ap. 1013, 5001-801 Vila Real, Portugal. E-mail: cviegas@utad.pt

Introduction: The goal of periodontal therapy is to protect and maintain the patient's natural dentition over his lifetime for optimal comfort, function and esthetic appearance. (Zander et al. 1976, Carranza et al. 2002). After periodontal or oral surgery, healing proceeds by repair or regeneration. Repair is the healing of a wound by tissue that does not fully restore the architecture or function of the affected unit, whereas regeneration is reproduction or reconstitution of a lost or injured part. (American Academy of Periodontology 2001). The aim of regenerative periodontal procedures is to induce regeneration at the alveolar bone and cementum and to develop a new functional periodontal ligament. (Giannobile et al. 1996, Camargo et al. 2002, Carranza et al. 2002).

A recent innovation in dentistry is the preparation and use of platelet-rich plasma (PRP), a concentrated suspension of the growth factors found in platelets. These growth factors are involved in wound healing and are postulated as promoters of tissue regeneration, including those in the periodontal area. (Anitua et al. 1999, Man et al. 2001, Petrungaro et al. 2001, Aghaloo et al. 2002, Camargo et al. 2002, Carlson et al. 2002, Lekovic et al. 2002). This review focuses on PRP, an autologous, economic and safe substance with significant benefits in Dentistry on several fields as implantology, periodontology, oral and maxillofacial surgery, among others, to enhance wound healing and regeneration (Pierce et al. 1991, Marx et al. 1998, Man et al. 2001, Kim et al. 2002,). The purpose of this study was to prove the effect of the soft laser compared to the PRP in the reconstruction and healing of hard and soft periodontal tissue after periodontal reconstructive surgery.

Materials and Methods: In this experiment ten beagle dogs were used. They were divided into two groups. The procedure was the following: Approximately 7mm large periodontal defects were created in the mandibular vestibular face at the 4th premolar and the 1st. molar. The root surfaces were then instrumented to remove all cementum and the wounds immediately closed by replacing and suturing the flaps just coronal to the cementum-enamel junction. All the defects were filled up with collagen, but on 5 dogs the collagen was saturated with PRP and placed after having sutured and closed the control side hermetically. The other 5 dogs were operated in the same way (the collagen was only used to fill up the defects). During a period of 4 weeks, 5 days a week, the teeth were treated with soft laser only on experimental side. The dogs were sacrificed 16 weeks postsurgery. Histometric recordings included height and area of alveolar bone regeneration, height of cement regeneration, connective tissue repair, and junctional epithelium. We evaluated the bone regeneration, the dental cement regeneration, the new PDL, the collagen sponges persistence, root resorption and/or ankylosis histologicly (Wikesjo, 1991). Group means, standard deviations, and P values are shown (Student *t* test; n=5 y $\div^2$; n=2).

Results: The regeneration of bone was 3.1+0.7 for the PRP against 2.4+0.7 on the control site (p=0.04). The bone area values are 3.4 + 1.0 for the PRP against 1.5 + 10 on control (p=0.01). The regenerated cement measured 2.7 + 0.9 with PRP against 2.6 + 0.8 on the control site. The junctional epithelium measured 1.7 v 0.6 with PRP against 2.7 + 0.8 on control site (ns). The connective tissue repair measured 2.8 + 1.5 with PRP against 2.4+ 0.7 on control. Ankylosis was 0.0 + 0.0 with PRP against 0.0 + 0.0 on control (ns). In the PRP group we could observe a nearly continuous layer of osteoblasts lined the newly formed bone, and there was a dense cellular "front" with mesenchymal stem cells and blastic cells at the coronal extent of the new bone. The PDL presents great reactivity with mesenquimal cells, neo blood vessels and functionally oriented, inserted and densely packed periodontal fibers. In the PRP experiment control group we could find the same regeneration standard but slowly developed. We couldn't find collagenous vehicles in both the experimental and the control groups. The height and area of alveolar bone regeneration in the experimental group are improved related with the control group with statistical significance. The alveolar bone crest in the experimental side presents great activity with osteoblasts margining the crest and cementoblasts margining the new regenerated cement.

Discussion and Conclusions: Our data suggest that PRP alone helps with the bone regeneration approximately with a 20% of improvement. All the review authors were worked with PRP and another technique, because of this we could not compare our results with them.

References: Aghaloo T.L., Moy P.K. & Freymiller E.G. 2002. Investigation of platelet-rich plasma in rabbit cranial defects: a pilot study. J. Oral Maxillofac. Surg. 60(10):1176–1181. - American Academy of Periodontology 2001. Glossary of periodontal terms. 4th ed. Chicago, p.44. - Anitua E. 1999. Plasma rich in growth factors: preliminary results of use in the preparation of future sites for implants. Int. J. Oral Maxillofac. Implants 14(4):529–535. - Camargo P.M., Lekovic V., Weinlaender M., Vasilic N., Madzarevic M. & Kenney E.B. 2002. Platelet-rich plasma and bovine porous bone mineral combined with guided tissue regeneration in the treatment of intrabony defects in humans. J. Periodont. Res. 37(4):300–306. - Carlson N.E. & Roach R.B. Jr 2002. Platelet-rich plasma: clinical applications in dentistry. J. Am. Dent. Assoc. 133(10):1383-1386. - Carranza F.A., McLain P.K. & Schallhorn R.G. 2002. Regenerative osseous surgery, p.804-824. In: Newman M.G., Takei H.H. & Carranza F.A. (ed.), Clinical Periodontology. 9th ed. W.B. Saunders, Philadelphia. - Giannobile W.V. 1996.

Periodontal tissue engineering by growth factors. Boné. 19(1, Suppl.):23S-37S. - Kim S.G., Chung C.H., Kim Y.K., Park J.C. & Lim S.C. 2002. Use of particulate dentin-plaster of Paris combination with/without platelet-rich plasma in the treatment of bone defects around implants. Int. J. Oral Maxillofac. Implants 17(1):86–94. - Lekovic V., Camargo P.M., Weinlaender M., Vasilic N. & Kenney E.B. 2002. Comparison of platelet-rich plasma, bovine porous bone mineral, and guided tissue regeneration versus platelet-rich plasma and bovine porous bone mineral in the treatment of intrabony defects: a reentry study. J. Periodontol. 73(2):198–205. - Man D., Plosker H. & Winland-Brown J.E. 2001. The use of autologous platelet-rich plasma (platelet gel) and autologous platelet-poor plasma (fibrin glue) in cosmetic surgery. Plast. Reconstr. Surg. 107(1):229-237. - Marx R.E., Carlson E.R., Eichstaedt R.M., Schimmele S.R., Strauss J.E. & Georgeff K.R. 1998. Platelet-rich plasma: growth factor enhancement for bone grafts. Oral Surg. Oral Med. Oral Pathol. Oral Radiol. Endod. 85(6):638–646. - Petrungaro P.S. 2001. Using platelet-rich plasma to accelerate soft tissue maturation in esthetic periodontal surgery. Compend. Contin. Educ. Dent. 22(9):729-732, 734, 736. - Pierce G.F., Mustoe T.A., Altrock B.W., Duel T.F. & Thomason A. 1991. Role of platelet-derived growth factor in wound healing. J. Cell Biochem. 45(4):319-326 - Zander H.Á., Polson A.M. & Heijl L.C. 1976. Goals of periodontal therapy. J. Periodontol. 47(5):261-266. - Wikesjo U.M.E., Selvig K.A., Zimmerman G. & Nilvéus R. 1991. Periodotal repair in dogs: healing in experimentally created chronic periodontal defects. J. Periodont. 62(4):258-263.

INDEX TERMS: Platelet Rich Plasma, periodontal regeneration.

069. Viegas C.A.A., Muñoz F., Thams U., Rodrigues J.A. Dias M.I.R; Binder do Prado A.M., Watzek G., Llorens P. & San Román F. 2007. **Periodontal regeneration with low level laser therapy (soft laser): experimental study in Beagle dogs.** *Pesquisa Veterinária Brasileira 27(Supl.).* Department of Veterinary Sciences, UTAD, Ap.1013, 5001-801 Vila Real, Portugal. E-mail: cviegas@utad.pt

Introduction: The goal of periodontal therapy is to protect and maintain the patient's natural dentition over his lifetime for optimal comfort, function and esthetic appearance. (Zander et al. 1976, Carranza et al. 2002). The aim of regenerative periodontal procedures is to induce regeneration at the alveolar bone and cementum and to develop a new functional periodontal ligament. (Giannobile et al. 1996, Camargo et al. 2002, Carranza et al. 2002). The last decade has seen an explosion of research work in the application of laser technology to general dental practice. Despite the many advantages which 'hard' or 'hot' surgical lasers (such as CO2, Nd:YAG and Er:YAG) offer for tooth-related procedures, issues such as instrument costs and the potential for thermal injury to dental pulp from thermal changes, have limited the uptake of this technology in general dental practice (Walsh et al. 1994, Pick et al. 1995). At the opposite end of the equipment spectrum are the semiconductor diode lasers, which are sometimes referred to as 'cold' or 'soft' lasers. In medicine and dentistry, diode lasers have been used predominantly for applications which are broadly termed low level laser therapy (LLLT), biostimulation or "biomodulation" (The latter term is more appropriate, since the therapy can not only stimulate, but also suppress biological processes) (Goldman et al. 1987) however, there is controversy surrounding the effectiveness of some of these procedures (Nemeth et al. 1993, Basford et al.1995). Low-level laser therapy (LLLT) refers to the use of red-beam or near-infrared nonthermal lasers with a wave-length between 600 and 1000nm power from 5-500 milliwatts. In contrast, lasers used in surgery typically use 300 watts. These types of lasers have been advocated for use in wound healing (Borgogna et al.1983, Armida et al.1989, Braekt et al. 1991, Hall et al.1994). The exact mechanism of its effect is unknown; however, hypotheses have included improved cellular repair and stimulation of the immune, lymphatic and vascular systems. The purpose of this study was to prove the effect of the soft laser in the reconstruction and healing of periodontal tissue after periodontal reconstructive surgery.

Materials and Methods: In this experiment 5 Beagle dogs were used. The procedure was the following: 7mm large periodontal defects were created in the mandibular vestibular face at the 4th premolar and the 1st molar. The root surfaces were then instrumented to remove all cementum and the wounds immediately closed by replacing and suturing the flaps just coronal to the cementum-enamel junction. All the defects were filled up with collagen, and during a period of 4 weeks, 5 days a week, the teeth were treated with soft laser only on experimental side. The dogs were sacrificed 16 weeks postsurgery. Histometric recordings included height and area of alveolar bone regeneration, height of cement regeneration, connective tissue repair, and junctional epithelium. We evaluated the bone regeneration, the dental cement regeneration, the new PDL, the collagen sponges persistence, root resorption and/or ankylosis histologicly (Wikesjo, 1991). Group means, standard deviations, and P values are shown (Student *t* test; n=5 y $\div^2$; n=2).

Results: The size of regeneration with laser measured 1.8 + 0.5 against 2.3 + 0.8 on control (ns). Bone-values with laser were 2.1 + 0.8 against 2.7 + 1.0 on control (ns). The regenerated cement measured 1.7 + 0.5 with laser against 2.8 + 0.8 on control (p=0.006). The junctional epithelium measured 2.7 v 1.1 with laser against 2.8 + 0.1 on control (ns). The connective tissue repair measured 2.2 + 1.0 with laser against 1.6 + 0.4 on control (p=0.04). Ankylosis was 0.0 + 0.0 with laser against 0.0 + 0.0 on control (ns). One could find root resorption on 12/20 with laser against 17/20 on control. The irradiated bone presents architectural disorganization and an intense activity of bone remodelling. We could see some empty osteocytes lacunes and some osteocytes nucleus in picnosis or cariolisis. The PDL presents a few density of functionally oriented periodontal fibers and was poorly irrigated. We couldn't find collagenous vehicles in both the experimental and the control groups.

Discussion and Conclusions: These various treatment procedures are used to treat a wide range of medical conditions. There does not appear to be standards regarding the dose, number of treatments or the length of treatment. Controlled clinical studies have demonstrated that while LLLT is effective for some specific applications, it is not a panacea. Our data suggest that laser helps with the soft tissue cicatrization but it stops the bone regeneration.

References: Armida M.M.T. 1989. Laser therapy and its applications in dentistry. Pract. Odontol. 10:9-16. Walsh L.J. 1997. The current status of LLLT in dentistry. Part 1: Soft tissue applications. Aust. Dent. J. 42(4):247-254. - Basford

J.R. 1995. Low intensity laser therapy: still not an established clinical tool. Lasers Surg. Med.16:331-342. - Borgogna E., Leung C.Y., Manfredi C., Roccia G.M. & Roccia L. 1983. First observations on soft-laser therapy in odontostomatology. Minerva Med. 74:1693-1696. - Camargo P.M., Lekovic V., Weinlaender M., Vasilic N., Madzarevic M. & Kenney E.B. 2002. Platelet-rich plasma and bovine porous bone mineral combined with guided tissue regeneration in the treatment of intrabony defects in humans. J. Periodont. Res. 7(4): 300–306. - Carranza F.A., McLain P.K. & Schallhorn R.G. 2002. Regenerative osseous surgery, p.804-824. In: Newman M.G., Takei H.H. & Carranza F.A. (ed.), Clinical Periodontology. 9th ed. W.B. Saunders, Philadelphia. - Giannobile W.V. 1996. Periodontal tissue engineering by growth factors. Bone 19(1, Suppl.):23S. - Goldman L., Goldman B. & Van Lieu N. 1987. Current laser dentistry. Lasers Surg. Med. 6:559-562. - Hall G., Anneroth G., Schennings T., Zetterqvist L. & Ryden H. 1994. Effect of low level energy laser irradiation on would healing: an experimental study in rats. Swed. Dent. J.18:29-34. - In de Braekt M.M., van Alphen F.A., Kuijpers Jagtman A.M. & Maltha J.C. 1991. Effect of low level laser therapy on wound healing after palatal surgery in beagle dogs. Lasers Surg. Med. 11:462-470. - Neiburger E.J. 1995. The effect of low-power lasers on intraoral wound healing. NY State Dent. J. 61:40-43. - Nemeth A.J. 1993. Lasers and wound healing. Dermatol. Clin.11:783-789. - Zander H.Á., Polson A.M. & Heijl L.C. 1976. Goals of periodontal therapy. J. Periodontol. 47(5):261-266. - Pick R.M. & Miserendino L.J. 1995. Lasers in dentistry. Quintessence, Chicago, p.17-25. - Walsh L.J. 1994. Dental lasers: some basic principles. Postgrad. Dent. 4:26-29. - Wikesjo U.M.E., Selvig K.A., Zimmerman G. & Nilvéus R. 1991. Periodotal repair in dogs: healing in experimentally created chronic periodontal defects. J. Periodont. 62(4):258–263.

INDEX TERMS: Low level laser therapy, biostimulation, periodontal regeneration.

070. Viegas C.A, San Román F., Castejón-González A.C., Rubio L., Manso C.,Whyte A. & Lloréns P. 2007. **Surgical endodontics in horses: case reports**. *Pesquisa Veterinária Brasileira 27(Supl.).* Department of Animal Medicine and Surgery, Veterinary Faculty, Universidad Complutense de Madrid, Avda Puerta de Hierro s/n, 28040 Madrid, Spain. E-mail: fsanroman@vet.ucm.es

Introduction: Periapical diseases of teeth in horses can end up causing fistulous trajects with purulent secretion that can persist and become chronic even with the administration of antibiotic treatment. In these cases, nowadays there are two possible treatments: exodontics or apicoectomy. Exodontics in horses should be considered the last option because the absence of a dental piece may unstabilize the rest of the teeth, push the pieces, form beaks, and cause overgrowth (Kirkland et al. 1996, Baker 1999). This would require periodic controls and treatments for the rest of the animal´s life; therefore whenever the tooth does not present mobility and periodontal tissue is healthy, apex resection should be the choice. Apicoectomy permits the maintenance of the tooth for a long time and, therefore maintain the stability of the oral cavity (Kirkland et al. 1996, Baker 1999, Steenkamp et al. 2005). The percentage of success of the apicoectomy in horses varies in 36 to 84% as a consequence of the complexity of the pulpar chamber, the difficulty to clean it completely and most importantly the difficulty to seal adequately the apex (García et al. 1990, Kirkland et al. 1996, Baker 1999, Steenkamp et al. 2005).

Materials, Methods and Results: *Case 1.* A young female Shetland pony, presented a chronic fistulae with purulent secretion in the infraorbitarial region. In the oral examination nothing was found that could justify the lesion. In the oblique x-ray a radiolucent periapical area was seen in the distal root of piece 207. An apicoectomy of both of the roots of piece 207 was decided under general anaesthesia. For the post surgical treatment, analgesics (fynadine) and antibiotherapy with cephalexine were administered. Two months afterwards the fistula appeared again, with osteomyelitis surrounding the roots, therefore the extraction of the dental piece was decided. - *Case 2.* A 7-year-old Pure Blood Spanish Breed Horse, with a chronic fistula in the left mandible body. The X-ray of the mandible showed a fistulous traject originated in the mesial root of piece 309 with calcifications in the wall. The animal did not present alterations in the oral cavity that could justify the pathology, it did not present pain nor eating problems. An apicoectomy was planned under general anaesthesia. The resection of the two apexes was done. Dehiscence of the skin sutures happened three days after the surgery. It was treated with antibiotherapy and daily cures. Second intention scarring of the flap occurred and there were no other complications. - *Case 3.* A chronic fistula in the left mandibular body was treated in an 8-year-old mixed Spanish Pure Blood Breed Horse which presented a few months evolution. The definitive diagnosis was done by X-ray. The dental pieces and the oral tissues did not present alterations. An apicoectomy was done and the immediate post operatory and follow up during 6 months took place without any complications. - *Case 4.* A chronic fistula of dental origin (408) in the mandibular body of an adult Arabian Breed Horse was treated. A fistulous traject with origin in the distal root of piece 408. The affected tissue and the apexes were eliminated. The sealing was done with calcium hydroxide in paste, glass ionomer and finally with flow composite. The post operatory consisted of antibiotherapy for 7 days and analgesics for 3 days in all cases.

Clinical procedure: 1) The animal is placed in a lateral recumbency position oposite to the side of the affected dental peice. Preparation of the surgical field. Shaving and cleaning with povidone yodade. 2) Approach: Incission of the skin around the fistula to create a cutaneous flap. Dissection of the subcutaneous tissue. Periosteal elevation and exposition of the alveolar bone. Rectangular osteotomy of the lateral bone wall to expose the roots of the tooth. A handpeice and a tungsten round bur were used for the technique with constant irrigation using sterile physiologic solution. Finally the bone is completely separated by an osteotome. 3) Elimination of fistulous soft tissue and sick bone. 4) Exposition of the roots. The apex is cut off in a 45º angle with a fissure bur under constant irrigation to ease the cleaning and the retention of the material. 5) Clearing the pulpal channel with a small spoon in order to eliminate the maximum amount of necrotic tissue possible. Afterwards it is washed with very large amounts of sodic hypoclorate until it flows transparently in order to assure a complete cleaning of the pulpar chamber and canal. Drying with cotton and air. Paper points are not used because of their limited size. 6) Obturation and sealing of the pulp channel. Filling of the pulpar chamber with calcium hydroxide in paste using a syringe and catheter (14g). Then glass ionomer is placed and finally light-curing composite or flow composite is used to complete sealing. 7) Collagen sponge placing over the created bone defect 8. Suture of the periosteum and connective tissue with poliglycolic acid using simple stitches and the skin using simple nylon stitches.

Discussion: Apicoectomy is difined as the section of the apical portion of the dental root in order to seal adequately the canal at this level (Raspal 1994). In humans and small animals

the apicoectomy is always followed by cleaning and complete obturation of the canal and the pulpar chamber (Ruiz de Tremiño 1990, Raspal 1994). In horses cleaning of the dental pulp is very complicated due to the irregular shape and size of the canals (Kirkland et al.1996, Baker 1999). Nevertheless, an exhaustive cleaning of the canal is not as important as a good hermetic sealing of the apex for a successful technique (Kirkland et al. 1996, Baker 1999). The most frequent cause of failure of an endodontic treatment is an insufficient apical sealing. According to Baker (1999), the drying of the pulpar canal must be done routinely with paper points, but the size of the points available is insufficient for a complete drying of the canal, so we think. Instead we use cotton and above all pressured air. The use of gutta-percha points for filling the canal has also been described, but they present the same problem, the size is insufficient and the canal has many dentine wrinkles. The technique we use is to fill the canal completely with calcium hydroxide in paste which is injected inside the canal with a syringe in order to distribute it completely in the spaces. Once it is hardened, a retentive cavity is created in the canal and it is sealed with light-curing composite. In one of the cases in order to improve the sealing, glass ionomer and flow composite were used. In human dentistry amalgama, composite resins, glass ionomer cements, zn phosphate cements and zn oxide-eugenol have been used (Ruíz de Tremiño 1990, Raspal 1994) Amalgama has been the most used for apicoectomies but its toxicity, material contraction and filtrations through the union dentine-amalgama have limited its use. In an *in vitro* study of three materials (amalgama, glass ionomer and IRM) proved that there were no significant differences between these materials (Steenkamp et al. 2005). In all these cases the apicoectomy of both apexes of each dental piece was performed. In one of them necrotic tissue was observed inside each root and in the rest even though necrotic material was observed only in one root, both roots were resected because of the possible communication with the rest of the pulp chamber. According to a study done by Kirkland (2005), the pulp canals in animals less than 6 years old, are communicated in the pulp chamber, in horses over 10 years both canals are separated and there is no communication between them and in horses between 7 and 9 years old, the canals can be communicated or not depending on the dental piece.

Conclusion: We think that in the case of dental fistulae in horse teeth, that present a healthy coronal surface without periodontal lesion or other affections, the best alternative to exodontics is the apicoectomy. The apicoectomy, if succesfull (75%), permits the maintenance of the dental piece and the absence of oral or dental complications, that could appear in exodontic procedures.

References: Baker G.J. 1999. Endodontic therapy, p.250-258. In: Baker J. & Easley J. (ed.), Equine Dentistry. Harcourt Brace and Company, London. - Garcia F., San Román F. & Lloréns M.P. 1990. Endodontics in horses: an experimental study. J. Vet. Med. A 37(3):205-214. - Kirkland D., Baker G., Marretta S., Eurell J. & Losonskyn J. 1996. Effects of aging on the endodontic system, reserve crown, and roots of equine mandibular cheek teeth. Am. J. Vet. Res. 57(1):31-38. - Raspall G. 1994. Cirurgia periapical, p.287-320. In: Raspall G. (ed.), Cirugía Oral. Panamericana, Madrid. - Ruiz de Temiño P. 1990. Cirugía periapical y radicular, p.541-567. In: Donado M. (ed.), Cirugía Bucal: patología y técnica. - Steenkamp G., Olivier-Carstens A., Van Heerden W.F.P., Crossley D.A. & Boy C. 2005. *In vitro* comparison of three materials as apical sealants of equine premolar and molar teeth. Equine Vet. J. 37(2):133-136.

INDEX TERMS: Endodontic disease, apicoectomy, chronic fistulae.

Posters presented at the

10th World Veterinary Dental Congress

001. Carvalho V.G.G., Venturini M.A.F. & Gioso M.A. 2007. **Reconstruction of a dog's face as treatment for oral squamous cell carcinoma**. *Pesquisa Veterinária Brasileira 27(Supl.).* Departamento de Cirurgia, FMVZ-USP, São Paulo, SP, Brazil. E-mail: vanggc@uol.com.br

Introduction: The oral squamous cell carcinoma is the second most common malignant oral neoplasia in dogs, representing 20-30% of the tumors in dogs and 61 to 70% in cats (Stebbins et al. 1989, Withrow 2001). This tumor most often originates on gingiva and tonsila in dog, gingiva and tongue in cats; it deeply infiltrates, proliferates and is almost always ulcerative in dog, resulting in excessive salivation, halitosis and bleeding (Harvey & Emily 1993). In the first stages of gingival carcinoma, the tumor can be similar with local gingivitis. The loss of teeth is common and the owner sometimes believes that there is relationship between the extraction and the tumor appearing (Harvey 1985). In dogs, local and distance metastasis are rare, except in cases of tonsilar and tongue carcinomas. In cats, the regional limphnodes is frequently affected but lung metastasis is rare (Postorino Reeves et al. 1993). An important characteristic about the tonsilar carcinoma is that this kind of tumor normally is unilateral, a good information to differential diagnosis (Harvey 1985). The principles of treatment involve surgical procedure with excision of 1cm of healthy tissue, as safety margin (Wiggs & Lobprise 1977). The radiotherapy can be indicated before surgical treatment or can be done in association of surgery with satisfactory results (Harvey 1985). The purpose of this study is to present a clinical case of reconstruction of a dog face after surgically removal of oral squamous cell carcinoma.

Case Report: A Cocker Spaniel, male, 12-year-old, was consulted in the Veterinary Hospital of the School of Veterinary Medicine, University of São Paulo, presenting a small mass located in the maxilla, around the right fourth premolar tooth and ulcerate lesions spread out to the jugal mucosa, involving all of the labial commissures. These same signals had initiated one year before, at the caudal region of the upper right maxilla. In that period, the animal was treated in a private veterinary clinic with excisional biopsy. The histological diagnosis confirmed the oral squamous cell carcinoma. During the physical examination, the aspect of the skin and upper lips suggested local invasive lesions at these structures; there was halitosis and pain during the manipulation of the oral cavity. Skull radiographs as well as intra-oral did not show bone resorption or any kind of lesion on the region of neoplasia. Thorax X-ray did not show also signs of metastasis.The owner was informed about the necessity to procedure another radical surgery, to try to remove all tissue affected. But, the extension of the lesion could result in a difficult suture because it was expected a large skin loss, resulting in some deformities of the animal face. The anesthetic protocol was pre-medication with Acepromazina (0,1mg/Kg) and Meperidine (5mg/Kg) IM and Propofol (0,5mg/Kg IV) for induction, IV. The anesthesia was maintained with Isofluorane inhalation.The surgery was done with excision of all tumor and 2cm of health tissue beyond, removing part of the maxilla, mucosa and skin. The regional lymphnode was removed too, particularly because it was slightly increased. A large defect was caused by the excision and a reconstruction of the face needed to be realized to close the wound, providing a flap of the neck skin. The internal mucosa was sutured with poliglactin 910 (Vicryl^{R} 4.0) and the skin was sutured with nylon 2.0. The final aspect of the suture was good but a deformity of the right side of the dog face was evident. To assure that the animal would kept the mouth closed, an acrylic interdental block was realized until the total heals of the soft tissues. One week after surgery, the nylon of the skin sutured was removed and the owner related excellent health conditions and good control of pain during the first days. The prescribed drugs were tramadol (1mg/Kg/8h/5d), enrofloxacin (5mg/Kg/24h/10d), chlorhexidine (4xd/10d) and it was recommended an Elizabethan collar 24h/day. The patient presented edema at the surgical region (controlled with anti-inflammatory drugs) and an upper labial small defect. A second physical examination was realized one month after surgery. The animal was re-anesthetized to remove the acrylic splint and no signals of tumor recurrence were observed.

New clinical appointment was recommended after six months of surgery for oral examinations and metastasis control. In this period, the animal presented halitosis and the owner asked for a periodontal treatment. So, the animal was re-anesthetized with the same protocol used before, and during the periodontal treatment, the region from where the carcinoma was removedsix mouths ago could be evaluated and no signals of tumor recurrence were observed. A new biopsy was accomplished in two suspect regions of inflammation of the oral mucosa and the histopathological results confirmed just inflammation, without tumors cells. Radiographs of the maxilla and skull showed no signals of bone lesions and no signals of metastasis respectively, after six mouths of surgery.

Discussion: This related case is a kind of oral squamous cell carcinoma that can be initiated in gingival tissues, near the right upper fourth premolar tooth but after, it was spread out to the oral mucosa causing pain, halitosis and bleeding, according to the signs related in the literature (Harvey 1985, Harvey & Emily 1993). The first surgical intervention was not efficient and did not control the tumor growth. After a radical excision of tumor, with 2cm of margin, like suggested for Wiggs Lobprise (1977), one year later, the patient had an oral health condition without signs of tumor recurrence after 6 months of surgery. The animal face had not signs of deformities or tissue loss because the long hair was covering the skin. In this case, it could be very interesting the association of radiotherapy during and after treatment to control recurrences and metastasis (Harvey 1985). Metastasis is rare in these cases of Oral Squamous Cells Carcinoma, like related by Postorino Reeves et al. (1993), but the patient will be continuously examined during the next months to control possible recurrence and metastasis.

References: Harvey H.J. 1985. Oral Tumors. Vet. Clin. North Am. Small Anim. Pract 15(3):493-500. - Harvey et al. 1993. Small Animal Dentistry. Mosby, Missouri. 413p). - Wiggs R.B. & Lobprise H.B. 1997. Veterinary Dentistry: principles and practice. Lippincot-Raven, Philadelphia. 748p. - Postorino Reeves N.C. et al. 1993. Oral squamous cell carcinoma in the cat. J. Am. Anim. Hosp. Assoc. 29(5):438-441. - Stebbins K.E. et al. 1989. Feline oral neoplasia: a ten-year survey. Vet. Pathol. 26(2):121-128. - Withrow S.J. 2001. Cancer of the oral cavity, p.305-318. In: Withrow S.J., Macewen E.G. (ed.), Small Animal Clinical Oncology, 3rd ed. W.B. Saunders, Philadelphia.

INDEX TERMS: Oral, squamous, carcinoma, dog, mucosa, gingival.

002. Chosa M.[1], Ishikawa H.[2], Soeta S.[3], Ichihara N.[1], Asari M.[1] & Amasaki H.[3] 2007. **Immunocyto related tooth bud absorption in developmental antarctic mink whale.** *Pesquisa Veterinária Brasileira (Supl.).* [1]Laboratories of Anatomy I, Azabu University School of Veterinary Medicine, Fuchinobe 1-17-71, Sagamihara, Kanagawa, 229-8501, Japan; [2]The Institute of Cetacean Research, 4–18 Toyomi-cho, Chuo-ku, Tokyo 104–0055, [3]Laboratories of Veterinary Anatomy, Nippon Veterinary Life Science University, 1-7-1 Kyonan-cho, Musashino-shi, 182-8602, Japan. E-mail: hamasaki@nvlu.ac.jp

Introduction: The Mysticeti has tooth buds temporarily in a certain fetal period (Dissel-Scherft & Vervoort 1954, Karlsen K. 1962.). Our previous reports revealed that disappearance of some extra cellular materials was closely related to the fetal tooth bud degradation in the baleen whale (Ishikawa H. & Amasaki H. 1995, Ishikawa H. et al. 1999). Regression of deciduous tooth from the root part is induced by the activated odontoclast of the deciduous dental pulp in the common mammals (Sasaki T. et al. 1988, Ten Cate A.R. 1989). While the embryonic teeth buds of baleen whale is degraded gradually from whole part during fetal period (Ishikawa, H. & Amasaki H. 1995). It is not clear what kind of cells related to this degeneration of the baleen whale tooth bud and also not revealed the degradation mechanism of temporal fetal tooth bud in the baleen whale. Present immunohistochemical examinations reveal two types of specific immunocyte related to this degeneration of tooth buds in the Antarctic minke whale, Balaenoptera bonaerensis.

Materials and Methods: We used forty fetuses (body length 6.7-197cm) of Antarctic minke whales in the Japanese Whale Research Program under the Special Permit in the Antarctic Sea (JARPA) from 1993 to 2002. After routine histological procedures, we observed immunohistchemical expressions of the immunocyte markers; CD4, CD8, CD11, CD14, AI-1, and of the immunocyte functional markers as tissue digestive enzymes; mmp9, mmp13, triptase, type II carbonic anhydrase (CA2), acid phosphatase.

Results and Discussion: Tooth buds of Antarctic mink whales started to degenerate from the fetus of 53.8cm length. Almost of tooth buds have been degenerated before birth. The calcified dentin matrix was degenerated from the starting period as 65cm CRL fetus by the large sized odontoclast, which was immunopositive to CA2 and acid phosphatase antibodies. These cells also reacted to AI-1 (Macrophage marker), mmp9 and mmp13

Fig.1. Immunohistological microscopic image of AI1 antibody. Arrow indicates large sized odontoclast.



Fig.2. Immunohistological microscopic image of mmp9 antibody. Arrows indicates small sized macrophage like cells.

Fig.3. Immunohistological microscopic image of mmp13 antibody. Arrows indicates small sized macrophage like cells.

(gelatine and collagen digestion cells). Distributional pattern of these cells was spreaded over the outer surface of dentine matrix. While many number of small sized macrophage-like cells were distributed over the inner surface of the dentine space. These small cells were immuno reacted only to AI-1, mmp9 and mmp13, but not to CA2 and acid phosphatase (Fig.1, 2, 3, 4). Degenerating

Fig.4. Immunohistological microscopic image of type II carbonic anhydrase antibody. Arrow indicates large sized odontoclast.

tooth buds of the Mysticeti during the fetal periods was destructed by the two ways of other types of immunocytes; one was the large typed odontclast which is destructed the calcified dentine, and other small one was the macrophage like cells which might be destructed collagens and some matrix protein. Large number of later type cells might be quickly destructed huge volume of dentine matrix (proteoglycans and glycosaminoglycans in the dental pulp.

References: Dissel-Scherft,M.C.V. & Vervoort W. 1954. Development of the teeth in fetal Balaenoptera physalus (L.) (Cetacea, Mystacoceti). Proc. Kon. Akad. Wet., Amsterdam, C57:196–210. - Ishikawa H., Amasaki H., Dohguchi H., Furuya A. & Suzuki K. 1999. Immunohistological distributions of Fibronectin, Tenascin, Type I, III & IV Collagens, and Laminin during tooth development and degeneration in fetuses of minke whale, *Balaenoptera acutorostrata minke*. J. Vet. Med. Sci. 61:227-232. - Ishikawa H. & Amasaki H. 1995. Development and physiological degradation of tooth bud and development of rudiment of baleen plate in southern minke whale *Balaenoptera acutorostrata*. J. Vet. Med. Sci. 57:665-670. - Karlsen K. 1962. Development of tooth germs and adjacent structures in the whalebone whale (*Balaenoptera physalus* (L.). Hvalrådets Skrifter 45:5-56. - Sasaki T., Motegi N., Suzuki H., Watanabe C., Tadokoro K. Yanagisawa T. &. Higashi S. 1988. Dentin resorption mediated by odontoclasts in physiological root resorption of human deciduous teeth. Am. J. Anat. 183:303-315. - Ten Cate A. R. 1989. Physiologic tooth movement: eruption and shedding, p.337–365. In: Ten Cate A.R. (ed.), Oral Histology Mosby, St Louis.

INDEX TERMS: Immunocyto, tooth bud, development, Antarctic Minke Whale.

003. Cruz R.A., Santos C.F., Passos S.K., Belmonte D. Carneiro A.F.O. & Luz H.C.P. 2007. **Pulp alteration in a canine tooth of a cat (*Felis cattus*) detected by a routine radiography.** *Pesquisa Veterinária Brasileira 27(Supl.).* Clínica Escola de Medicina Veterinária, UCB, Rio de Janeiro, RJ 21021-020, Brazil. E-mail: drigow@predialnet.com.br

Introduction: The intra-oral radiography in the veterinary dentistry must be considered as a powerful tool to get to a diagnosis in the clinical practice. Some clinical or surgery decisions can be made just by signs of pain, appetites, time of occurrence of the trauma and owner's report. Although lots of mechanisms of investigation in dentistry nowadays, unfortunately they can't be applied in a veterinary patient. So, some radiological signs can be used to make a decision plan on a treatment. This paper intends to describe a case where a cat, with an enamel trauma and tooth displacement, had its pulp integrity evaluated by a intra-oral radiography.

Materials and Methods: A 3 years-old male cat (*Felis cattus*), non-breeded and non-castrated, had been taken to the Veterinary Dentistry Lab of Castelo Branco University (LOVE UCB/RJ) by the owners with a complaint of hiporexia and a discret loss of weight. The animal had been described as a peri-domicilliary pet, sometimes with soft tissue injuries. On the physical examination, there was no signs of pain or injuries, and it's left maxillary canine (element #204) could be observed with a rostral displacement in a comparison by the homologue. No gingivitis or stomatitis could be noted. There was a little loss of a piece of this tooth, and no terciary dentine reparison was detected. By the way, a radiography was made to evaluate the integrity of the tooth, just because the owners said that this tooth positioning must be considered normal, and since it was a kitten the tooth had this appearance and positioning. To proceed the radiography, an association of ketamine (10mg/kg, IV), diazepam (0.5mg/Kg, IV) and Atropine (0.04mg/Kg, IV) was administrated as a chemical containment. An intra-oral film was placed in parallel and an oblique-lateral maxillary technique was obtained (Gioso 2004). A FNX x-ray machine was used, with a combination of 60 Kvp/5mA's (Ticer 1987). After that, the film was developed in conventional ways.

Results: The analysis of the radiographs showed a visible difference about the pulp chamber between the left superior canine and the right one. A widening pulp can be observed in comparison with the homologue tooh, but no peri-apical radioluscence could be described. The diagnosis of pulp death was obtained. The enamel has a normal radiopacity, like the alveolar bone pattern that surrounded the tooth. In an specific examination, under anesthesia, no signs of mobility or gingivitis could be observed after periodontal exploration. After all this clinical and radiological findings, the endodontics was propose to the owners, after a explanation that this findings could be related to a traumatic factor in the animal, when it was a kitten (SIMON, 1892).

Discussion and Conclusions: The chemical containment used shows a good perform, making the radiography possible, even though the clinical examination. The use of diazepam in association was useful to restrain the tongue movements characteristic in cats with ketamin administration. The oblique-lateral technique to obtain a radiological image of the canine was very helpful, like tells Gioso, 2004. The size and pulp chamber visualization was very near to the tooth itself. A good contrast obtained by the technique related by Ticer (1987), was helpful to evaluate the pulp chamber, even if a conventional machine was used, showing that the radiological acknowledgement is essential to proceed this exam and its evaluation. The trauma itself could be a important etiologic factor for a pulp disease, like tell us Simon (1982). It's justified by the pulp death in a tooth that showed signs of trauma and a little avulsion process. For instance, the radiology in the veterinary dentistry routine is a useful tool, and its acknowledgement is of an essential way to have an excellence service.

References: Simon J.H.S. 1982. Patologia, p.283-306. In: Cohen S. & Burns R.C. (ed.), Caminhos da Polpa. Guanabara Koogan, Rio de Janeiro. - Ticer J.W. 1987. Técnicas Radiográficas na Prática Veterinária. 2ª ed. Roca, São Paulo. - Gioso M.A. 2003. Odontologia para o Clínico de Pequenos Animais.Editco Comercial, São Paulo.

INDEX TERMS: Radiography, cat, tooth.

004. Cruz R.A., Willi L.M.V., Santos C.F., Passos S.K., Valle L.G. & Paiva J.P. 2007. **Veterinary Dentistry in the graduation of veterinary students of Castelo Branco University (UCB/RJ).** *Pesquisa Veterinária Brasileira 27(Supl.).* Clínica Escola de Medicina Veterinária, UCB, Rio de Janeiro, RJ 21021-020, Brazil. E-mail: drigow@predialnet.com.br

Introduction: The graduation of a veterinarian currently asks for that the graduate be a critical, inserted individual knowledgeable of his part as a professional close to the society. In this context, during the academic life, some sources of our profession are presented to the students, being of their own choice the way to follow, either for vocation or as an opportunity, since they all have a generalist formation. It cannot be ignored that the profile of the education institution suffers direct influence from where it is located, suggesting a directed formation to such determined area, either it clinical in all its modalities, animal production or technology and inspection of animal origin products. However, it is observed that some sub-areas, especially at clinic discipline, due to its plurality, pass merely as topics when it could be seen as other discipline, and not only as prompt lessons or lectures. It is known, however, that the curricular grade, for many times, cannot support all disciplines considered as important for us. The present work has as objective to report as the Course of Veterinary Medicine of Castelo Branco University (UCB), Rio de Janeiro, is developing its activities in the area of Veterinary Dentistry Medicine, and its contribution to the formation of the involved academics.

Materials and Methods: The veterinary dentistry is inserted in different points of the course, applying itself the principle of the union between lots of disciplines. The first contact of the student with the subject happens at basic disciplines such as Anatomy and Physiology, where in a practical way he become able to develop agreement on the future importance of this area in his professional life. In the disciplines of Small Animal Medical Clinic, more specifically in the module of Neonatology and Pediatrics, the student develops the basic concepts of Prophylaxis, pointing out the importance of Pediatric Routine as a basic method for education in animal health to the owners. At this moment, they are also capable to identify related alterations of the development to the subject matter. Still in Medical Clinic, in the module of Diseases of the Digestive System, practical lessons with corpse use are given (deriving of the clinical routine of the Hospital), with the purpose of familiarization with the practical aspects of the oral cavity. Periodontic diseases are the keys at the boarding of teeth diseases, on which etiology, physiopathogeny, diagnoses, treatment and prophylaxis are argued. Diseases the resolution of which is merely surgical, as exodontics and endodontics, are again boarded in the Discipline of Clinical Surgery. Through practical lessons in the hospital routine or with the corpse use, the student has the chance to apply the theorical knowledge obtained in classroom. The *Laboratório de Odontologia*

Veterinária (LOVE/UCB) was created in 2004 at the Veterinary Medicine School of UCB, with the intention to create study groups and workshops for the students who were interested in the area, based on the necessity of a better graduation to the academics and the personal experience of the veterinarians dedicated to the study of the veterinary dentistry medicine (Cruz 2004). Since then, weekly meetings for scientific previously selected article and clinical cases of the Clinical School discussion, or practical training with cases of the routine take place supervised for professors and professionals of the Institution. Short-term courses are being developed as activities of LOVE, bringing different subjects of the area, and in addition a schedule for veterinary dentistry in the annual Academic Week of this institution was implemented.

Results: Understood as work with results in the long run, the boarding on dentistry in the Course of Veterinary Medicine starts to show repercussion by means of the learning interest. The search for participation in the study group, always surpassing the offered vacant number, the fast capacity of the groups of mini-courses, the choice of subjects related for accomplishment of Works of Conclusion of Course, and mainly in the intense commitment and devotion to solve the different clinical cases taken care of, that depend on study and update is an indicating of this interest. The work of the Laboratory of Veterinary Medicine Dentistry, Castelo Branco University (LOVE/UCB), currently starts to pass the borders of the Institution, being its mini-courses searched for students from other Institutions and professionals. The LOVE still stimulates its integrant through the offering of scholarships for course carried through by entities of classroom in partnership in the cession of the space of the University. We can cite as an initial result of this work the attendance made exclusively of academics, where a cat (*Felis cattus*), male, 2 years old, not spayed, was proven to have a traumatic opening of a oral-nasal communication next to the lingual face of maxillary teeth of the right hemi-arches after being hit by a car. The surgical procedure was supervised by the professors and veterinarians of UCB/RJ, being solved with the closing of the oral-nasal communication and reduction of the fracture using a splint technique. The animal began feeding with soft food about 24 hours after the intervention, and dry feeding about 36 hours after the surgery.

Discussion and Conclusions: Although the curricular lines of direction guided by the Ministry of Education, tell us that the graduate of a course of Veterinary Medicine must have a generalist graduation, and be able to act in the area of his profession, the growth of the sub-areas is undisputed and demanded for the work market. The Graduation Institution does not intend to graduate specialists, but it can stimulate the interest and introduce the student to its existence, leaving planted on them this small seed. The growth and the perfection of the Veterinary Medicine are a reality, and the professional who is aware of such fact, is unique for introducing on his routine many simple practices that demonstrate his update. A specialty can be inserted in the graduation of a student, without privileges, so that no other important area is forgotten, but in a way that the student can have his first contact with an area that could be his choice for the future. The reported case showed to the students the necessity to remain always up to date, studying and dedicating themselves to their area of interest, whatever it is, especially at veterinary dentistry medicine by many ethical reasons that surround it in our country, as said Gioso (2003).

References: Gioso M.A. 2003. Odontologia para o Clínico de Pequenos Animais. Editco Comercial, São Paulo. - Cruz R.A., Willi L.M.V., Santos C.F., Passos S. K. & Dantas F. F. 2004. Avaliação do grau de esclarecimento em relação ao serviço de odontologia veterinária com os clientes da Clínica Escola de Medicina Veterinária Dr. Paulo Alfredo Gissoni, VI CONPAVET / I COBOV, Santos, São Paulo.

INDEX TERMS: Veterinary dentistry, academics, school, Brazil.

005. Domingues-F. L.M., Ferreira J., Lopes F.M., Tymoszczenko A. & Gioso M.A. 2007. **Use of different times for temporary endodontic dressing cements in root canal therapy of induced pulp necrosis in dog's teeth**. *Pesquisa Veterinária Brasileira 27(Supl.).* Departamento de Cirurgia, Faculdade de Medicina Veterinária e Zootecnia, Universidade de São Paulo, São Paulo, Brazil. E-mail: lesliedf@usp.br

Introduction: Endodontic treatment of necrotic pulp is intended to reduce infection to a level that allows the body to respond successfully to the bacterial load. Tanomaru Filho (2002) and Holland et al. (2003) observed by histopathological evaluation that tissue repair of apical and periapical regions was more effective where teeth were treated with calcium hydroxide (double session) compared to definitive obturation (single session). Other studies (White et al. 1997, Komorowski et al. 2000) showed the importance of temporary endodontic dressing material aimed at bacterial elimination in the apical delta region. Calcium hydroxide has both a bactericidal effect and neutralizes endotoxins (Savafi et al. 1994). The present study examines the persistence of microorganisms in the root canal, dentine tubules and apical delta of dog's teeth with induced pulp necrosis after two sessions of endodontic treatment, using temporary endodontic dressing cements for different periods of time.

Materials and Methods: The present study was performed in four mixed breed dogs. The second, third and fourth lower premolar teeth and the second and third upper premolar teeth of the maxilla were used at the experiment. Intraoral radiographies were performed every 15 days, until day 120. During these procedures the animals were anesthetized. Surgery procedure: At day 0, the animals were anesthetized and periapical radiographs of all experimental teeth. Thirty of the forty teeth were opened at the crown to expose the pulp chamber. The remaining 10 teeth were kept intact during this first phase. At the end of the first phase the animals were medicated with anti-inflammatory drugs to control the inflammatory reaction and pain. After 60 days the root canals in the 30 opened teeth were filled. At this time, the 10 intact teeth were opened to expose the coronary chamber, consisting in the control group. The classical

technique of root canal therapy was performed in this study. The 80 roots were divided into three experimental groups: Group I: control; Group II: calcium hydroxide/PMCC for 7 days, followed by zinc oxide eugenol paste and gutta-percha; Group III: calcium hydroxide/PMCC for 15 days, followed by zinc oxide eugenol paste and gutta-percha and Group IV: calcium hydroxide/PMCC for 30 days, followed by zinc oxide eugenol paste and gutta-percha. After 120 days, the teeth were extracted *en bloc* (teeth and periodontal tissue). The specimens were fixed and demineralized for preparation of histological sections.

Results: Histopathological analysis revealed intense inflammatory process in the periapical area. The pattern of inflammatory response was similar in all groups. Thus the root canal exposure to contamination with induced pulp necrosis was sufficient to promote the periapical inflammatory process. The presence of bacteria in the apical delta and dentine tubules were analyzed in all groups. Longer periods of calcium hydroxide lead to a lower percentage of bacteria in these regions. Although even at 30 days of temporary endodontic dressing there was still evidence of microorganisms. Besides the delta and dentine tubules, inside the root canals were also evaluated. A complete removal of microorganisms could be observed at day 7. Only the control group presented microorganisms inside the root canal. When evaluating bacteria in the dentine tubules, located at the apical third, there was a significant reduction of bacteria proportional to the period of the temporary endodontic dressing cements. However even after 30 days of exposure bacteria could still be observed in this region.

Discussion and Conclusion: The longer the period of temporary endodontic dressings were left in the root canal, the deeper the effect penetrated and the more severe the reaction; reaching periapical alveolar bone at 30 days. This would be expected since calcium hydroxide causes an inflammatory response when used alone, but in association with PMCC the response is more severe since PMCC is more aggressive to tissues. The use is recommended by some authors for short periods. The histomicrobiological analysis demonstrated that the presence of temporary endodontic dressing reduces microbial loading, agreeing with Holland et al. (2005) and Vianna et al. (2005). The control group showed the highest concentrations of microorganisms. There was a decrease proportional to the exposure time to the temporary endodontic dressing cements in the root canal. This agreed with Vianna et al. (2005) in demonstrating the bactericidal effect of calcium hydroxide, and showed that PMCC was an effective power over the studied periods. Significantly however, even after 30 days of treatment microorganisms were still found in some of the studied regions. The periods (7, 15 and 30 days) of temporary endodontic dressing cement in the root canal were not sufficient to totally eliminate bacteria in all regions, bacteria were present in the dentine tubules and apical delta. Complete removal is considered essential for a good prognosis of endodontic treatment. Other studies are necessary in order to establish an efficient endodontic treatment.

Acknowledgments: To FAPESP for funding this Project.

References: Holland R., Otoboni Filho J.A., De Souza V., Juvenal Rery M., Bernabé P.F.E. & Dezan E. 2003. A comparison of one versus two appointment endodontic therapy in dogs' teeth with apical periodontitis. J. Endodon. 29(2):121-125. - Komorowski R., Grad H., Wu X.Y. & Friedman S. 2000. Antimicrobial substantivity of chlorhexidine-treated bovine root dentin. J. Endodon. 26:315-317. - Safavi K.E. & Nichols F.C. 1994. Alteration of biological properties of bacterial lipopolysaccharide by calcium hydroxide treatment. J. Endodon. 20:127-129. - Sjögren U., Fidgor D., Persson S. & Sundqvist G. 1997. Influence of infection at the time of root filling on the outcome of endodontic treatment of teeth with apical periodontitis. Int. Endodon. J. 30:297-306. - Tanomaru Filho M., Leonardo M.R. & Da Silva L.A.B. 2002. Effect of irrigation solution and calcium hydroxide root canal dressing on the repair of apical and periapical tissues of teeth with periapical lesion. J. Endodon. 28(4):295-299. - White R.R. 1997. Residual antimicrobial activity after canal irrigation with chlorhexidine. J. Endodon. 23:229-231.

INDEX TERMS: Apical delta, endodontic, gutta-percha, camphorated paramonochlorophenol, microorganisms, dogs.

006. Domingues-F. L.M., Lopes F.M., Ferreira J., Gioso M.A. & Padilha Filho J.G. 2007. **Comparative study of bactericide and tissue repair effect of calcium hydroxide with and without PMCC in dental structure of dogs**. *Pesquisa Veterinária Brasileira 27(Supl.)*. Departamento de Cirurgia, Faculdade de Medicina Veterinária e Zootecnia, Universidade de São Paulo, São Paulo, Brazil. E-mail: lesliedf@usp.br

Introduction: The calcium hydroxide is a material with antibacterial properties and it also induces the formation of a dentine bridge. Calcium hydroxide is usually recommended for covering exposed pulp (Holland et al. 1999, Melo 1998, Leonardo & Leal 1998). Holland et al. (2005) and Sipert et al. (2005) proposed studies to observe the repair process of dogs' teeth after the filling of the pulp cavity. They concluded that the cement of the calcium hydroxide promoted better process of apical repair. Although the antibacterial activities of the calcium hydroxide on anaerobic microorganisms have shown effectiveness, it was not active on all of the present aerobic bacteria in the root canal (Chong & Pitt Ford 1996). The association of calcium hydroxide plus camphorated paramonochlorophenol (PMCC), proposed by researchers, had the aim to increase the bactericidal power of the calcium hydroxide, inducing mineralized tissue formation on the tooth apex and resulting in better repair process. Among the antiseptic as root canal dressing, PMCC always offered better results as bactericidal. Although effective in this aspect, is also considered to be a potent cytotoxic. For some researchers the cytotoxity of PMCC is larger than its antibacterial action. However, the association of PMCC to calcium hydroxide has shown great effectiveness in bacteria elimination and irritation reduction (Vianna et al. 2005). The present study aimed to compare the bactericidal effect and the power of tissue repair of the calcium hydroxide, associated or not to the camphorated paramonochlorophenol (PMCC), in the root canal, dentine tubules and apex of teeth of dogs with pulpar necrosis induced experimentally.

Materials and Methods: Four dogs were used. Second, third and fourth lower premolar teeth and second and third upper premolar teeth were used, in a total of 28 teeth, totalizing 56 roots. All animals were submitted to general anesthesia and periapical radiographies were performed in every teeth involved in the study. Nineteen of the 28 teeth were opened on the crown to expose the pulp canal. The remaining 9 teeth were maintained intact. At the end of the first session, anti-inflammatory administration was performed in all dogs in order to control inflammation and pain. The animals were submitted to intra-oral radiographies control every 15 days, totalizing 60 days of pulp exposure, under general anesthesia. At day 60 the animals were anesthetized for root canal obturation of the 19 opened teeth in the first phase, and it was performed the coronary opening of the 9 teeth remaining serving as control. The chemical-biomechanical instrumentation (filing) was accomplished through the classic technique. The studied materials were applied and distributed in groups: Group I: calcium hydroxide paste; Group II: calcium hydroxide plus camphorated paramonochlorophenol paste; Group III: control. The animals were accompanied with intra-oral radiographies under general anesthesia, every fifteen days. At day 120, the teeth were extracted in block (teeth and periodontal tissue). The blocks were fixed, demineralized and histological evaluation was performed with hematoxilin-eosin staining. The Brown & Hopps coloration was also realized to evidence microorganisms.

Results: Group III, the control, should contain largest concentration of inflammatory cells, being supposed that most of their samples would be classified as severe. However, Group I presented equivalent number of altered roots. The Group II showed part of the roots with moderate inflammatory infiltrated, suggesting that the calcium hydroxide plus PMCC promoted better inhibition of inflammation, reflecting larger bactericidal activity and causing a faster repair process. It was also evaluated the presence of bone resorption (BR), cementum resorption (CR), and necrotic tissue in apex (N). The Groups I and II presented similar patterns and Group III obtained the largest percentile for all the variables. It was also verified the presence or absence of microorganisms in the groups. Group I was the most effective in the elimination of bacteria, because it showed the smallest percentile of microbial presence, followed by Groups II and III. The last one obtained the largest bacterial concentration. Regarding group I, microorganisms were in larger number in the dentinal tubules followed by other areas. In Group II, bacteria were observed in the apex, dentinal tubules and, lacunas cementum, distributed among those areas. Contamination was detected in all areas in Group III, and just the apex was absent of bacteria. The fact suggests that exposure time to the oral cavity was short. Bacteria probably take more time to colonize the apex.

Discussion and Conclusion: Comparing the results obtained from histological and histomicrobiological analysis we can infer that the calcium hydroxide plus PMCC showed low intensity of inflammatory infiltration and the smallest presence of bone resorption and cementum areas, being effective in the process of tissue repair. However, the association was not so effective as bactericidal, because it allowed bacteria to penetrate in the apex, and not being efficient in elimination of microorganisms. The calcium hydroxide alone was the least effective in all parameters. Other studies evidenced its effectiveness in the elimination of anaerobic microorganisms, and not of aerobics, besides the effect of not being irritant to tissues. This study can infer that the method of application the calcium hydroxide plus distilled water was not efficient, because the results obtained in this group was similar to those observed at the control group (not treated). Further studies should be accomplished with long term follow up of the animals.

Acknowledgements: Fapesp for funding this project.

References: Chong B.S. & Pitt Ford T.R. 1992. The role of intracanal medication in root canal treatment. Int. Endon. J. 25:290-297. - Holland R. et al. 1999. Reparação dos tecidos periapicais com diferentes formulações de $Ca(OH)_2$: estudo em cães. Ver. Assoc. Paul. Cir. Dent. 53:27-31. - Melo L.L. 1998. Traumatismo Alvéolo-Dentário: etiologia, diagnóstico e tratamento. Artes Médicas, São Paulo: EAP-APCD, 9. 287p. - Leonardo M.R & Leal J.M. 1998. Endodontia: tratamento de canais radiculares. 3ª ed. Panamericana, São Paulo. 902p. - Holland R., Sant'Anna Junior A., Souza V., Dezan Junior E., Otoboni Filho J.A, Bernabé P.F.E., Nery M.J. & Murata S.S. 2005. Influence of apical patency and filling material on healing process of dogs' teeth with vital pulp after root canal therapy. Braz. Dent. J. 16(1):9-16. - Sipert C.R., Hussne R.P., Nishiyama C.K & Torres S.A. 2005. *In vitro* antimicrobial activity of fill canal, sealapex, mineral trioxide aggregate, Portland cement and endorez. Int. Endodon. J. 38:539-543. - Vianna M.E., Gomes B.P.F.A., Sena, N.T., Zaia A.A., Ferraz C.C.R. & Souza Filho F.J. 2005. *In vitro* evalutation of the susceptibility of endodontic pathogens to calcium hydroxide combined with different vehicles. Braz. Dent. J. 16(:3):175-180.

INDEX TERMS: Apical delta, endodontics, calcium hydroxide, microorganisms, camphorated paramonochlorophenol, dog.

007. Domingues-F. L.M., Lopes F.M., Ferreira J., Gioso M.A. & Padilha Filho J.G. 2007. **Histopathological and histomicrobiological study of root canal therapy medication, comparison of calcium hydroxide versus gutta-percha with zinc oxide/eugenol in dog's teeth.** *Pesquisa Veterinária Brasileira 27(Supl.):00-00.* Departamento de Cirurgia, Faculdade de Medicina Veterinária e Zootecnia, Universidade de São Paulo, São Paulo, Brazil. E-mail: lesliedf@usp.br

Introduction: During the treatment of chronic periapical endodontic lesions the complex internal anatomy of teeth contributes to therapy failure with the millions of dentine tubules and their numerous ramifications (Wada et al. 1998) having both aerobic and anaerobic microbial contamination (Almeida, 1993; Leonardo et al. 1993). With endodontic treatment in dogs microorganisms are the primary consideration since bacteria in the dentine tubules, foramina and apical delta seem to be related to treatment failure with the apical delta being the most important of these structures (Gioso 2003). Holland et al. (2005) and Sipert et al. (2005) observed the process of tooth repair in dogs after the filling the canal, concluding that calcium hydroxide cement was the best material to induce apical repair. The purpose of this study is to evaluate the presence of microorganisms in the root canal, dentine tubules and especially in the apical delta in the teeth of dogs with experimentally induced pulp necrosis. The intention is

to test the antimicrobial and tissue repair efficacy of gutta-percha with zinc oxide/eugenol cement compared with calcium hydroxide.

Materials and Methods: The present study was performed in four mixed breed dogs. The second, third and fourth lower premolar teeth of both sides and the second and third upper premolar teeth of the left side of the maxilla were used at the experiment. Intraoral radiographies were performed every 15 days, until day 120. During these procedures the animals were anesthetized. At the end of the first phase the animals were medicated with anti-inflammatory drugs to control the inflammatory reaction and pain. Surgery procedure: At day 0, the animals were anesthetized and periapical radiographs of all experimental teeth. Twenty-one of the third-two teeth were opened at the crown to expose the pulp chamber. The remaining 11 teeth were kept intact during this first phase. After 60 days the root canals in the 21 opened teeth were filled. At this time, the 11 intact teeth were opened to expose the coronary chamber, consisting in the control group. The classical technique of root canal therapy, described by Harvey & Emily (1993), was performed in this study. The 64 roots were divided into three experimental groups: Group I (22 roots): gutta-percha with zinc oxide/ eugenol cement; Group II (20 roots): calcium hydroxide paste; Group III (22 roots): control. After 120 days, the teeth were extracted e*n bloc* (teeth and periodontal tissue). The specimens were fixed and demineralized for preparation of histological sections. The sectioned specimens were dyed with hematoxylin-eosin (HE) and Brown & Hopps (1973) methods were used to visualize the microorganisms. The non parametric variability method of the Kruskal-Wallis was used for statistical analysis and the results were then compared by the Dunn multiple comparison test.

Results: Histological analysis of the periapical region showed areas of inflammation and resorption of the apical cement, with dentine structures exposure in many cases. As expected Group III (control) had the highest level of inflammation, with the majority of the sample classified as "severe". However, Group II presented the same number of inflamed roots suggesting that calcium hydroxide treatment did not result in inflammation reduction. The bacterial data showed that calcium hydroxide (Group I) was also a less effective anti-microbial treatment than zinc oxide/eugenol cement with gutta-percha cones (Group II). Bone resorption (RO), cement resorption (RC) and necrotic tissue at the apical delta (TN) were also analysed. Groups I and II had a similar response with Group III showing the highest level of all three parameters. The tested groups (I and II) had a high index of RO, RC and TN but with a low percentage, due to the presence of low levels of inflammatory infiltrate. Group I was the most efficient at reducing bacteria followed by Groups II and III with the control (Group III) having the greatest concentration of bacteria. The results were submitted to the non parametric variability method of the Kruskal-Wallis and then tested by the Dunn multiple comparison test, the results were significant ($p>0.05$) and the average variability was significantly higher as expected.

Discussion and Conclusion: The depth of inflammation and the extent of bone resorption revealed by histopathological analysis indicated a long term infection. This study suggests different antibacterial activity for each substance used. Sixty days after root canal filling, an inflammatory reaction was evident in all samples but with different levels of intensity. According to other researchers the process used for histological staining results in a reduction in the observed bacterial level within the tissues. The apparent absence of gram-negative bacteria in this study could be a result of the complete disintegration of these microorganisms at the acid stage of demineralization. Group I had the lowest bacterial concentration but the greatest concentration of bacteria was in the apical delta, the most difficult region for the test materials to access. This fact could be explained by the viscosity of the zinc oxide/eugenol cement reducing its ability to penetrate the foramina. By contrast this group was most effective at eliminating bacteria in the dentine tubules. Overall this group had the lowest contamination of bacteria. In Group II microorganisms were found in the dentine tubules and in other regions showing that calcium hydroxide alone did not penetrate the dentine tubules well or was a less effective bactericidal agent. The period of time of oral exposure was short and therefore bacteria probably need more time to reach the apical delta. The gutta-percha with zinc oxide/eugenol cement showed effective antibacterial activity and the calcium hydroxide was less effective this parameter. The conclusion of this study is that the gutta-percha with zinc oxide/eugenol is a better protocol to fill the root canal in dogs.

Acknowledgments: FAPESP for funding this Project.

References: Almeida W.A. 1993. Diferentes técnicas de tratamento de canais radiculares em dentes de cães com reação periapical crônica: estudo radiográfico e histobacteriológico da reparação apical e periapical. Dissertação de Mestrado em Endodontia, Faculdade de Odontologia, Universidade Estadual Paulista, Araraquara. 155p. - Brown J.H. & Hopps H.C. 1973.Staining of bacteria in tissue sections: a reliable gram stain method. Am. J. Clin. Pathol. 60(2):234-40. - Gioso M.A. 2003. Odontologia Veterinária: pequenos animais. 2ª ed. FMVZ-USP, São Paulo. 45p. - Harvey C.E. & Emily P.P. 1993. Small Animal Dentistry. Mosby -Year Book, St Louis. 413p. - Holland R., Sant'Anna Junior A., Souza V., Dezan Junior E., Otoboni Filho J.A., Bernabé P.F.E., Nery M.J. & Murata S.S. 2005. Influence of apical patency and filling material on healing process of dogs' teeth with vital pulp after root canal therapy. Braz. Dent. J. 16(1):9-16. - Leonardo et al. 1993. Histological evaluation of therapy using a calcium hydroxide dressing for teeth with incompletely formed apices and periapical lesions. J. Endodon. 19:348-352. - Sipert C.R. et al. 2005. *In vitro* antimicrobial activity of fill canal, sealapex, mineral trioxide aggregate, Portland cement and endorez. Int. Endodon. J. 38:539-543. - Wada M et al. 1998. Clinical study of refractory apical periodontitis treated by apicectomy. Part I. Root canal morphology of resected apex. Int. Endodon. J. 31:53-56.

INDEX TERMS: Apical delta, endodontic, gutta-percha, calcium hidroxide, microorganisms, dogs.

008. Domingues-F. L.M., Lopes F.M., Ferreira J., Gioso M.A. & Padilha Filho J.G. 2007. **Prevalence of microorganisms in dental structures of dogs after different endodontic treatment**. *Pesquisa Veterinária Brasileira 27(Supl.).* Departamento de Cirurgia, Faculdade de Medicina Veterinária e Zootecnia, Universidade de São Paulo, São Paulo, Brazil. E-mail: lesliedf@usp.br

Introduction: In the endodontic treatment of dogs, the dentinary tubules are not instrumented during the chemical-mechanical preparation. The association of calcium hydroxide plus camphorate paramonochlorophenol (PMCC), proposed by other researchers, is thought to increase the bactericide action of calcium hydroxide, inducing the

formation of mineralized tissue on the tooth apex and cause a better tissue repair (Leonardo & Leal 1998, Soares 1999). Vianna *et al* (2005) accomplished an in vitro research to investigate the microbial activity of calcium hydroxide (CH) combined with different vehicles, concluding that CH plus camphorate paramonochlorophenol (PMCC) became highly effective in the elimination of anaerobes bacteria. This study intended to evaluate the prevalence of microorganisms in the root canal, dentinary tubules and, mainly, in the apical delta of teeth of dogs with pulpar necrosis induced experimentally, through the gutta-percha with zinc oxide and eugenol and calcium hydroxide plus camphorated paramonochlorophenol.

Materials and Methods: Four dogs were used. For the procedure the seconds, third and fourth inferior premolars and the second and third superior premolars were used, in a total of 32 teeth with 64 roots. Periapical radiographies were accomplished of all the teeth involved in the study, under general inhalatory anesthesia. Initially twenty-one of the thirty-two teeth were opened in the crown, in order to expose the pulp chamber, having the remaining teeth (11) intact in this first phase. At the end of the first session antiinflammatory was administered, in order to control the inflammation and pain process. The animals were submitted to intra-oral radiographic control, every 15 days, in a total of 60 days of pulp exposure. After 60 days the animals were again submitted to anesthesia for filling the canal of the 21 initially opened teeth. Crown opening of the 11 teeth, which did not have their canals exposed in the first session, was done, serving as control teeth. The chemical-biomechanical preparation was accomplished through the classical technique. All of the roots were divided in 3 experimental groups: Group I: Gutta-percha with zinc oxide and eugenol; Group II: calcium hydroxide paste plus camphorated paramonochlorophenol and Group III: control. After the 120 days of study, the teeth were extracted in block (teeth and periodontal tissue). After the extraction, the blocks were fixated and demineralized. Once demineralized the material was processed for histological examination to determine the presence of microorganisms.

Results: In this study it could be verified after 120 days the presence of inflammatory infiltrate in all the samples, only differing in the level of intensity, suggesting that there was difference in the antibacterial activity of each used substance. Group III, which was not treated, should contain the largest concentration of inflammatory cells, supposing that most of its samples would be classified as severe. Groups I and II had a very similar behavior in relation to the type of reaction, since the percentage of severe inflammation was similar, differing only in the distribution between soft and moderate. Group II had a high percentage of soft infiltration and group I presented a more moderate infiltrate. The histomicro-biological analysis verified the presence or absence of microorganisms in the studied group. It was observed that Group I was the most effective in the elimination of bacteria, since it presented the lowest percentage of microbial presence, followed by Groups II and III, the latter obtained the largest bacterial concentration. Localization of bacteria was studied in all groups. This evidenced the presence of microorganisms not only in the root canal, but also in the dentinary tubules and root ramifications.

Discussion and Conclusion: When comparing the results it can be concluded that the gutta-percha with zinc oxide and eugenol was effective reducing periapical lesion, being directly related to the inflammatory process that in this case was mostly found in a moderated form. However, it was the material that obtained better results in the elimination of bacteria. The fact of the low number of microorganisms, in contrast with the presence of severe periapical lesion can be supported by the verification done by other authors that, besides the bacterial presence, the process of bacterial death stimulates themselves to liberate lipopolisacarides (LPS), which are constituents of the cellular wall of gram-negative bacteria. These LPS have biological effects such as the increase of the inflammatory reaction. In other words, bacterial elimination can often exacerbate the inflammatory process delaying the tissue healing. The association was not effective in the antibacterial effect, since it allowed the bacteria to penetrate even in apical delta, where it was not efficiently eliminated. It is emphasized the effectiveness observed in groups I and II. Both showed good results in different aspects. It is suggested that it is really necessary the association of both materials, being the dog's teeth treated in two sessions, using calcium hydroxide plus PMCC as temporary endodontic dressing, and gutta-percha with zinc oxide and eugenol as the definitive obturation material. However new studies are necessary to prove this possible synergistic effectiveness.

Acknowledgements: To Fapesp for funding this research.

References: Soares J.A. 1999. Estudo microbiológico dos canais radiculares, histopatológico e histobacteriológico dos tecidos apicais e periapicais, em função do preparo biomecânico e de dois curativos de demora à base de hidróxido de cálcio, utilizados em dois períodos de avaliação, no tratamento endodôntico de dentes de cães, com reação periapical crônica induzida. Dissertação de Mestrado em Endodontia, Faculdade de Odontologia, Universidade Estadual Paulista, Araraquara. 453p. - Leonardo M.R. & Leal J.M. 1998. Endodontia: tratamento de canais radiculares. 3ª ed. Panamericana, São Paulo. 902p. - Vianna M.E., Gomes B.P.F.A., Sena N.T., Zaia A.A., Ferraz C.C.R. & Souza Filho F.J. 2005. *In vitro* evalutation of the susceptibility of endodontic pathogens to calcium hydroxide combined with different vehicles. Braz. Dent. J. 16(3):175-180.

INDEX TERMS: Apical delta, endodontic, gutta-percha, microorganisms, camphorate paramonochlorophenol, dog.

009. Dotorovici B.M., Lima E.A.B., Santos L.J., Seppa G.S., Souza L.R.V., Bastos P.N., Coutinho P. & Menezes C.M.C. 2007. **Traumatic avulsion of maxillary canine with mesio-buccal dislocation and fracture of the vestibular wall of the alveolar bone**. *Pesquisa Veterinária Brasileira 27(Supl.).*
Policia Militar do Rio de Janeiro, CIPM Cães, Rio de Janeiro, Brazil. E-mail: hdiagnostico@ibest.com.br

Introduction: The lesion occurred in a 7-year-old German shepherd dog during a training of the Military Police in Rio de Janeiro. The element 104 was completely displaced from its alveolus (Westphalen et al. 2007) due the fracture of the vestibular wall of the alveolar bone. According to Eisenmerger & Zetner (1985) the function of the canines is arresting and laceration and has a power of 500 kg/cm².

Materials and Methods: The animal received Acepromazyne

0.03mg/kg i.v. as sedative; induced with Thiopental sodium 12.5mg/kg and maintenance with Enfluorano. It also received Bupivacain with vaseconstrictor in the infra-orbital foramen. The analgesia after the surgery was done with Meloxican 0.1mg/kg for 7 days. After radiographs with lateral incidences, the tooth was replaced into the alveolus and the fractured alveolar bone was reduced; the necrotic tissue of the junctional epithelium at the palatal region around the tooth was removed. The gingival mucous was sutured with nylon 3.0, and the splint was made with an orthodontic wire Twist-flex 0.80mm, supported by the elements 101, 102 and 103; it was also stabilized and involved with an acrylic self-polymerized dripping.

Results: A final radiograph was taken showing a very good bone coaptation, the pain was under control and the dog was able to eat his food softened with water. The infection was controlled with Cefalexin-500mg 12/12 hours during 7 days.

Discussion and Conclusion: When a tooth is avulsed, attachament damage and pulp necrosis occurs, but if the periodontal ligament is left attached to the root surface, it does not dry out and the consequences of tooth avulsion are usually minimal (Trope 2002). A reattachment between the tooth and the alveolar socket to be successful, the cells of the periodontal ligament which are attached to the root of the tooth must remain vital; an ideal splint is one that is quickly and easily constructed, passive, comfortable and durable enough to last the length of time needed for splinting (Dewhurst et al. 1998). Because dental acrylic hardens by an exothermic reaction, it is important to minimize injury to the gum by washing during the application if the splint; interdental acrylic fixation is a versatile technique and may be applied to a variety of oral injuries (Muir & Gengler1999). The control of the tooth and the alveolar bone with radiographs is made because, if a fistula develops, an endodontic treatment will be the next procedure. The dog has already returned to its normal life.

References: Westphalen V.D. et al. 2007. Knowledge of general practioner dentists about the emergency management of dental avulsion, in Curitiba, Brazil. Dent. Traumatol. 23:68. - Eisenmerger E. & Zetner K. 1985. Diente y encia, p.15-38. In: Idem (ed.), Odontologia Veterinaria. Ediciones, Barcelona. - Trope.M. 2001. Clinical management of the avulsion tooth: present strategies and future directions. Dent. Traumatol. 17:180-184. - Dewhurst. S.N., Mason C. & Roberts G.J. 1998. Emergency treatment of orodental injuries: a review. Brit. J. Oral Maxillofacial Surg. 36:165-175. - Muir P. & Gengler W.R. 1999. Interdental acrylic stabilization of canine tooth root and mandibular fractures in a dog. Vet. Rec. 144:43-45.

INDEX TERMS: Tooth avulsion, avulsion of a maxillary canine, fracture of alveolar bone.

010. Filla S.C.F. & Filla J.C. 2007. **Qualified clients prospection in animal dentistry: a successful experience.** *Pesquisa Veterinária Brasileira.* Pró-Animal Clínica Veterinária, Londrina, PR Cep 86046 430 Brazil. E-mail: pro-animal@uol.com.br

Introduction: Client prospecting is a process of identifying potential clients for the services provided. It is divided in three categories: referrals, potential clients and qualified potential clients, the latter being the most difficult to identify but the one with the best results due to their buying trends, power and autonomy (Junior & Peter 2000). Thus it is extremely important to create an adequate market positioning for the service provided to guarantee customer loyalty (Cobra & Zwarg 1987). Kotler (1999) stresses that a potential client will choose the supplier with the most attractive value-added proposal, after having evaluated all the physical effort, time spent and psychological distress involved in the proposal. The objective of this work is to present a successful strategy developed to attract qualified clients.

Materials and Methods: 133 animal dental care records filled during the period of March 2003 and June 2006 were revised and information regarding date of admission for treatment and animal origin were tallied. The objective was to assess the impact of one event realized in March 2005 on the increase in the number of dentistry cases, services provided through referrals, and companies or professionals that started to recommend the Pró-Animal Clinic Services. After analyzing the regional market, two groups of organizations were identified as the main marketing channels: animal clinics and higher education institutions that provide veterinarian services. Veterinarians from these institutions are considered main influencers. The strategy involved helping these veterinarians to recognize main oral cavity alterations, treatment possibilities, and getting their recommendations for dental services. Training sessions consisted of a lecture-dinner when the value-added offer was introduced: consultation fees would be waived for patients referred, in writing, by a veterinarian, and the Clinic ethical obligation to send the patient back to the veterinarian responsible for the patient together with his dental records, X-ray documentation and a letter describing all the procedures. The objective of this proposal was to value the diagnosis made by the veterinarian responsible for the animal, emphasizing that this is an exclusive benefit he provides his client with. Special care was given to the preparation, dissemination and organization of the event, when the ethical conduct and reliability of the Pro-Animal Clinic Services were reinforced through a clear and transparent language. All participants were personally invited to show their importance. The lecture was divided into two parts. First, the history of Clinic's involvement with animal dentistry was chronologically presented to show all the effort and investment made on professional development and the necessary infrastructure. Next, all the necessary tools to help participants identify in their patients the most frequent dental problems, as well the benefits of having the services of a specialized professional were emphasized.

Results: The action resulted in a 124% increase in dental consultations, 183% increase in the number of consultation through referrals, and in a 114% increase in the number of veterinarians that started recommending the Clinic's services.

Discussion and Conclusion: The Pró-Animal Clinic in Londrina, Paraná, Brazil has provided dental care services for 6 years and has developed many ways to prospect clients such as ads and articles in newspapers, interviews on TV and mail shots with very low return on the investment. Results have shown that the event was successful in creating an adequate image for the company, stressing the Clinic's capacity to carry out the proposed services , which increased significantly the number of referrals. The choices of specific channels and

influencers as well as of the value to be added to services were adequate to prospect qualified clients.

References: Cobra, Marcos H. Nogueira & Zwarg, F. Arnaldo 1986. Marketing de Serviços: conceitos e estratégias. McGraw-Hill, São Paulo, p.126-131. - Churchill, Gilbert A. & Peter, Paul 2000. Marketing: criando valor para o cliente. Saraiva, São Paulo, p.512-513. - Kotler P. 1999. Marketing para o Século XXI: como criar, conquistar e dominar mercados. Futura, São Paulo, p.81-86

INDEX TERMS: Prospection in animal dentistry; qualified clients , value-added proposal.

011. Filla S.C.F. & Gonzáles J.R.M. 2007. **Type 3 malocclusion with type B lesion in a 10-year-old poodle: a case study**. *Pesquisa Veterinária Brasileira 27(Supl.).* Clínica Veterinária Pró-Animal, Londrina, PR, Brazil. E-mail: pro-animal@uol.com.br

Introduction: Malocclusions in dogs are common and are classified in Types 0, I, II and III (Hennet et al. 1992, Harvey & Emily 1993). Several orthodontics adjustment methods have been recommended to malocclusion based on the etiology, animal age and type (Legenfre 1994). If not treated early, malocclusions can cause chewing alterations, tooth wear, soft tissues trauma, periodontal diseases and tooth fractures.(Shi et al. 1997, Wiggs & Lopprise 1997, Hallmon 2001). In these cases malocclusions must be adjusted and its consequences treated. The objective of this work is to report on the treatment of enamel and dentine lesions with tooth pulp exposure due to a Type III malocclusion late diagnosis in a 10-year-old poodle.

Materials and Methods: A 10-year-old poodle with tooth enamel lesions on the right upper canine tooth was seen at the Clinic. Clinical tests showed that the right lower canine was occluded towards the right upper canine, touching it lightly and producing an enamel lesion. X-ray analysis classified the lesion as Type B (Harvey & Emily 1990), involving the dentine and exposing the pulp. Due to the pulp exposure, the therapeutic procedure adopted was the penetration of disinfectant into the upper canine, filling it with zinc oxide, eugenol and gutta-percha and restoring the amalgam. A pulpectomy and tooth crown amputation followed by root canal filling with zinc oxide and eugenol and amalgam restoration were carried out due to the malocclusion and animal age.

Results: The right lower canine crown reduction avoided the occlusion of these teeth towards the right upper canine, preventing the development of the problem. Endodontic treatment of the right upper canine treated the focus of infection and the source of pain thus improving the life quality of the animal.

Discussion and Conclusion: Malocclusion late diagnosis led to an occlusion trauma with tooth pulp exposure (Brine 1999). Under an early diagnosis, this problem would have been prevented and the root canal treatment of the right lower canine unnecessary. In this case, a root canal treatment or a crown amputation of the right lower canine and a pulpotomy would be sufficient (one intervention only). A late diagnosed malocclusion requires two or more procedures: an orthodontic and an endodontic or crown amputation, pulpectomy and endodontic treatment. In this case, the age of the animal, its aggressive behavior and cardiac alterations led to the non-adoption of the orthodontic treatment since the use of orthodontic braces would be more complex and demand more anesthesia. Findings from this study showed that the late diagnosis of a malocclusion may lead to endodontic alterations, increase in the number of procedures and prolonged suffering (Yu 2004, De Simoi 2006).

References: Brine E.J. 1999. Endodontic disease of the mandibular first molar tooth secondary in a yong Shetland sheepdog. J. Vet. Dent. 16(1):15-18. - De Simoi A. 2006. Complications of mandibular brachygnathism in a North African leopard. J. Vet. Dent. 23(2):89-95. - Hallmon W.W. 2001. Occlusal trauma - periodontal concers. Tex. Dent J. 118(10):956-60. - Harvey C.E. & Emily P.P. 1993. Small Dentistry. Mosby, Philadelphia. - Hennet P.R., Harvey C.E. & Emily P.P. 1992. The Angle classification system of malocclusion: is it appropriate for use in veterinary dentistry? J. Vet. Dent. 9(3):10. - Legendre L.F. 1994. Bilateral vital pulpotomia as a treatment of class 2 malocclusion. Can. Vet. J. 35(9):583-585. - Shi Y., Wang J. & Cao C.. 1997. Clinical studies on pulpitis and periapical periodontitis caused by traumatic occlusion. Zhonghua Kou Qiang Yi Xue Za Zhi 32(1):23-5. - Wiggs R.B. & Lobprise H.B. 1997. Veterinary Dentistry: principles and practice. Lippencott-Raven, Philadelphia. - Yu C.Y. 2004. Role of occlusion in endodontic management: report of two cases. Aust. Endod. J. 30(3):110-115.

INDEX TERMS: Malocclusion, orthodontics, crown amputation, dentistry animal.

012. Freitas E.P., Rahal S.C., Teixeira C.R., Fornazari F., Giordano T. & Gioso M.A. 2007. **Oral cavity evaluation of wildlife *Didelphis albiventris* from Brazil.** *Pesquisa Veterinária Brasileira 27(Supl.).* Departamento de Cirurgia e Anestesiologia Veterinária, FMVZ-Unesp, Botucatu, SP 18618-000, Brazil. E-mail: eliperezfr@yahoo.com.br

Introduction: Didelphimorphs are small to medium size marsupials including three species: *Didelphis virginiana, D. marsupialis,* and *D. albiventris. Didelphis albiventris* are small mammals with black fur covering the greater part of the body and may be divided according to age in juveniles (3.4-8 months), subadults (7.5-9.5 months) and adults (>9.5 months) (Gentile et al. 1995, Cáceres & Monteiro-Filho 1999, Samoto et al. 2006). They are found distributed throughout South America (Muller et al. 2005). Their behavior is nocturnal and during the day they sleep on trees and other shelters (Samoto et al. 2006). Their diet consists mainly of insects, fruits, seeds and vertebrates (Aguiar et al. 2004). The dental formula (one side of one jaw) includes 5 incisors (four on the mandible), 1 canine, 3 premolars and 4 tricuspid molars (Fonseca & Alves 2006). The aim of this study was to evaluate the oral cavity of *Didelphis albiventris* in wildlife.

Materials and Methods: Three juvenile and six adult *Didelphis albiventris* weighing from 200g to 1.6kg were studied. Under general

anesthesia a specific dentistry examination was performed and the findings were registered on the previously prepared dental chart, followed by intra-oral radiographies. The oral cavity was examined by visual inspection of the lips, the soft palate, the hard palate, the tongue, the alveolar mucosa, the buccal mucosa, and the gingiva. Each tooth was evaluated as for abnormal number, malocclusion, stains, presence or absence of plaque and calculus, mobility, attrition or abrasion, crown fracture with or without pulp exposure, evidence of furcation involvement and periodontal pocketing. Negative impression of upper and lower dental arches were obtained using irreversible hydrocolloid (alginate). Immediately after the tray was inserted into the *D. albiventris* mouth, jellification occurred and, upon its completion, the tray was removed and acrylic resin put into the mold. Still under anesthesia action, and a wax registration was taken (by folding the wax lamina under head). The mouth was closed enough to obtain the teeth impression on the wax.

Results: Seven of the nine *Didelphis albiventris* presented dental lesions as follows: dental plaque (14.28%), gingivitis (14.28%), calculus (42.86%), dental stain (42.86%), dental wearing (14.28%), dental fracture (14.28%), pulp exposure (14.28%), avulsed tooth (14.28%), and mandibular alveolar bone fracture (14.28%).

Discussion and Conclusions: The dental formula (one side of one jaw) includes 5 incisors (four on the mandible), 1 canine, 3 premolars and 4 tricuspid molars similar to the dental formula described by other authors (I 5/4, C 1/1, P 3/3, M 4/4 = 50) for *Didelphis albiventris* species (Fonseca & Alves 2006). Dental plaque were observed in 14.28% of the *D. albiventris*. Probably firm-textured natural diet made up of insects, fruits, seeds and vertebrates cause more natural scaling of teeth, and thus, less accumulation of plaque (Amand & Tinkelman 1985, Wiggs & Lobprise 1997, Eisenberg & Redford 1999, Nowak 1999, Aguiar et al. 2004). Dental calculus occurred in 42.86% of the *D. albiventris* and most of them were of grade 1. Dental calculus is a mineralized dental plaque, composed primarily of carbonate calcium and calcium phosphate mineral salts deposited between and within remnants of formerly viable microorganisms (Harvey & Emily 1993, Harvey 1998). It was possible to conclude that juveniles and adult *Didelphis albiventris* in wildlife did not show severe dental lesion probably associated with their diet and absence of stress observed in captivity.

References: Harvey C.E. & Emily P.P. 1993. Small Animal Dentistry. Mosby, St Louis. 413p. - Wiggs R.B. & Lobprise H.B. 1997. Veterinary Dentistry: principles and practice. Lippincott-Raven, Philadelphia, p.748. - Harvey C.E. 1998. Periodontal disease in dogs. Vet. Clin. North Am., Small Anim. Pract. 28:1111-1127. - Aguiar M.S., Ferigolo J., Rossi Jr. J.L. & Gioso M.A. 2004. Atrição dental em *Didelphis albiventris* e *D. marsupialis* (Marsupialia, Didelphimorphia, Didelphidae) do sul do Brasil. Ciência Rural, Santa Maria, 34:1127-1132. - Eisenberg J.F. & Redford K.H. 1999. Order Carnivore. Mammals of the Neotropics. University of Chicago Press, Chicago, p.279-311. - Nowak R.M.. 1999. Order Carnivore. Walker's Mammals of the World. Johns Hopkins University Press, Baltimore, p.632-793. - Amand W.B., Tinkelman C.L. 1985. Oral disease in captive wild animals, p.289-308. In: Harvey C.E. (ed.), Veterinary Dentistry. W.B. Saunders, Philadelphia. - Gentile R., D'Andrea P.S. & Cerqueira R. 1995. Age structure of two Marsupial species in a Brazilian restinga. *J. Tropical Ecol.* 11(4):679-682. - Fonseca C.T. & Alves J.B. 2006. Dental development of *Didelphis albiventris* (Marsupialia). I. Incisors and canines. Braz. J. Biol. 66(1a) 53-60. - Cáceres N.C. & Monteiro-Filho E.L.A. 1999. Tamanho corporal em populações naturais de *Didelphis* (Mammalia: Marsupialia) do Sul do Brasil. Revta Bras. Biol. 59(3):461-469. - Samoto V.Y., Miglino M.A., Ambrósio C.E., Pereira F.T.V., Lima M.C. & Carvalho A.F. 2006. Morfologia da glândula mamária de gambás da espécie *Didelphis* sp. associada ao modelo marsupial. Biota Neotropica 6(2):1-12. - Muller G., Brum J.G.W., Langone P.Q., Michels G.H., Sinkoc A.L., Ruas J.L. & Berne M.E.A. 2005. *Didelphis albiventris* Lund, 1841, parasitado por *Ixodes loricatus* Neumann, 1899, e *Amblyomma aureolatum* (Pallas, 1772) (Acari: Ixodidae) no Rio Grande do Sul. Arq. Inst. Biológico, São Paulo, 72(3):319-324.

INDEX TERMS: *Didelphis albiventris*, wildlife, dental alterations.

013. Freitas E.P., Rahal S.C., Teixeira C.R., Teixeira R., Mendes G.M. & Gioso M.A. 2007. **Coati *(Nasua nasua)* oral cavity evaluation in captivity and its register**. *Pesquisa Veterinária Brasileira 27(Supl.).* Departamento de Cirurgia e Anestesiologia Veterinária, FMVZ-Unesp, Botucatu, SP 18618-000, Brazil. Email: eliperezfr@yahoo.com.br

Introduction: Among wild carnivore mammals, the coatis from the Procyonidae family, Procioninae subfamily, *Nasua* genus, *Nasua nasua* specie, are frequently found in Brazilian zoos (Mehren 1986, Beisiegel 2001, Braddy 2006). Due to the few dental reports of these animals, the aim of this study was to develop a dental chart, to evaluate any oral cavity disease, to develop gypsum models of the dental arcades and to register the occlusion of coatis kept in captivity.

Materials and Methods: Seven coatis of *Nasua nasua* species, five females and two males, having a body weight from 4 to 6 kg, living in the Quinzinho de Barros Municipal Zoo, were used. After fasting of 7 hours, the coatis were tranquilized and 15 minutes later a general anesthesia was induced and maintained with isoflurane. Afterwards, a specific dentistry examination was performed and the findings were registered on the previously prepared dental chart. Negative impression of upper and lower dental arches were obtained using irreversible hydrocolloid (alginate). The endotracheal tube was removed, still under anesthesia action, and a wax registration was taken (by folding the wax lamina under head). The mouth was closed enough to obtain the teeth impression on the wax.

Results: The index of dental plaque was 1 for Coati 7, and 2 for the others. Gingivitis was detected in five animals with degree I (Coati 7), degree II (Coatis 1, 2 e 3) and III (Coati 4). Except Coati 4 that had a calculus degree 3, the others had a degree 2. Bleeding on probing of the gingival sulcus occurred with Coatis 3 and 4 at an intensity of 2 and 4, respectively. Through the registration of the occlusion in wax, the markings of the incisor teeth were of little evidence due to the long canine teeth, which avoided the incisor to carve the wax.

Discussion and Conclusions: The coati dental formula of the present experiment was made up of three incisors, one canine tooth, three or four premolar and two molars, similar to the dental formula described by other authors (I 3/3, C 1/1, P 3-4/3-4, M 2/2 = 36-40) for *Nasua nasua* species (Mehren 1986, Kertesz 1993). Dental plaque and gingivitis were observed in 71.43% of the coatis. These findings suggest that coatis kept in

captivity are predisposed to periodontal disease caused by the accumulation of bacterial plaque (Emily & Penman 1994, Harvey 1998, Brown & Mcgenity 2005, Gengler et al. 2005). Probably firm-textured natural diet made up of fruits, nuts, figs, small birds, rodents, lizards, snails, insects, among others, cause more natural scaling of teeth, and thus, less accumulation of plaque (Amand & Tinkelman 1985, Wiggs & Lobprise 1997, Eisenberg & Redford 1999, Nowak 1999). From this study it was possible to conclude that coatis in captivity may develop oral diseases which, in many cases, may be associated with the administered diet type and environmental stress.

References: Kertesz P. 1993. A Colour Atlas of Veterinary Dentistry e Oral Surgery. Wolfe Publ., Aylesbury. 312p. - Mehren K.G. 1986. Procyonidae, p.816-820. In: Fowler M.E. (ed.), Zoo and Wild Animal Medicine. Saunders, Philadelphia. - Beisiegel B.M. 2001. Notes on the coati, *Nasua nasua* (Carnivora: Procyonidae) in an Atlantic forest area. Braz. J. Biol. 61:689-692. - Braddy S. *Nasua nasua*, Animal Diversity Web. Disponível em: <http:/animaldiversity.ummz.umich.edu/site/accounts/information/Nasua_nasua.html>. Acesso em: 22 jan. 2006. - Wiggs R.B, Lobprise H.B. 1997. Veterinary Dentistry: principles and practice. Lippincott-Raven, Philadelphia, p.748. - Emily P. & Penman S. 1994. Small Animal Dentistry. 2nd ed. Pergamon Press, Oxford, p.7-53. - Harvey C.E. 1998. Periodontal disease in dogs. Vet. Clin. North Am. Small. Anim. Pract. 28:1111-1127. - Brown W.Y. & Mcgenity P. 2005. Effective periodontal disease control using dental hygiene chews. J. Vet. Dent. 22:16-19. - Gengler W.R., Kunkle B.N., Romano D. & Larsen D. 2005. Evaluation of a barrier dental sealant in dogs. J. Vet. Dent. 22:157-159. - Eisenberg J.F. & Redford K.H. 1999. Order Carnivore. Mammals of the Neotropics. University of Chicago Press, Chicago, p.279-311. - Nowak R.M. 1999. Order Carnivore. Walker´s Mammals of the World. Johns Hopkins University Press, Baltimore, p.632-793. - Amand W.B. & Tinkelman C.L. 1985. Oral disease in captive wild animals, p.289-308. In: Harvey C.E. (ed.), Veterinary Dentistry. W.B. Saunders, Philadelphia.

INDEX TERMS: *Nasua nasua,* oral cavity, dental chart.

014. Gawor J.P.[1,2], Jodkowska K.[1,3], Kurski G.[1,4], Korczyñski W.[6], Ceregrzyn M.[5,6]. 2007. **Oral health in pedigree dogs in association with their bodyweight and type of skull**.. *Pesquisa Veterinária Brasileira 27(Supl.).* [1]Dental Working Group in Polish Small Animal Veterinary Association; [2]Veterinary Clinic Arka, Kraków.; [3]Warsaw Agricultural University; [4]ELWET Veterinary Hospital, Warszawa; [5]Masterfoods Polska, Koćuszki Parcel; [6]Department of Gastrointestinal Physiology, Institute of Animal Physiology and Nutrition, Polish Academy of Sciences, Jab³onna. E-mail: jgawor@pp.com.pl

Introduction: Numerous factors influence oral health in dogs. Age, diet, and preventive measures taken by owners are the most important ones.(Harvey & Emily 1993, Lyon 1993, Gawor 1997, Lund et al. 1999) It has been observed that older dogs have more serious oral problems. (DuPont 1998, Lund et al. 1999), On the other hand, proper diet, and appropriate homecare can significantly improve oral health status. Anatomical aspects as bodyweight, size, and type of scull may also play a role in oral health. There is very little known about genetic background of oral diseases occurrence. Particularly periodontal disease incidence is very likely linked with the genome. It is possible that anatomy of an individual dog, as a part of genetic expression, is a good example of the influence of genetics on the oral health status. Therefore, the aim of the present study was to investigate anatomical factors that may influence oral health in dogs.

Materials and Methods: In 2005, members of the Dental Working Group of the Polish Small Animal Veterinary Association (PSAVA) and representatives of Masterfoods Poland recruited veterinary practices to provide free oral examinations in cats and dogs. The examination procedure consisted of three parts: 1) clinical dental/periodontal examination; 2) history taking and filling in a questionnaire; 3) presentation of diagnosis and management plan to the owner. Parameters such as age of the patients, size of mandibular lymph nodes, presence of dental deposits, and presence of periodontal disease were recorded and scored, utilizing standardized charts. (Gawor et al 2003) Presented studies shows results obtained from pedigree dogs distinguished from the total population of examined animals. The oral health index (Hennet et al. 2002, Schumacher 1993) was defined as the summation of scores obtained for the three parameters: lymphadenopathy, dental deposits, and periodontal disease (Table 1). The best score was 0 that mean optimal oral health while the worst possible score was 7. The oral health score was related to two parameters dogs' weight and type of skull. Based on the proportion of muzzle to the skull dogs were grouped into brachycephalic, mesocephalic, or dolichocephalic type. Complete data were obtained from 5462 pedigree dogs in 730 Polish veterinary practices. The oral health was expressed as oral health index (OHI) that was a sum of single parameters score.(Gawor et al. 2006) Statistical analysis was performed using Chi square test (Statistica 6.0, USA). $P<0.05$ was considered significant.

Results: In the present confirmed that age is one of the most important factors influencing oral health (Fig.1). Therefore, dogs over 3 years were taken for the further analysis. Adult dogs weighting less that 5 kg showed more frequent OHI 5 while in heavier dogs OHI 1 and 2 were the most frequently scored (Fig.2). Statistical significance in occurrence of OHI equal 0 was observed in dogs weighting more that 25 kg in comparison to dogs weighting less than 5 kg ($P<0.001$). On the other hand, in dogs lighter than 5 kg occurrences of OHI equal 7 was significantly higher that in dogs weighting more that 5 kg ($P<0.01$). Moreover, dogs weighting more than 25 kg showed less frequent occurrence of OHI equal 7 than lighter dogs. There was a large disproportion of number of representative dolichocephalic dogs ($n=40$) in comparison to mesocephalic and brachycephalic dogs $n=4791$ and 648, respectively. Therefore, the interpretation of the data concerning dogs with long muzzle is questionable. Mesocephalic dogs showed equally frequent incidence of OHI score 0 in comparison to brachycephalic dogs ($P=0.48$). Similarly, OHI equal 7 had the same incidence in both groups ($P=0.23$). However, OHI equal 1 was more frequently observed in mesocephalic dogs ($P<0.01$). On the other hand OHI equal 6 was more frequent in brachycephalic dogs ($P<0.01$). (Fig.3)

Discussion and Conclusions: Obtained results show that smaller dogs are more prone to the occurrence of oral health problems regardless the age that is very important factor influencing oral health. Moreover, proportions of the skull influence the oral health. Brachycephalic dogs are more often affected than the rest of the population studied. Due to low number of

Table 1. Oral health parameters assessed during patient examination

Parameter	Score[a]			
	0	1	2	3
Size of mandibular lymph nodes on palpation	Normal	Slightly enlarged	Moderately to severely enlarged	-
Presence of dental deposits (plaque, calculus and stain)	Absent	Up to 50% of the dental crown affected	More than 50% of the dental crown affected	Abundant amount of calculs and plaque
Presence of periodontal disease	Absent	Gingivitis	Periodontitis	-

[a] The summation of scores obtained for the three parameters provide the oral health index; 0 points indicate optimal oral health, 6 points indicate the worst oral health.

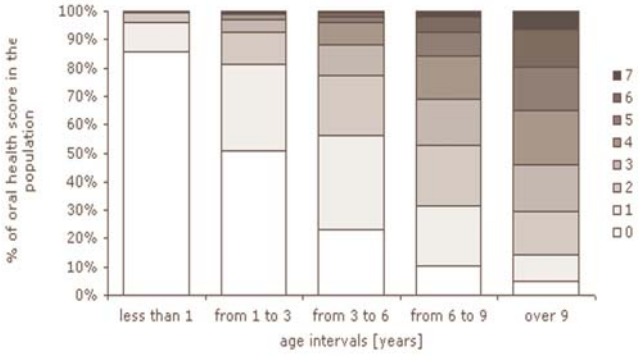

Fig.1. The influence of age of pedigree dogs on oral health index. Data expresses as a percentage of OHI incidence in 5 age intervals.

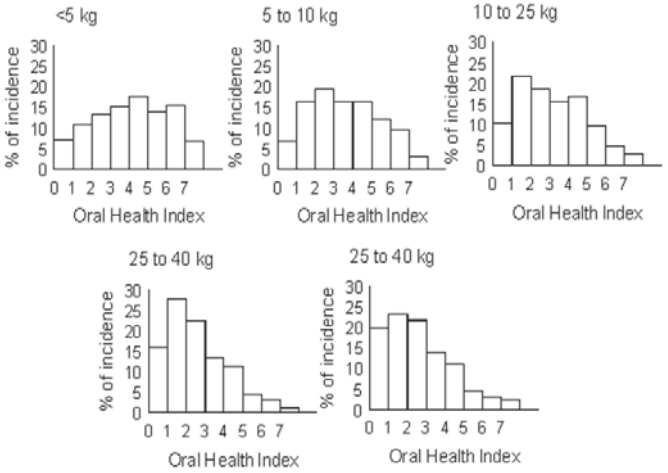

Fig.2. The distribution of OHI in five weight categories.

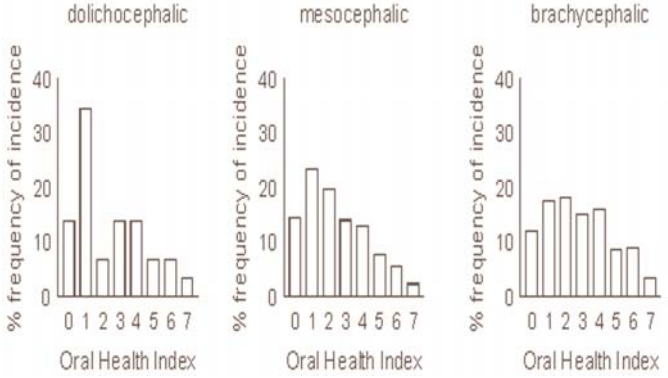

Fig.3. The influence of scull type on incidence of OHI score in dogs over 3 years.

dolichcephalic dogs' population it is very difficult to conclude whether these dogs are more or less affected than other dogs.

The study was performed in normal environment of dogs; therefore the diet was not standardized for the study. Therefore the data was analyzed regardless the type of the diet. In the population studied 22% dogs ate dry commercial food, 18% mixture of dry and wet commercial diets, 5% only wet diets, 41% mixture of commercial diets and home made food, 15% only home made food. In conclusion, presented data shows that size and skull type are factors influencing oral health. However, within the analyzed groups there are certain variations suggesting that more particular genetic features influence oral problem incidence in a single individual.

References: Harvey C. & Emily P.P. 1993. Periodontal Disease: small animal dentistry. Mosby-Year Book, St Louis, p.89-144. - Lyon K.F. 1993. Advances in periodontal therapy. What about the basics? J. Vet. Dent. 10(1):5. (Editorial). - Gawor J. 1997. Osady nazêbne u psów i kotów. Patogeneza, postêpowanie, profilaktyka [Dental deposits in dogs and cats. Pathogenesis, management and prophylaxis]. Mag. Wet. 29:171-174. - DuPont G.A. 1998. Prevention of periodontal disease. Vet. Clin. North Am. Small Anim. Pract. 28:1129-1145. - Lund E.M., Armstrong P.J., Kirk C.A., Kolar L.M., Klausner J.S. 1999. Health status and population characteristics of dogs and cats examined at private veterinary practices in the United States. J. Am. Vet. Med. Assoc. 214:1336-1341. - Gawor J., Jodkowska K., Kurski G. 2003. Postêpowanie z pacjentem stomatologicznym [Dental patient management. Instructions for veterinarians participating in the Pet Smile Campaign 2003-2004.] PSAVA and FH STOPA, Gdynia, Polandm, - Hennet P., Soulard Y., Salesse H. 2002. Evaluation of the Boyce & Logan plaque scoring method for the study of plaque accumulation in dogs. Proc. 11th Europ. Congr. Vet. Dentistry, Granada, Spain, p.56-58. - Schumacher C.B. 1993. Charting and the oral examination. J. Vet. Dent. 10(3):9-13. - Gawor J., Reiter A.M., Jodkowska K., Kurski G., Wojtacki M.P. & Kurek A. 2006. Influence of diet on oral health in cats and dogs. J. Nutr. 136:2021-2023.

INDFEX TERMS: Dog, oral health, brachycephalic, bodyweight, size, diet, pet smile campaign.

015. Gioso M.A., Fecchio R.S. & Ferreira J. 2007. **Iatrogenic dental lesion caused by "dental disarming" in chimpanzee (*Pan troglodytes*).** *Pesquisa Veterinária Brasileira 27(Supl.).* Laboratory of Comparative Dentistry, Surgery Department, FMVZ-USP, São Paulo, Brazil. E-mail: maggioso@usp.br

Introduction: The "dental disarming" (crown amputation) in wild animals consists in cutting the canine teeth in close to the cervical line of the tooth so that they have the incisive teeth crown height. The purpose of this technique is to eliminate the dangerous potential represented by the canine teeth, which can lead the animal to lethal accidents, serious injuries caused

by the animal bite, or self trauma. This procedure is conducted to decrease the risk and severity of bite wound trauma to personnel, other nonhuman primates, and to the primates themselves (Kertsz 2003). Several techniques are used to disarm the canine teeth of nonhuman primates. Disarming nonhuman primate teeth is presently the subject of debate due to the high incidence of abscessation of the affected tooth (Lyon 2001, Pachaly & Gioso 2001). The most common techniques used to disarm teeth include complete extraction of canines, crown reduction followed by a mucoperiosteal flap, crown reduction followed by a root canal, or crown reduction followed by a pulpal capping procedure (Lyon 2001). A pulpotomy is also an acceptable procedure in these cases. To leave an open and exposed pulp canal after disarming is an invitation to infection and litigation (Amand & Tinkelman).

This surgical procedure requires sterile technique. Surgical preparation with rubber dam technique, surgical drapes, caps, masks, gloves, and sterile instruments is indicated (Forrest 1986). After evaluation of dental radiographs, the pulp chamber is entered and the pulp is removed down to about the cervical level of the tooth. It is advisable to avoid the cervical level of the pulp, which is important in dentin production and contributes to the strength of the tooth. Approximately 5 to 10 millimeters of pulp are removed using a water-cooled round diamond bur in a high-speed handpiece. Gently wash the pulp with saline and place a moist cotton pellet on the pulp until the bleeding stops, in general not more than 15 minutes. Then wash the pulp again before placing a pulp dressing. Calcium hydroxide is introduced over the pulp tissue as a powder. Exposed dentin should be coated also. A glass ionomer is over the calcium hydroxide pulp dressing. A crown restoration is completed using a direct bonded composite restorative. Placement of a light cured unfilled resin placed over the pulp tissue without placement of calcium hydroxide has also been described, as well as CO_2 laser vital pulpectomy techniques (LYON, 2001). If the pulp bleeding does not stop after five minutes, remove 2 to 3 millimeters of pulp. If hemorrhage continues, proceed with conventional endodontic pulpectomy and obturation techniques. Assessment of successful vital pulp is made with dental radiographs at six weeks, six months and then yearly. A dentinal bridge may be evident indicating a successful procedure. However, success may be seen without an obvious dentinal bridge. Periodic reassessment with radiographs is the only method of determining a successful procedure.

Case Report: A female chimpanzee, belonging to a circus, was referred to the Laboratory of Comparative Dentistry of FMVZ-USP, where its oral cavity was examined and the animal was maintained in an anesthetic plan by Sevoflurane. During the oral evaluation, it was seen that three canine teeth had passed through crown reductions without specific endodontic procedure. However, these teeth were apparently healthy because of the tertiary dentine (reactional) produced by the dental pulp, which occluded the root canal and minimized the traumatic pulp exposure effects. Nevertheless, the upper canine tooth was not with the same reactional pattern and, probably, presented an infectious and inflammatory endodontic lesion that leaded to a pulp necrosis, root resorption and gingival hyperplasia. These last signs were observed during the oral cavity clinical exam. As treatment, the roots of the teeth were extracted, after intra-oral radiography, because the direct inspection of this dental element was not possible due to gingival hyperplasic reaction which was covering the teeth.

Discussion and Conclusion: There are ethical elements involved in these "dental disarming" procedures, once they are mutilating to the animal and this procedure has to be accomplished exclusively by veterinarians. The extent of the dental procedure may vary in individual cases from crown amputation of canine teeth to extraction of all teeth. All dental treatments must be performed appropriately, under general anesthesia, understanding the disadvantages and risks. Crown amputations must reduce crown height appropriately, and remaining tooth structure requires endodontic therapy, including periodic long-term radiographic evaluation. Crown amputation with endodontic therapy or extraction of multiple teeth rarely causes long-term complications. Appropriate pain management measures are essential. Even after this procedure is performed, aggressive individuals are still capable of inflicting serious damage, including mortal injury. "Dental disarming" should be reserved as a procedure of last resort.

References: Amand W.B. & Tinkelman C.L. 1985. Oral disease in captive wild animals, p.289-308. In: Harvey C.E. (ed.), Veterinary Dentistry. - Forrest A.W.V. 1986. Veterinary dentistry in zoo and wild animals. In: Fowler E.M. (ed.), Zoo and Wild Animals Medicine. W.B. Saunders Company, Philadelphia. - Pachaly J.R. & Gioso M.A. Oral cavity, p.457-463. In: Fowler M.E. & Cubas Z.S. (ed.), Biology, Medicine and Surgery of South American Wild Animals. Iowa State University Press, Ames. - Kertesz P.A. 1993. Colour Atlas of Veterinary Dentistry and Oral Surgery. Wolfe Publishing, Aylesbury. - Lyon K. 2001. Emergency Endodontics and Pulpotomy. Proc. Small Anim. Vet. Assoc. World Congr., Vancouver, Canada

INDEX TERMS: Dental disarming, crown reduction, Chimpanzee, *Pan troglodytes*, primates, pulpotomy.

016. Gonzáles R.R., Maia J.Z. & Witz M.I. 2007. **Oclusal adjustment on mare with upper fourth premolars missing.** *Pesquisa Veterinária Brasileira 27(Supl.).* Dentist and Veterinarian in Private Practice in Brazil. C-D, M-V, MSD. E-mail: rosalina@cpovo.net

Introduction: Although horses can have up to forty four teeth, canines are usually present on male horses. Lower woolf teeth are not as common as upper ones but these kind of absences are considered normal (Baker 1999). Missing teeth can occur due to periodontal disease, caries, trauma and also be congenitally missing. Malocclusion will develop when congenitally missing teeth are present because adjacent teeth migrate to the remaining space and diastemas will appear on other areas (Pence & Wilewski 2002). Food impaction will occur between diastemas (Pence 2002) and teeth of the opposing arcade will extrude causing some times gingival and osseous trauma. The antagonist tooth in certain cases should be extracted (Baker 1999).When there is an incisor missing the extruded tooth should be filled (Mitz 2003). Motorized equipment allows a faster and more precise work and also a less stressful job for the veterinarian (Dacre & Dixon 2002).

But it is important to know the technics and risks to use this kind of equipment (Scrutchfield 1999).

Materials and Methods: A 15-year-old thoroughbred mare arrived at the hospital with a history of weigth loss. An oral exam was done and it was observed that both upper fourth pre molars were missing. Steps were found on the opposing arcade which were causing gingival trauma. Sedation was done with xylazine (0,5mg/Kg) and radiographs were taken before and after the procedures. Mouth was rinsed with water and the oral speculum and dental halter were placed after. Oclusal adjustment was done with motorized equipments and refrigeration was done simultaneously. The oral speculum and dental halter were removed at the end of procedure. Since the steps were so pronounced oclusal adjustments were done three times with intervals of six months in between. The oclusal adjustment was not done all at once to avoid pulp damage.

Results: As a result of the oclusal adjustment there was improvement on the score condition. Also the radiographs show reduction of both steps.

Discussion and Conclusions: There is no doubt that the motorized dental equipments changed the way equine dentistry is done and allows a better and faster job with less force by the professional. But it is important to keep in mind that this kind of equipment should be used by experienced professional because on the contrary there is a risk to remove excess tooth structure and as a consequence reduce its functional life. Besides there is a risk to cause irreversible pulp damage due to the heat produced by the equipment and also pulp exposure on the oclusal surface caused by excess tooth removal.

References: Baker G.J. 1999. Abnormalities of development and eruption, p.49-59. In: Baker G.J. & Easley J.J. (ed.), Equine Dentistry. W.B.Saunders Company Ltd, London- Dacre K.J.P., Dacre I.T. & Dixon P.M. 2002. Motorised equine dental equipment. Equine Vet. Educ. 4:337-340. - Mitz C. & Allen T. 2003. Dentistry in miniature horses, p.175-192. In: Allen T. (ed.), Manual of Equine Dentistry. Mosby, St. Louis, Missouri. - Pence P. 2002. Dental equipment, p.25-52. In: Pence P. (ed.), Equine Dentistry: a practical guide. Lippincott Williams & Wilkins, Philadelphia - Pence P. & Wilewski K. 2002. Newborn, wealing , and adolescent horse dentistry, p115-140. In: Pence P. (ed.), Equine Dentistry: a practical guide. Lippincott Williams & Wilkins, Philadelphia. - Scrutchfield D.L. 1999. Equine dental instrumentation, p.173-184. In: Baker G.J. & Easley J.J. (ed.), Equine Dentistry. W.B. Saunders Company Ltd, London.

INDEX TERMS: Equine dentistry, oclusal adjustment, missing premolars.

017. Holms C.A.T.A. & Gioso M.A. 2007. **Regional analgesia for equine dentistry procedures.** *Pesquisa Veterinária Brasileira 27(Supl.).* Laboratório de Odontologia Comparada, Faculdade de Medicina Veterinária e Zootecnia, Universidade de São Paulo (FMVZ-USP), São Paulo, SP 055900-000, Brazil. E-mail: carlaholms@hotmail.com

Introduction: Several dentistry procedures, including examination, radiograph and endoscope diagnostic and surgery itself can be successfully performed in the appropriately restrained and sedated standing horse. However, for dental surgical procedures, additional analgesia can be provided with appropriate local anesthetic blocks, eliminating general anesthesia associated risks, like prolonged recumbence and recovering (Schumacher et al. 2000; Dixon et al. 2005). However, some difficult animals cannot permit head manipulation, and the use of loud instruments and excessively prolonged procedures are not recommended (Ford 1991).

Literature Review: The regional anesthesia is obtained through the sensitivity regional nerve block (Schumacher et al. 2000). Basically, the local anesthetic agents inhibit the influx of sodium ions across the axonal membrane. The physico-chemical properties of each local anesthetic drug determine the onset of action, potency and duration of action (Dav & Skarda 1991). In the horse dentistry, lidocaine is still the local anesthetic drug most widely used (Ford 1991). Regional anesthesia is produced through the perineural injection of a local anesthetic drug in the main surgical site nerves (Ford 1991). There are basically three principal nerves in dentistry surgery, the infraorbitary, mandibular and the mental ones, all of them derive from the trigeminal nerve. The regional anesthesia purpose in oral procedures is to permit a great numbers of surgical interventions in the standing horse, without general anesthesia and their associated costs and risks (Dixon et al. 2005). The infraorbitary nerve is a maxillary branch of a trigeminal nerve, and is responsible for the maxillary teeth innervations, upper lips, cheek and nose sensitization. The infraorbitary nerve begins in the pterigopalatine fossae, and runs cranially inside the infraorbitary channel, emerging from the infraorbitary foramen, localized next to the facial crest (Ford 1991). Once blocked about 2 centimeters inside the infraorbitary foramen, this nerve will desensitize the rostral portion of the maxilla, including lips and nose and the ipsilateral incisors, canine, premolar teeth, their alveolus and associated gingival tissue (Scrutchfield et al. 1996; Hague & Honnas 1998). So, this nerve block could be used for dentistry procedures like tooth extraction, rostral maxillary fractures stabilization and soft tissues suture (Ford 1991). The mandibular branch of the trigeminal nerve receives three different denominations along its course. When this nerve penetrates the mandibular foramen, localized on the medial face of the mandibular vertical ramous, it is named mandibular nerve (Ford 1991). This nerve runs rostrally inside the mandibular channel, receiving the name inferior alveolar nerve (*N. alveolaris inferior*). When finally emerges in the mental foramen, it is named as mental nerve. Once an anesthetic block is done in the mandibular foramem site, all ipsilateral mandibular teeth, alveoli, gingiva and the lower lips are desensitized (Hague & Honnas 1998). This is accomplished with a very long needle or catheter (around 25mm for large horses) However, some areas of the mandibular cutaneous tissues are still innervated by the superficial temporal nerve (Ford 1991). With an anesthetic block close to the mental foramen, next to the labial comissure, only incisors and canine teeth, their alveoli and gingiva together with the lower lips are desensitized (Scrutchfield et al. 1996). If the local anesthetic can be deeply inserted in the

mental foramen, the premolars teeth can also be desensitized (Hague & Honnas 1998). Complications associated with local anesthetics are rare in the horse, making this agent an attractive option in the high-risk patient. The main complication associated with local anesthetic is over dosage, causing changes in the central nervous system activity (excitement or depression), muscle tremors and hypotension. However, the dose required to produce these effects in the horse is very high (12mg/kg), justifying the uncommon complications (LeBlanc 1990). Short-term or long-term analgesia is most commonly provided with non steroidal anti-inflammatory drugs.

Discussion and Conclusion: Although many dental procedures can be performed on the sedating standing horse, by the use of local anesthetic agents, the decision to perform this procedure must be made on the basis of the temperament of the horse, severity of the injury and skill of the surgeon. The knowledge of the nerves anatomical sites and the correct use of nerve blocks will greatly facilitate the correct diagnosis and permits a surgical treatment of a great numbers of dental affections avoiding the general anesthesia associated risks and costs.

References: Dav T.K. & Skarda R.T. 1991. The pharmacology of local anesthetics. Vet. Clin. North Am., Equine Pract. 7(3):489-500. - Dixon P.M., Dacre I., Dacre K., Tremaine W.H., McCann J. & Barakzai S. 2005. Standing oral extraction of cheek teeth in 100 horses (1998-2003). Equine Vet. J. 37(2):105-112. - Ford T.S. 1991. Standing surgery and procedures of the head. Vet. Clin.North Am., Equine Pract. 7(3):583-600. – Hague B.A., Honnas C.M. 1998. Traumatic dental disease and soft tissue injuries of the oral cavity. Vet. Clin. North Am., Equine Pract. 14(2):333-348. - LeBlanc, P. H. 1990. Regional anesthesia. Vet. Clin. North Am., Equine Pract. 6(3):693-704. - Scrutchfield W.L., Schumacher J. & Martim M.T. 1996. Correction of abnormalities of the cheek teeth. Proc. 42th Annu. Conv. Am. Assoc. Equine Pract., p.11-21. - Schumacher J., Dutton D.M., Murphy D.J., Hague B.A. & Taylor T.S. 2000. Paranasal sinus surgery through a frontonasal flap in sedated, standing horses. Vet. Surgery 29(2):173-177.

INDEX TERMS: Horses, regional anesthesia, nerves, mandibular, maxilla.

018. Holms C.A.T.A. & Gioso M.A. 2007. **Tooth extraction in horses**. *Pesquisa Veterinária Brasileira 27(Supl.):00-00.* Laboratório de Odontologia Comparada, Faculdade de Medicina Veterinária e Zootecnia, Universidade de São Paulo, FMVZ-USP, São Paulo, SP 055900-000, Brazil. E-mail: carlaholms@hotmail.com

Introduction: Tooth removal is the most frequently performed oral surgery in the horse. Usually, the exodontia should be considerate when other more conservative treatments do not respond well or have failed (Dixon et al. 2000).The most common indications for dental extraction include retained deciduous teeth, advanced periodontal disease, dental fractures, supernumerary tooth, displaced or misaligned teeth, dental impaction and periapical abscesses (Tremaine & Lane 2005).There are many extraction techniques, and the selected one will depend on the tooth to be removed, the kind of tooth disease and the preference of the surgeon performing the procedure (Tremaine & Lane 2005).While many dental extractions can be performed in the sedating standing horse, the necessity for general anesthesia in difficult patients or for complicated procedures must always be considered (Orsini 1992).

Literature Review: Dental extraction is a technically challenging procedure, demanding careful preparation, specialized equipment and a surgeon that has a meticulous technique, avoiding intra and post-operative complications (Tremaine & Lane 2005). The purpose of all extraction procedures is to separate the tooth from the jaw, breaking down the periodontal ligament, structure that attaches each tooth to its respective alveolus. This procedure is easily performed in aged horses, which have shorter reserve crowns, and in severe periodontal disease cases, which present a weak periodontal attachment (Dixon 1997b). A great number of radiographs should be made before the exodontia procedure. Dental removal should never be undertaken when doubts remain as to diseased tooth (Mueller 1991; Lane 1994). Clinic and radiographic detailed exams are very helpful to choosing the best extraction technique (Mueller 1991). The oral extraction is the less traumatic technique, and has been associated with a reduced incidence of complications (Dixon et al. 2000). It is the current technique of choice for the majority of horses (Lowder 2000). The oral extraction can be performed with standing chemical restraint and local anesthesia. Extraction of the caudal molars teeth using this technique is more difficult because the limited mouth wide opening of the equine temporomandibular joint. Also, oral extraction could not be applied in dental impaction cases and should not be applied in fractured and severe carious teeth (Dixon 1997b, Tremaine & Lane 2005). The oral extraction technique begins with preoperatively antibiotic and anti-inflammatory drugs administration (Easley 1991). A speculum is inserted and opened to provide access and visual identification of the tooth to be removed (Orsini 1992). After that, the gingival tissue on both sides, buccal and palatal or lingual is elevated from the tooth using a periodontal elevator (Dorn 1989). Molar separators can be used to loosen the rostral and caudal periodontal attachments, except between the first and second and between the fifth and sixth cheek teeth, because the risk of iatrogenical loosening of the first or a last healthy cheek teeth (Tremaine & Lane 2005). Once the loosening of the periodontal attachments, the molar extractors should be firmly placed on the tooth. Low amplitude rotary movements should be done in the horizontal plane. This amplitude should be increased slightly as the tooth becomes loose, but excessive forces need to be avoided, because they can result in fracture or shearing of the clinical crown (Baker 1991, Dixon 1997b, Lowder & Mueller 1998, Tremaine & Lane 2005). Once extracted, the tooth should be inspected for integrity, exceptionally in the apical area. The alveolus should be curetted to avoid the presence of remaining dental or alveolar bone fragments (Easley 1991, Orsini 1992). In this technique, as well as the surgical ones, the dental alveolus may be temporarily protected with dental wax, impression compound or gauze

soaked in an antibacterial solution, to avoid food and saliva impaction. The packing will be gradually extruded as the alveolus heals (Tremaine & Lane 2005). Radiographic exams should be done again, looking for dental remaining fragments, one of the main post-operative complications (Easley 1991). The surgical extraction of equine teeth is performed under general anesthesia through the utilization of an endotraqueal tube, protecting the horse airways (Mueller 1991). It is a procedure that may have many potential complications in the intra and post-operative periods. The skin over the surgical site must be cleansed, and prepared for an aseptically procedure. Preoperatively antibiotics and anti-inflammatory drugs are recommended too. There are basically three techniques that have been used nowadays (Tremaine & Lane 2005). Dental repulsion is the most traditional method for the surgical extraction of cheek teeth in horses (Easley 1991, Lane 1991, Mueller 1991, Orsini 1992, Dixon 1997), where an osteotomy access over the apex of the diseased tooth is made in order to drive it into the mouth with a punch (Turner & McIllwraith 1989, Dixon 1997, Tremaine & Lane 2005). This technique can be used in both, maxillary and mandibular teeth, but the repulsion of the last mandibular teeth frequently requires an incision of the masseter muscle (Gaughan 1998). However, this repulsion technique is suggested as the surgical option to remove all the maxillary molars teeth and the last mandibular teeth (Triadam 109, 110, 111, 209, 210, 211, 311, 411) (Tremaine & Lane 2005). As in the oral extraction technique, the repelled tooth should be inspected for any missing pieces and the alveolus should be curetted. Radiographic evaluation should be done as well (Gaughan 1998). This technique requires careful aftercare because of the long healing time and a secondary sinus empyema development in some cases (Easley 1991; Pascoe 1992; Orsini 1992). The buccotomy technique purpose is to make a horizontal skin incision through the cheek, centered over the diseased tooth, followed by a gingival flap and a removal of the buccal crest of the alveolar bone and a dental longitudinally sectioning, splitting the tooth, which is withdraw laterally (Evans et al. 1981). The alveolus should be curetted and radiographic evaluation should be performed after the procedure. The oral defect should be protected, and the incision is closed in three layers starting with the gingival mucosa. This technique could be used to remove the premolars in all arcades (Tremaine & Lane 2005). The vertical alveolar osteotomy, a modification of the buccotomy technique is an option to remove the 309, 310, 409 e 410 teeth, taking account the position of the linguofacial artery and vein as well as the parotid salivary duct. A vertical skin incision is made, and the vertical osteotomy incisions are made in the dental interproximal spaces, removing at least two-thirds of the lateral alveolar wall before attempting to remove the tooth. Residual root tissues should be removed and the oral defect protected. Radiographic evaluation needs to be performed also. The mucosal and skin defects should be closed (Tremaine & Lane 2005). There are a great number of post-operative complications involving equine tooth removal, frequently caused by incomplete removal of the diseased tooth, causing or maintaining infections and persistent drainage (Pascoe 1992). Also, after the removal of an equine tooth, the opposite one will not be worn down, because there is no more wearing by the antagonists (Orsini 1992).

Conclusions: The exodontia remains the most common oral surgery in the horse (Dixon et al. 2000). The surgical extraction techniques should be done with a careful preparation and an appropriate knowledge of the anatomy of the surgical site (Tremaine & Lane 2005). A precise diagnostic is very helpful, and a great numbers of radiographs should be taken before choosing the correct surgical procedure. After all dental removal, radiographs always need to be done, looking for a presence of any dental or alveolar bone fragments. The post-operative care should not be neglected and the healing alveolus should be monitoring until it becomes filled by granulation tissue, avoiding post-operative complications. The opposite teeth need periodic wearing, avoiding overgrowth.

References: Dixon P.M.1997. Dental Disease. Current Therapy in Equine Medicine. 4th ed. W.B. Saunders, Philadelphia, p.149-153. - Dixon P.M. 1997a. Dental extraction in horses: indications and preoperative evaluation. Comp. Cont. Educ. Pract. Vet. 19(3):366-375. - Dixon P.M. 1997b. Dental extraction and endodontic techniques in horses. Comp. Cont. Educ. Pract. Vet. 19(5):628-638. - Dixon P.M., Tremaine W.H., Pickles K., Kuhns L., Hawe C., McCann J., McGorum B.C., Railton D.I. & Brammer S. 2000. Equine dental disease. Part 3. A long-term study of 400 cases: disorders of wear, traumatic damage and idiopatic fractures, tumours and miscellaneous disorders of the cheek teeth. Equine Vet. J. 32(1):09-18. - Dorn A.S. 1989. Basic Oral Surgery. Veterinary Dentistry'89, Sponsored by the American Veterinary Dental College and the Academy of Veterinary Dentistry, San Anto-nio, TX. p.120-122. - Easley K.J. 1991. Recognition and management of the diseased equine tooth. Proc. 37th Annu. Conv. Am. Assoc. Equine Pract., San Francisco, CA, p.129-139. - Evans L.H., Tate L.P. & LaDow C.S. 1981. Extraction of the equine 4th upper premolar and 1st and 2nd upper molars through a lateral buccotomy. Proc. 27th Annu. Conv. Am. Assoc. Equine Pract., San Diego, CA, p.249-252. - Gaughan E.M. 1998. Dental surgery in horses. Vet. Clinics North Am., Equine Pract., 14(2):381-397. - Lowder M.Q. & Mueller P.O.E. 1998. Dental disease in geriatric horses. Vet. Clinics North Am., Equine Pract., 14(2):365-380. - Mueller P.O.E. 1991. Equine dental disorders: cause, diagnosis, and treatment. Comp. Cont. Educ. Pract. Vet. 13(9):1451-1461. - Orsini P.G. 1992. Oral cavity, p.301-305. In: Auer J.A. (ed.), Equine Surgery. W.B. Saunders, Philadelphia. - Pascoe J.R. 1992. Complications of dental surgery. Proc. Annu. Meet. Am. Assoc. Equine Pract., Orlando, FL, p.141-146. - Turner A.S. & McIllwraith C.W. 1989. Equine Dental and Gastrointestinal Surgery: techniques in large animal surgery. Lea and Febiger, Philadelphia, p.235-239.

INDEX TERMS: Horse, teeth, exodontia, extraction, buccotomy, repulsion.

019. Jamshidi Sh[1] & Bokaie S[2] 2007. **Epidemiologic study of periodontal disease in dogs referred to the small animal hospital, faculty of veterinary medicine, University of Tehran.**
Pesquisa Veterinária Brasileira 27(Supl.). [1]Department of Clinical Sciences, Faculty of Veterinary Medicine, University of Tehran, Tehran-Iran; [2]Department of Food Hygine, Faculty of Veterinary Medicine, University of Tehran, Tehran-Iran. E-mail: shjamshidi@vetmed.ut.ac.ir

Abstract: This study as the first time in Iran performed to determine the prevalence of periodontal disease and gingivitis. 300 dogs with 6 months of age and older that was referred to small animal hospital, faculty of veterinary medicine, University of Tehran included in this study. In all cases factors like as age, diet and content of bone in it (hardness of diet) and occlusion

conformation were recorded. Based on oral examination and content of dental calculus, depths of gingival sulcus, dental mobility or their lost, the gingival status were graded as: 1) healthy, 2) gingivitis (primary and reversible lesions), and periodontitis (advanced and irreversible cases). The frequency rate of gingivitis and periodontitis were 24% and 12% respectively. Small breeds had a higher tendency for gingival problems (gingivitis = 32.8% and periodontitis = 24.8%) in comparison with larger breeds (gingivitis = 19.2% and periodontitis = 0.9%). Periodontal disease was more common in older animals and all of the dogs more than 5 years old showed some degrees of gingival disease. Furthermore gingival diseases were more common in the dogs with soft diets (75.5%). Dental calculus were deposited mainly on maxillary forth premolars and first molars, but dental mobility was more prevalent in incisors. Based on results of the study, gingival problems should be considered as one of the most common disorders in small breeds of dogs and such animals' especially older ones need more attention to oral hygienic procedures.

INDEX TERMS: Periodontal disease, epidemiology, dog.

020. Kowalesky J. & Gioso M.A. 2007. **Dental anatomy of the dog and the cat.** *Pesquisa Veterinária Brasileira 27(Supl.).* Departamento de Cirurgia, FMVZ-USP, São Paulo, SP CEP 05508-000, Brazil. E-mail: jukowalesky@hotmail.com

Introduction: The knowledge of the anatomy of the stomatognathic system has essential importance for clinical practitioners and surgeons in order to be able to present diagnosis and institute an adequate and necessary treatment. Despite veterinary dental books present simple or detailed descriptions of most of the surgeries, none of them describe the dental organ individually, which could contribute for the surgical act, with better precision and knowledge. Almost all of veterinary medicine and veterinary dental researches, in which the dental anatomy is cited, is limited to describing the dental formula, its differentiation, structure, formation and eruption. The individual analysis of each dental element was not found. However, such information exists in abundance in human dentistry literature. Moreover, great part of the human procedures has been done in animals, which lead us to conclude about the importance to get these information into practice. So, we describe, as analogous to the existing books of human dental anatomy, to detail and to nominate the dental organ, through photographs, facilitating the surgical procedures and supplying information that bring greater precision to the surgeon. In addition, the recognition of dysfunctions occurring from morphologic and functional alterations can also be established.

Materials and Methods: The research used ten macerated skulls, being five skulls of dogs and five skulls of cats, studying 210 teeth of dogs of the respective skulls and 130 dental elements of cats. The skulls were macerated. The dental correlations of localization and situation and its functions was made in accordance with the morphology and activity exerted in mastication and apprehension, of the number of teeth, dental formula, relative and absolute direction; correlation of this form, its relations of holotopy and sintopy. After that, the alveolectomy was accomplished and the dental elements were removed. In the morphology of the grooves and ridges on the various surfaces are described and named. The teeth were used for individual analysis: the character and location of the ridges, grooves, convexities, and concavities. They were individually analyzed, according to its characteristics in all faces and respectively nominated. The conservation and storage of teeth and skulls were made in universal collecting bottles and plastic bottles respectively, in ambient temperature, not being necessary methods of fixation. The anatomical terms have been revised in accordance with the regulations established by the *Nomenclatura Anatômica Veterinária Ilustrada* (Schaller 1999).

Results: The results were presented through photographs attempting to emphasize the dental structures. Here we will only describe the characteristics of each dental group, therefore the individual characteristics are very long. The main incisors function is to cut food. A tooth crown has five surfaces, or four surfaces and a cutting edge. The crown is usually longer than wide. The vestibular aspect is convex and the lingual is concavous. The upper incisor has three mamelons and the lower have only two mamelons. The root is conical and the apex gap. The canines have robust teeth. The mesial aspect of the crown is convex and the distal is concavous. There is an enamel ridge in the distal aspect of the upper canines. The premolars have three cusps. The cusps may be bigger or smaller, depends of the tooth. The premolar may have one, two or three roots. The molars are the last teeth of the dental arcs. The crowns can present two, three or four cusps. The molars may have one, two or three roots.

Discussion and Conclusions: It is possible to conclude that there are a great variation of sizes and morphology of skulls and this was correlate with the relative position of teeth and the diastemas. And the nomenclature of the dentition of human can be adapted for used in dog and cat.

References: Woelfe J.B. & Scheid R.C. 2000. Anatomia Dental: sua relevância para a odontologia. 5ª ed. Guanabara Koogan, Rio de Janeiro. - Schaller O. 1999. Nomenclatura Anatômica Veterinária Ilustrada. Manole, São Paulo. 614p. - Sicher H. & Dubrul E.L. 1977. Anatomia Bucal. 6ª ed. Guanabara Koogan, Rio de Janeiro. 511p. - Madeira M.C. 2001. Anatomia da Face: bases anátomo-funcionais para a prática odontológica. 3ª ed. Sarvier, São Paulo. 117p. - Madeira M.C. 2005. Anatomia do Dente. 4ª ed.rev. Sarvier, São Paulo. 128p. - Getty, R. 1975. Anatomia dos Animais Domésticos. Vol.2. 5ª ed. Guanabara Koogan, Rio de Janeiro. 1134p. - Kowalesky J. 2005. Anatomia dental de cães *(Canis familiaris)* e gatos (*Felis catus*): considerações cirúrgicas. Dissertação, Universidade de São Paulo, São Paulo. 198p.

INDEX TERMS: Dog, cat, anatomy, teeth.

021. Lage-Marques M., Mouriño J.M., Almeida T.T.D. & Miracca R.B. 2007. **Rostral mandibulectomy in a ferret (*Mustela putorios furo*).** *Pesquisa Veterinária Brasileira 27(Supl.).* Departamento de Cirurgia, FMVZ-USP, São Paulo, SP 05508-270, Brazil. E-mail: mari.lm@uol.com.br

Introduction: The ferret, *Mustela putorius furo,* is a carnivore in the family Mustelidae, which probably dates back 40 million years ago. This family includes about 23 genera and 67 especies that had been recognized in North, Central,

South America, Europe and Africa. The genus Mustela is divided into five subgenera: Mustela (weasels), Lutreola (Europe mink); Vision (American mink), Putorius (ferrets), and Grammogale (South American weasels). They showed such adaptation at different ecosystems. Some are arboreal, others fossorial and a few aquatic. The ferret domestication had occured more than 2,000 years ago, but there are not much record about this. The name "ferret" is derived from the Latin *furonem* and the Italian *furone*. "Putorius" is derived from Latin *putor*, a stench, which applies to the musky odor of the ferret. This animals have been used as a pet, biomedical research and hunting. As a result of its behavior, traits and burrowing instincts, they developed some anatomic adaptations. A long neck and placement of the carotid arteries that help the ferret to keep sufficient cerebral blood flow in tight places. With long body, short muscular legs and long tail. Their average varies in 44-46cm from nose to tip of the tail. Powerfull jaws, large canines and reduced molars. The cranial skull had the same structures of the dog and cat. They generally live between 5 and 8 years old. Both sexes exhibit seasonal fluctuations of up to 30-40% in body weight. Males can be twice larger than females, even if neutered. Most of the ferrets in Brazil came from one of the major producer, in North America. Neoplasms in ferrets probably have existed since they first evolved, but were not reported. In 1979 some cases were documented. Some researches contribute to this with the reproduction as laboratory animals (in biomedical research) and as a pet, increasing number of neoplasms. Nowadays neoplasia is the major clinical diseases in ferrets. The statistics reveals that 43.7% are endocrine system; 21.5% hemolymphatic; 11% intertegumentary. The most frequently neoplasms are pancreatic islet cell tumors (21.3%); adrenocortical cell tumors (20.1%) and lymphomas (19.1%). Multiple types of neoplasia can occur simultaneously and clinical sign vary depending of it. In ferrets, dental abnormalities are related commonlly in older patients and found incidentally on clinical examination, usually fractures of the teeth and periodontal diseases. Symptom are anorexia associated or not with swelling. Oral squamous cell carcinomas, fibrossarcomas, and salivary gland adenocarcinomas have been reported. Severe and extensive involvement of the bone is common, but the metastases are considered low. This kind of disease is rarely seen by the owner, unless the patient presents sings like increase of salivation, weight loss, halitosis, blood discharge, dysphagia, tooth loss and occasionally lymphadenopathy. The cancer diagnostic is difficult because of the wide range of oral cancers and its behavior. It is recommended thoracic radiographs associated with a good abdominal palpation. In oral cases regional radiography and computed tomographies establish the prognosis and evaluate neoplasia extension (bone, adjacent tissue, pharynx, nasal cavity and others). These subsidiary exams are suggested, in most animals, before a careful anesthesia. A biopsy and histopathologic examination are essential. The lymph nodes should be palpated and if possible a cytology with a fine needle. In ferrets it is not common because of the lymphonode diameter. A cytology preparation is contra-indicated when is associated with necrosis, inflammation or infection. The most common therapy used in oral neoplasia is surgery and cryosurgery. Radical surgeries such as mandibulectomy and maxillectomy are well tolerated by most of the patients and are indicated when there is a large bone invasion. The literature recommends margins at least 2cm for malignant cancers, like squamous cell carcinoma, malignant melanoma and fibrossarcoma. Some recent reports suggest chemotherapy and radiation therapy as adjuvant. Oral neoplasia does not respond well to this therapy alone. The cryosurgery may be indicated for lesions minimally invasive.

Case Report: The owner noticed a mass involving the rostral area of the mandible from her ferret, male, 5 years old. The mass was ulcerated and around 0,8centimeter at the rostral part of the jaw, another mass on the right upper lip with 0,3centimeter of diameter, where the inferior canine (404) made direct contact. The animal was clinically well, eating normally and without any sign, except the visible increase of volume in oral cavity, for two weeks. It was suggested an abdominal ultra-sound and X-ray to investigate the possibility of metastasis or local osteolysis. And it was detected a radiotransparency at cranial skull (arround the inferior incisors). The ferret was submitted to general anesthesia with isofluorane after oro-tracheal intubation. The histopathologic results indicated the squamous cell carcinoma. After 20 day a surgery ressection with the same anesthesia was done. The only difference was the use of pre-medication with acepromazine (0.05mg/kg) and morphine (0.3mg/kg). At surgery it was noticed an increase of mandible volume with approximately 1.5cm of diameter and 0.5cm of diameter in the right upper lip. The incision was carried through with conventional scalpel, distal to the 3rd premolar bilaterally, mucosa and gingiva was dissected and bone exposed. The bone was removed with a surgical drill and the mandible vascularization isolated bilaterally for the ligature. After that the rostral portion at the jaw was removed in block, with the canines, incisors and pre-molars teeth. For suture it was used 4-0 nylon. At the right upper lip the mass was removed without a free margin because there was no more area for excision. Postoperatively the animal was submitted to flusher with 0.12% chlorexidine, antinflammatory, antibiotic and analgesic. The ferret was very well and eating paste food and drinking water normally. Until 30 days after the surgery there was no sign of recurrence. Three months after the surgery, it showed a mass on right upper lip, a small nodular and ulcerated mass. It was suggested cryosurgery, but not approved by the owner. Since then the ferret was treated with prednisolone (1mg/kg). Five months after surgery the animal return and at that moment it was no more life quality, they choose by euthanasia.

Discussion and Conclusions: The ferret domestication occurred since more than 2,000 years ago, but many veterinarians still have doubt about how to manipulate this species. Mainly because there is only a small number of studies, we must investigate and report more about this and it's individual interaction with different therapies including neoplasms. These case showed that we can do surgery to make this animals live longer and with quality.

References: Fox J.G. 1998. Taxonomy, history and use, p.227-241. In: Idem (ed.), Biology and Diseases of the Ferret. 2nd ed. Lippincott Williams and Wilkins, Baltimore. - Graham J., Fidel J. & Mison M. 2006. Rostral maxillectomy and radiation therapy to manage squamous cell carcinoma in a ferret. Vet Clin. North Am. Exot. Anim. Pract. 9(3):701-106. - Hamilton T.A. & Morrison W.B. 1991. Bleomycin chemotherapy for metastatic squamous cell carcinoma in a ferret. J. Am. Vet. Med. Assoc. 198(1):107-108. - Lewington

J.H. 2000. General neoplasia, p.200-210. In: Idem (ed.), Ferret Husbandry, Medicine and Surgery. 1st ed. Butteworth-Heinemann, Woburn, MA - Li X. & Fox J.G. 1998. Neoplastic diseases, p.405-447. In: Fox J.G. (ed.), Biology and Diseases of the Ferret. 2nd ed. Lippincott Williams and Wilkins, Baltimore. - Lloyd M. 1999. Anatomy, p.3-12. In: Idem (ed.), Ferrets: health, husbandry and diseases. 1st ed. Blackwell Science, Woburn, MA .- Lloyd M. 1999. Neoplasia, p.120-137. In: Idem (ed.), Ferrets: health, husbandry and diseases. 1st ed. Blackwell Science, Woburn, MA .- Olsen G.H., Turk M.A. & Foil C.S. 1985. Disseminated cutaneous squamous cell carcinoma in a ferret. J. Am. Vet. Med. Assoc. 186(7):702-703. - Withrow S.J. 1989. Tumors of the gastrointestinal system, cancer of the oral cavity, p.227-241. In: Withrow S.J. & MacEwen E.G (ed.), Small Animal Clinical Oncology. 2nd ed. W.B. Saunders, Philadélphia, Pensillvanya.

INDEX TERMS: Ferret, mandibulectomy, squamous cell carcinoma.

022. Madrid S. & Valenzuela M. 2007. **Use of topic Cyclosporine in one cat with feline gingivostomatitis.** *Pesquisa Veterinária Brasileira 27(Supl.).*

Clinical Veterinary Hospital, University of Chile, Medical Feline Center of Reference Moggie Cat's. E-mail: soniamadridvet@yahoo.es

Introduction: Feline chronic gingivostomatitis (FCGS) is an oral disease of unknown etiology and frequent presentation, characterized for chronic and persistent inflammation of oral tissue, also presenting ulceration and proliferation of mucogingival tissue and glossopharyngeal folds. It has uncertain prognosis and sometimes is untreatable (Anderson 2003).

Case Report: The patient was a 2.5-year-old red stripped tabby queen called "Niña" of 2.9 kg weight. She had no vaccines, was dewormed and ate commercial food. The patient had been treated with antibiotics and NSAIDS for a previous case of gingivitis, but reappeared when stopping medications. - Owner's complaint was anorexia, weight loss and sialorrhea. Physical exam showed a body condition (BC) of 2/5, she was depressed, scared and had tangled hair. Physiological parameters (T°, HR, RR) were within normal limits, she had pale ocular mucous membranes, 7% dehydration and no relevant abnormalities in abdominal compression. Intraoral exam showed pain upon opening mouth, sialorrhea, gingivitis, bilateral faucitis, bleeding and friable mucosa. When examining under general anesthesia there was little tartar and no periodontal disease. Radiographic evaluation excluded the presence of feline odontoclastic resorptive lesion (FORL). - Feline chronic gingivostomatitis, eosinophilic granuloma, squamous cell carcinoma, and retroviruses (Feline Leukemia Virus and Feline Immunodeficiency Virus) were considered as possible diagnoses. Complementary exams were suggested. Laboratory Exams were taken: complete blood work was made including: CBC, biochemical panel (both within normal ranges), FIV and FELV testing (both negative) and oral lesion biopsy. Biopsy informed mucous and submucous inflammatory lympho-plasmocytic infiltration, establishing the diagnosis of lympho-plasmocytic feline chronic gingivostomatitis. -Treatment: The patient underwent periodontal treatment (dental mechanical hygiene) and extraction of all dental pieces except for the following teeth: 104, 204, 304, and 404. She received a prescription for amoxicillin (20mg/kg TID PO), Metronidazole (10mg/ kg BID PO) and Prednisone (1 mg/kg BID for a week, tapering dose 50% each following week ending with 1mg/kg EOD for 7 times). Intralesional triamcinolone was applied before the surgery. - Post surgical evaluation showed improvement in premolar and molar areas but no changes in faucitis. Three weeks later a long acting deposit corticoid was prescribed (Methylprednisolone 20mg/cat IM) diminishing oral lesions. Six weeks later she presented new lesions showing bloody and friable mucosa, pain and salivation. She received again methylprednisolone using the same dose. She came back before the 6 week period with dermatologic lesions such as diffuse alopecia, thin skin and angioedema in the abdominal area. - Corticoid administration was suspended and a Cyclosporine therapy was made in a topical oral presentation of 0.5 %. Oral ointment was applied directly over the affected areas every 12 hours for a month. A 3-week later evaluation showed significant improvement of faucitis, hair condition and an increase of 200g weight. The next evaluation (30 days later), faucitis was completely absent and complete blood work panel was normal. - Evaluations were made 2 and 4 months after suspending treatment, no oral lesions were found. A year later the patient didn't show any oral lesion, her final weight was 3.6 kg.

Discussion and Conclusions: The present case involved a domestic feline queen; literature says that it can affect cats of any age and breed, although there is some controversy pure breeds such as Siamese, Persians, Himalayan and Burmese cats can be overrepresented (Cristal 2000). - The patient underwent the detection of Feline Leukemia Virus antigens and Feline Immunodeficiency Virus antibodies, because FIV has an important role in FCGS. Both testings were negative. Different authors have found FIV to be present in 10 to 81% of FCGS cases. Oral inflammation is also very common in cats positive to FELV, which is shed in high concentration in saliva of persistent carrier cats. However other studies have failed to show any association between severity of oral lesions and concurrent infection by FELV. Prevalence of infection with this virus in FCGS cases has been consistently low in different studies with values that go between 0% and 20% (Ueno 1996, Harley 2003). - In this case the exact cause of the pathology couldn't be established, but most authors' theories imply that cats with FCGS have a severe inflammatory response derived from an immunologic dysfunction. Peripheral T CD4 cells (T helper cells) and high levels of T CD8 cells (T cytotoxic and suppressor cells) have been found (Harley et. al. 2003a,b) showing associations with other infectious agents (bacteria and viruses) like *Bartonella henselae* (Anderson 2003, Ueno 1996). In Chile there aren't testing available for *B. henselae* or calicivirus, despite the fact that they are highly associated with this disease. *B. henselae* testing is only available for humans. - The patient showed characteristic signs of FCGS: weight loss, salivation, oral pain, halitosis. The affected area was symmetrical, inflamed, ulcerated and granular. Oral mucosa lesions were in the gingiva, glosopalatin arches and pharynx which is consistent with findings mentioned by several authors (Harvey 1994, Klein 1999, Sparker 2001). -Even though clinical signs were similar to findings described by specialists, a biopsy was made to rule out other possible diseases like squamous cell carcinoma and eosinophilic granuloma. Biopsy showed great number of inflammatory cells (neutrophils), lymphocytes and plasmatic cells. Lymphocyte and plasmatic cell infiltration was found in chronically exposed connective tissue, also there was mucosal hyperplasia with great infiltration of the same cells. A small number of neutrophils, eosinophils and macrophages were found in the submucosa (Anderson 2003, Harley 2003c). - In many patients tooth extractions (molars and premolars) by itself is an effective treatment. Eighty percent of the patients respond successfully to dental extractions and the 20% remaining are refractory. Our patient was in this 20% that showed no response to corticoid and dental procedure (Hennet 1997). A proven and effective treatment

protocol was instituted. It consisted in dental mechanical hygiene, dental extraction of affected pieces, subgingival injection of triamcinolone 10mg/cat as maximal dose plus antibiotic therapy (Smith 2001). - Injections of methylprednisolone were used without good results because the disease reappeared (Harvey 1994). Many cats are resistant to corticoid therapy and their administration must be made with higher frequency, increasing the risk of secondary reactions such as Cushing's syndrome, diabetes mellitus and frail skin syndrome. - As an alternative for corticoid therapy other inmunosuppressor drugs with Aurotioglucose or Aurotiomalate have been used at dose of 1mg/kg once a week, secondary effects of this drugs must be considered (Anderson 2003, Hawkins 2001). Other mentioned therapies are bovine lactoferrin, azathioprine (0.3 mg/kg EOD) and piroxicam at 0.3mg/ kg EOD (Anderson 2003). -Cyclosporine has been suggested for local topical treatment as ointment in 0,5% or in tablets using oral dosage of 3mg/kg BID for a maximum of 3 months or until clinical cure. Other authors prefer an oral dose of 5mg/ kg BID. In this case renal and hepatic evaluations must be made. Secondary reactions are soft stools, gingival hyperplasia, nephrotoxicity, hepatotoxicity and immunosuppresion. Remission is described but the economical cost is expensive (Harvey & Brethnach 2004). In this case topical cyclosporine 0.5% ointment (prepared in a base that insured adherence to damaged mucosa) was used showing positive results 30 days after starting treatment and full recovery in 6 months, allowing the patient to gain weight and improve her general condition. A year later there were no signs of the disease. - Cyclosporine has the ability to inhibit enzymes that catalyze reactions necessary for the immunologic system, it alters the proliferation of T helper cells, T cytotoxic cells and leads to significant and reversible immunosuppression, maintaining the function of B cells (Anderson 2003, Harvey & Brethnach 2004). In this patient blood work was made without abnormal findings.

References: Anderson J. 2003. Diagnóstico y tratamiento de la gingivo-estomatitis en los gatos. Waltham, Focus. 13(3):4-10. - Crystal M.A. 2000. Gingivitis, estomatitis, faringitis, p.228-231. In: El Paciente Felino: bases del diagnóstico y tratamiento. InterMédica, Buenos Aires. - Harley R., Gruffydd-Jones T.J. & Day M.J. 2003a. Salivary and serum immunoglobulin levels in cats with chronic gingivostomatitis. J. Vet. Rec. 152: 125-129. - Harley R., Gruffydd-Jones T.J. & Day M.J. 2003b. Characterization of immune cell populations in oral mucosal tissue of healthy adult cats. J. Comp. Pathol. 128:146-155. - Harley R. 2003c. Feline gingivostomatitis, p:34-41 In: Proc. Hill's Europ. Symp. Oral Care, Amsterdam. - Harvey C. & Brethnach R. 2004. The oral cavity, p.379-395. In: Chandler E. & Gaskell C. (ed.), Feline Medicine and Therapeutics. Blackwell Publishing, Oxford, UK. - Harvey C. Plasmocytic-lymphocytic stomatitis, p:59-63. In: John A.R. (ed.), Consultations in Feline Internal Medicine. Saunders Company, Philadelphia. - Harvey C.E. 2003. Periodontal therapy in cats: what's new, p.184-185. In: Proc. North Am. Vet. Conf., Orlando, Florida. - Hawkins B.J. 2001. Stomatitis in Cats and Dogs: what may help, p.111-113. In: Proc. North Am. Vet. Conf., Orlando, Florida. - Hennet P. 1997. Chronic gingivo-stomatitis in cats: a long term follow-up of 30 cases treated by dental extractions. J. Vet. Dent. 14(1):15-21. - Klein T.J. 1999. Advances in feline dentistry, p.96-99. In: Proc. 23rd Waltham/OSU Symp. Treatment Small Anim. Disease, Ohio, USA. - Smith M. 2001. Management of feline stomatitis and gingivitis, p.188. In: Proc. North Am. Vet. Conf., Orlando, Florida. - Sparkes A.H. 2001. Feline Upper Respiratory Disease, p.579-580. In: Proc. North Am. Vet. Conf., Orlando, Florida. - Ueno H., Hohdatsu T., Muramatsu Y., Koyama H. & Morita C. 1996. Does coinfection of *Bartonella henselae* and FIV induce clinical disorders in cats? Microbiol. Immunol. 40(9):617-620.

INDEX TERMS: Feline gingivoestomatitis, cyclosporine treatment.

023. Maia J.Z.[1], Witz M.I.[1], Pinto V.M.[1], Oliveira M.E.M.[2] & Leães A.N.[2] 2007. **Retrospective study on the incidence of mandible fractures in the small animal clinic at Brazil Lutheran University Veterinary Hospital (HV-ULBRA), from 2000 to 2005.** *Pesquisa Veterinária Brasileira 27(Supl.).* [1]Departamento de Cirurgia Veterinária, ULBRA, Canoas, RS, Brazil; [2]Aluno de Residência Médica Veterinária, ULBRA, E-mail: juzanimaia@yahoo.com.br

Introduction: Mandible fractures sum up to 3% of all fractures in canines and 15% in felines. Mandible fractures usually present traumatic etiology such as running over, falls or other forms of trauma. They are mainly characterized by edema, deviation of the fracture segments, dental malocclusion and the presence of saliva with blood streams (Piermattei & Flo 1999). Roza (2004) and Hulse & Johnson (2002) mention as a possible cause of mandible fractures, especially in small breeds, the advanced periodontal disease, which causes bone loss, leading to spontaneous fractures. Piermattei & Flo (1999) describe that, with rare exception, all mandible fractures are open and contaminated or infected. These fractures may be unilateral or bilateral, with single or multiple fracture lines. Symphysis fractures are the most common lesions in cats (73%), and fractures in the mandible body area are the most common in dogs. Lopes et al. (2005) wrote a retrospective study in which was observed that young dos and dog over 8 years of age were the most affected by maxilla or mandible fractures. Dog fight was the most common etiology (43%), followed by unknown cause, which happened to 23% of the dogs, while pathologic fractures occurred in 13% of cases. The objectives of corrections to the orthognathic system are occlusion correction, return to feeding as soon as possible, adequate stability, maintenance of the greatest number of teeth (Roza 2004). Generally, consolidation is rapid (three to five weeks) at the rostral portion of the mandible, but slower (four to seventeen weeks) at the caudal region. Exception to this generalized information about consolidation are fractures infected and symphysis fractures in old "toy" breed dogs, in whom considerable osteoporosis precedes the fracture. Complications are fairly commun, 34% in dogs, with malocclusion being the most common followed by infection and delayed union (Piermattei & Flo 1999). This study aims to show and evaluate mandible fracture cases taken in at HV-ULBRA, between January 11, 2000 and May 30, 2006.

Materials and Methods: The animals used in this study come from HV-ULBRA's clinical routine. Between January 11, 2000 and May 30, 2006 a total of 46 patients were attended with mandible fractures (23 dogs and 23 cats). These patients 54 mandible fractures with different locations and etiologies were diagnosed.

Results: Among the animals assisted, the higher incidence of mandible fracture appeared in patients without definite breed, followed by Poodle and Pinscher dogs, and felines of the Siamese

breed. Most of the canines presented fracture by bite trauma, for being run over or trauma with unknown origin. On the other hand, felines presented trauma with unknown origin, running over and falls as most common etiologies. Of all 46 animals assisted 30.43% were less than 1 year old; 43.47% were between 1 and 5 years old, and 26.1% were between 6 and 14 years old. In dogs, 45.15% of the fractures were unilateral and located on the mandible body area; 26.92% were mandible symphysis fractures, 19.23% were bilateral body fractures, and 8.7 % were mandible ramus fractures. In cats, 75% of the fractures were located on the mandible symphysis; 17.86% were unilateral body fractures, and 7.14% were bilateral mandible body fractures.

Discussion and Conclusions: Mandible fractures occur often in dogs and cats, but etiology differs due to the habits of each species. In this study the most common location of mandible fractures were the mandible body on dogs and mandible symphysis on cats. Ages between 1 and 5 years and traumatic etiology were the most prevalent in this study.

References: Hulse D.A. & Johnson A.L.1997. Management os Specific Fractures, 767- 778. In: Fossum T.W. (ed.), Small Animal Surgery. Mosby-Year Book, St Louis. - Lopes F.M., Gioso M.A., Ferro D.G. et al. 2005. Oral fractures in dogs of Brazil: a retrospective study. J. Vet. Dentistry 22(2): 86-90. - Piermatei D.L. & Flo G.L. 1999. Fraturas e luxações da mandíbula e maxilar superior, 613-628. In: Idem (ed.), Manual de Ortopedia e Tratamento das Fraturas dos Pequenos Animais. 3ª ed. Manole, São Paulo. - Roza M.R. 2004. Cirurgia dentária e da cavidade oral, 167-190. In: Idem (ed.), Odontologia em Pequenos Animais. L.F. Livros de Veterinária, Rio de Janeiro.

INDEX TERMS: Mandible fractures, oral fractures, mandible symphysis.

024. Maia J.Z.[1], Witz M.I[1], Salles A.A.[2] & Allgayer M.C.[3] 2007. **Intraperitoneal injection of different concentrations of sodium hypochloride: a study in rats.** *Pesquisa Veterinária Brasileira 27(Supl.).* [1]Departamento de Cirurgia Veterinária, Faculdade de Medicina Veterinária, ULBRA; [2]Departamento de Endodontia, Faculdade de Odontologia, ULBRA; [3]Departamento de Analises Clínicas, Faculdade de Medicina Veterinária, ULBRA, Canoas, RS, Brazil. E-mail: juzanimaia@yahoo.com.br

Introduction: The mechanical chemical preparation of the root canals represents one of the most important of the endodontic treatments, and the sodium hypochloride is the most used chemical substance for this purpose (Hales et al. 2001). The objective of this study was to evaluate the inflammatory response through the cellular reaction caused by different concentrations of sodium hypochloride: 1%, 2.5% and 4% of active chlorine, comparatively to the physiological solution, after intraperitoneal injection in Whistar rats. Were analysed global counting of inflammatory cells and protein dosages of the peritoneal washings. As result it was observed that all the correlations were not significant, indicating that there is not relation between the analyzed variable, however the increase of the concentration of the sodium hypochloride developed significantly the proteinic infiltrated one, demonstrating that this solution causes intense inflammatory response even in low concentration, being the concentration a determinative factor of the cytotoxic potential of the solution.

Materials and Methods: 32 Whistar rats were used, randomly distributed into 4 groups. Group C: NaCl solution at 0.9%. Group 1%: sodium hypochloride solution at 1%. Group 2.5%: sodium hypochloride solution at 2.5%. Group 4%: sodium hypochloride solution at 4%. 0.3 ml of the solutions was administered in the peritoneal cavity of each rat, using the paramedian approach with a hypodermic sterile needle. 72 hours later the euthanasia of the animals was done and, later, the cleansing of the peritoneal cavity with 4 ml of PBS solution and it was collected 3ml of this liquid. From the collected liquid a global counting of inflammatory cells and total proteins was made. The values from the counting of the 4 groups were characterized and statistically analyzed through the Kruskal Wallis test for analysing the groups and correlations were established between the variants.

Results: The values from the inflammatory cells global counting and total protein dosage of the 4 experimental groups are expressed in Tables 1 and 2. Table 3 represents the investigation of the possibility of correlation between the inflammatory cells global counting and total protein dosage.

Table 1. Kruskal-Wallis test for comparing the global counting between the groups

	Group	Minimum	Médium	Maximum	P value
Inflammatory global cells Counting (mm3)	C	1300	3700[a]	6100	0.013*
	1%	2600	8000[b]	9300	
	2.5%	5000	8500[b]	14600	
	4%	1300	4600[c]	9100	

*Significant statistic difference between groups at 5% level. Average levels followed by the same letter do not differ quite significantly by the Mann-Whitney test (5%).

Table 2. Kruskal-Wallis test for protein comparison between groups

	Group	Minimum	Médium	Maximum	P value
Total protein (g/dL)	C	0,310	0.430	0.730[a]	0.014*
	1%	0.620	0.730	2.030[b]	
	2.5%	0.360	1.460	2.870[b]	
	4%	0.400	3.250	9.680[c]	

*Significant statistic difference between groups at 5% level. Average levels followed by the same letter don't differ quite significantly by the Mann-Whitney test (5%).

Table 3. Correlation between the analysed average levels

Group	Correlation[a]	P value
C	0.053	0.909
1%	-0.276	0.549
2.5%	0.292	0.525
4%	-0.502	0.251

[a] All correlations were non-significant, indicating that there is no relation between the average levels.

Discussion and Conclusions: The main aim of mechanical chemical preparation is the cleansing and modelling of the root canal systems. In order to obtain such intent, the combined utilization of auxiliary chemical substances and tools during the preparation stage is essential, the non-utilization of these chemical substances results in the remaining of micro organisms and dirt within the root canal. The sodium hypochloride has been used as an endodontic irrigatory solution for over four decades, however, being toxic to the periapical tissue (Kuruvilla & Kamath 1998, Siqueira Jr et al. 1998). The evaluation method of the inflammatory response facing the different materials of endodontic usage has been experimented from the migration of inflammatory cells to the peritoneal cavity in rats (Tanomaru Filho et al. 2002). In particular, in this study it was demonstrated that the capacity of provoking the protein exudation of the control solution (physiological serum) was discreet when compared to the tested sodium hypochloride solutions, reflecting the aggression promoted by the process of inoculation, as well as the chemical reaction in the area. The data were statistically analysed by the Kruskal-Wallis non-parametric test, complemented by the Mann-Whitney test due to the large variability between the average levels in the different groups. The analysis of inflammatory cells global counting in the experimental groups, expressed by the average levels, was analogue to the utilization of the sodium hypochloride at 1% and 2.5%, statistically different from the 4% group and control. It is well worth remarking that the smallest average level of inflammatory cells from the 4% group is justified by the shorter aggression time, given that this group's specimens were slaughtered with 72 hours experimental period. Parallel to that, a significant raise in the number of proteins has been observed in the peritoneal cavities, fact directly related to the raise in concentration of the test solutions and indicative of higher toxicity. A probable justification is represented by the tissue irritation induced by the capacity of the sodium hypochloride of dissolving organic matter (Gordon et al. 198, Grossman & Meinman 1941). In agreement with our findings is the study from Leonardo et al. (1984), from Yesilsoy et al. (1995) and from Siqueira Jr et al. (1998) who observed the aggressive effect of the hypochloride, particularly with high concentrations. In this study, similarly to other methodological lines which used rats (Pasternak et al. 2002) and from Tanomaru Filho et al. (2002), we worked with tested solutions directly in the peritoneal cavities, evidencing of the real cytotoxic potential on cells and tissues; such lesion demonstrated depend upon concentration, being more expressive in the group of the sodium hypochloride at 4%, where it could be observed intense hemolysis, in accordance to Santos & Sampaio (2002). However, it is important to highlight that when such substances are used in the endodontic clinic routine, possible toxic effects on the cells in normal conditions are minimized. Many researchers observed that the sodium hypochloride did not present harmful effects to the apical region when used in concentrations of up to 5%, even when kept in the canal as a intracanal dressing, where the periapical tissue kept a regular structure, without leakage of inflammatory cells (Tepel et al. 1994). Such assertion is justified by the reduction of the contact between the solution, independent of the concentration, and the apical tissues which is given essentially by the apical foramen. Having in mind the exposed and the described previous results, the utilization of sodium hypochloride solutions in high concentrations (higher than 2.5%) must be indicated with restrictions, fundamentally when applied by students and inexperienced professionals. Furthermore, in special incomplete rhizogenesis clinical situations, ample foramens, reabsorptions, and perforations, more attention must be paid, due to the higher probability of extrusions of such chemical substance in larger volumes, mainly when an excessive pressure is applied to the syringe at the moment of the irrigation. So, although the sodium hypochloride is a chemical substance of outine use for presenting a higher quantity of desirable properties, due to its cytotoxic potential we agree with Hales et al. (2001) that it is necessary to search for knowledge and for routines which allow adequate and safe results, consequently facilitating the cure reaction process. Facing the results attained it is valid to affirm that no correlation between the global cell counting and total protein dosage has been observed; the tested sodium hypochloride solutions, independent of the concentration, caused tissue damage, represented by the average total protein levels ($p=0.014$); sodium hypochloride in the concentrations of 1% and 2.5% presented similar cytotoxic effects, diverting significantly from the more concentrated solution, at 4% and from the control solution; the sodium hypochloride in direct contact with the peritoneal tissue was irritating and toxic.

References: Gordon et al. 1981. Solvent effect of various dilutions of sodium hypochloride on vital and necrotic tissue. J. Endod. 7(10):466-469. - Grossman L.I. & Meiman B.W. 1941. Dissolution of pulp tissue by chemical Agents. J. Am. Dent. Assoc. 28(2) :223-225. - Hales J.J. et al. 2001. Treatment protocol for the management of a sodium hypochloride accident during endodontic therapy. Gen. Dent. 49(3):278-281. - Kuruvilla J.R. & Kamath P. 1998. Antimicrobial activity of 2.5% sodium hypochloride and 0.2% chlorexidine gluconate separately and combined, as endodontic irrigants. J. Endod. 24(7):472-476. - Leonardo M.R. et al. 1984. Immediate root canal filling: the use of cytophylactic substances and noncytotoxic solutions. J. Endod, 10(1):1-8. - Pasternak J.R. et al. 2002. Avaliação da biocompatibilidade de soluções de hipoclorito de sódio, clorexidina e uma combinação destas. JBE, Curitiba, 3(10):233-236. - Santos A.J. & Sampaio M.I.C. 2002. Efeito hemolítico e hemoglobinolítico de algumas soluções utilizadas como auxiliares no preparo biomecânico do sistema de canais radiculares, através de diluição em soro fisiológico normal *(in vitro)*. odontologia.com.br, abril. Disponível em http://www.odontologia.com.br/artigos.asp?id=136. - Siqueira J.R. et al. 1998. Antibacterial effects of endodontic irrigants on black-pigmented Gram-negative anaerobes and facultative bacteria. J. Endod. 24(6):414-416. - Tanomaru Filho M. et al. 2002. Inflammatory response to different endodontic irrigating solutions. Int. Endod. J. 35(9) :735-739. - Tepel J. et al. 1994. Reaction of inflamed periapical tissue to intracanal medicaments and root canal sealers. Endod. Dent. Traumatolol.10:233-238. - Yesilsoy C. et al. 1995. Antimicrobial and toxic effects of established and potential root canal irrigants. J. Endod. 21(10):513-515.

INDEX TERMS: Sodium hypochloride, toxicity, rats, chemical substance auxiliary.

025. Maia J.Z[1], Witz M.I.[1], Norte D.M.[2], Koech C.P.[3], Esmeraldino A.M.T.[4] 2007. ***Pemphigus vulgaris* in a dog: case report.** *Pesquisa Veterinária Brasileira 27(Supl.* [1]Departamento de Cirurgia Veterinária, ULBRA, Canoas, RS, Brazil. [2]Aluno de Residência Médica Veterinária, ULBRA; [3]Departamento de Clínica Médica Veterinária, ULBRA; [4]Departamento de Histologia Veterinária, ULBRA. E-mail: juzanimaia@yahoo.com.br

Introduction: Pemphigus is the most common autoimmune skin disease in cats and dogs. It is an erosive and ulcerative autoimmune disease that affects the skin and mouth mucous membrane due to the deposition of auto-antibodies on epidermal cells (Fioravanti et al. 2004). Records show that 90% of the cases happened with dogs while only 10% afflicted felines. Most common lesions are lip, palate, tongue and mucocutaneous junctions (breeds like Akita, Chow Chow, Collie, Dachschund, Doberman and Rottweiller are the most predisposed to this dermatosis (Rhodes 2003). No sex or age predisposition is observed, but it occurs more often in young adults. Autoimmune diseases that affect the mouth must be differentiated from allergic reactions to drugs and also from toxic epidermal necrolysis (San Roman et al. 1999). Usually the animal shows erythematic macules that quickly progress to pustules and later to yellowish crusty lesions. These lesions usually appear in the auricular pavillions, perioral areas, periocular areas, nasal plane e claw beds, and manifest less frequently on the oral and mucocutaneous areas (Rhodes 2003). This work aims to describe a case of *Pemphigus vulgaris* in a dog, Akita, 3.5 years old male taken in at ULBRA Veterinary Hospital.

Materials and Methods: Canine, Akita, male, 3.5 years old was taken to ULBRA Veterinary Hospital with intense halitosis and anorexia, a recurrent clinical signal for longer than 8 months. In specific clinical examination the presence of ulcers in the oral mucous membrane and mucocutaneous junction of the oral cavity, abundant purulent secretion, intense oral pain and halitosis was verified. The patient was anesthetized, an incisional biopsy was performed and the material was sent to histopathology. The result of the histopathological exam accused *Pemphigus vulgaris*. The adopted therapy was the use of prednisone, 5mg/kg BID metronidazole 30mg/kg BID, oral hygiene with physiological solution SID and return in 7 days for re-evaluation. Upon return the patient seemed active and the oral lesions were 80% healed. The gradual reduction of the prednisone dose and interruption of metronidazole was recomended on the 10th day of treatment. For the prednisone dose reduction was prescribed: 4mg/kg BID for 4 days; 3mg/kg BID, 4 days; 2mg/kg BID, 4 days; 1mg/kg BID, 4 days; 1mg/kg SID, 4 days; 0.5mg/kg SID, 4 days and the same dose for 4 more days in alternance. This prescription afforded 28 more days of treatment and the patient was dismissed with total remission of the symptoms. 75 days after the end of treatment, the patient returned for assistance at ULBRA Veterinary Hospital with recurrence of the clinical signs, but much less intensive when compared to the previous instance. Hence was adopted the same clinical therapy with prednisone and metronidazole. After five days of treatment the patient showed clinical improvement, with total remission of the oral mucous membrane and mucocutaneous lesions.

Results: The treatment indicated in this clinical case was satisfactory for *Pemphigus vulgaris* lesion control.

Discussion and Conclusions: Diagnosis was made through histopathology, while in literature is indicated to be made by direct intact pustule smear slides, antinuclear antibody tests, histopathology or direct immunofluorescent antibody test (Harvey & Emily 1993, Wiggs & Lobprice 1997, San Roman et al. 1999, Rhodes 2003, Fioravanti et al. 2004). The treatment established aimed to keep the infection under satisfactory remission with safe medication dosage. Prednisone was used for it. Therapeutical protocols may be based on steroid administration (Rhodes 2003, Fioravanti et al. 2004, San Roman et al. 1999, Wiggs & Lobprise 1997) or steroid administration combined with immunossupressor agents such as azathioprine, cyclosporine, clorambucil and cyclofosfamide (San Roman et al. 1999, Rhodes 2003, Fioravanti et al. 2004).

References: Fioravanti M.C.S. et al. 2004. Doenças da cavidade oral, p.258-259. In: Roza M.C. (ed.), Odontologia em Pequenos Animais. L.F. Livros, Rio de Janeiro. - Harvey C.E. & Emily P. P. 1993. Oral inflammatory and imune mediated diseases, p.147. In: Idem (ed.), Small Animal Dentistry. Mosby, St Louis. - Wiggs R.B. & Lobprise H.B.C. 1997. Clinical oral pathology, p.118. In: Idem (ed.), Veterinary Dentistry, Principle and Practice. Lippincott Raven, Philadelphia. Rhode K.H. 2003. Dermatoses imunomediadas, p.384-389. In: Birchard S.J. & Sherding R.G. (ed.), Manual Saunders Clínica de Pequenos Animais. Roca, São Paulo. - San Roman F. et al. 1999. Enfermidade inflamatória da cavidade oral em pequenos animais, p.131-132. In: San Roman F. (ed.), Atlas de Odontologia de Pequenos Animais. Manole, São Paulo.

INDEX TERMS: *Pemphigus vulgaris*; autoimmune disease; oral ulceration.

026. Pimentel L.F.R.O., Zoppa A., Alves G.E.S. & Amaral R.F. 2007. **Equine dental disosders: review of 607 cases.** *Pesquisa Veterinária Brasileira 27(Supl.).* Mestrando, Departamento de Cirurgia de Grandes Animais, FMVZ-USP, ão Paulo, Brazil. E-mail: luizrapp@unisys.com.br

Introduction: Equine dental disorders have clinical importance(Dixon et al. 1999). These disorders are classified as the third more commum problem to the equine practitioners in the United States (Traub-Dargatz et al. 1991). Even though, the equine dentistry is few teached at Universities in Europe and United States yet (Lowder 1997).The rate of meets of dental disorders and in oral cavity have a big variability, may be because the clinic exam is very difficult (Uhlinger 1987): Silbresbiepe & Berger (1954) meet 6% of dental disorders, but Anon (1965) 10%, Uhlinger (1987) 24%. Kirkland et al. (1994) examed 500 skuls in a slaughterhouse and discovered evidences of dental and oral cavity disorders in 80% of the specimens investigated. - The purpose of this study is to analyse the clinic discovery of 607 equine dental procedures. Cases review of 607 horses confined to stalls submit to service of equine dentistry shows a ocurrence of disorders discovered in oral cavity; bad oclusion of incisors and cheek teeth (hooks, beaks, ramps, waves, step and fractures), retention of deciduos

Premolars (caps) ,tooth absent, infundibular caries, occurence of first Premolar (wolf tooth and blind wolf tooth).

Materials and Methods: 607 horses were examined by the first author, in Brazil, at São Paulo, Minas Gerais and Rio de Janeiro states from 2001 to 2005. Cases whose informations were lost or not complete were reject. 374 (61.6%) males and 233 (31.4%) females, of following breeds: Brasileiro de Hipismo 287 (47%), Lusitano 86 (14.2%), Mangalarga Marchador 54 (8.9%), Througbreed 48 (7.9%), Quarter horse 44 (7.2%), Mangalarga Paulista 28 (4.2%) and others breeds 60 (10.2%) were examed. Animals age was from 2 years to 22 years old. After put the McPherson dental speculum, the oral cavity was washed with water and examined by manual palpation and visual inspection with a dental mirror (Backer & Easley 2005). The discoveries were identified and noted in equine dental charts using the modified Triadan system (Easley 1996). It is possible that in other studies, with diferent breeds and ages, occur diversification at incidence of discovers in the equine dental avaliation.

Results: Incisors; 607 animals examined it was noted that 273(44.97%) had problems in deciduos: 190 (31.3%) ventral curvature, 30 (4.9%)dorsal curvature, 46 (7.6%)overjet and 7 (1.4%) underbite. In 250 (91.57%) of 273 cases noticed the presence of diagonal curvature concomitant with others disorders. Incisors fractures: in 15 (2.47%) fractures, 13 (86.7%) were in the first incisor and 2 (13.3%)were in the thrid incisor. Retained deciduos Incisors: In 89 (14.6%) cases, 19 (21.3%) were localized at first Incisor, 20 (22.8%) at second Incisors and 50 (55.9%) at thrid Incisors . Cheeck Teeth; the oclusion disorders looked different acording to the patology and site of diseased teeth: Hooks and beaks in 1010 teeth; 495 (49.9%) rostral and 515 (50.1%) caudal.Waves in 1825 teeth; 465 (25.5%) in 108, 208, 308 and 408 (PM4), 453 (24.8%) in 109, 209, 309 and 409 (M1), 501(27.45%) in 110, 210, 310 and 410 (M2) e 406 (22.25%) in other teeth. Steps in 2122 teeth; 367 (17.3%) in 108, 208, 308 and 408 (PM4), 436 (20.5%) in 109, 209, 309 and 409 (M1), 727 (34.3%) in 110, 210, 310 and 410 (M2), and 592 (27.9%) in other teeth. 201 fractured teeth were looked; 65 (32.3%) fractures in 108, 208, 308 and 408 (M1), 112 (55.7%) in 109, 209, 309 and 409 M2 (55.7%) e 24 (12%) in other teeth. 40 teeth were absent; 4 (10 %) were 106, 206 208 or 209(PM2), 2 (5 %) were 207 and 307 (PM3), 10 (25%) were 108, 208, 308 or 408 (PM4), 12 (30%) were 109, 209, 309 or 210 (M1) and 12 (30%) were 110, 210, 310 or 410 (M2). 136 teeth showed carie infundibular, 3 (2.2%) in 106 and 206 (PM2), 5 (3.6%) in 107 and 207 (PM3), 22 (16.2%) in 108 and 208 (PM4), 81 (59.6%) in109 and 209 (M1), 21 (15.5%) in 110 and 210 (M2) e 4 (2.9%) in 111 and 211(M3). There were 250 (20.6%) PM1 ("Wolf tooth), with 229 (91.4%) in 105 and 205, 1 (0.4%) in 405 and 20 (8%) didn´t have eruption at oral mucosa ("blind Wolf tooth"). Ulcers; during the clinical exam, 1709 wounds or ulcers in the vestibular mucosa were discovered.These lesions were located beside the following teeth: 132 (7.7%) beside 106 and 206 (PM2), 267 (15.6%) beside 109 and 209 (M1), 688 (40.3%) beside 110 and 210 (M2), 460 (26.9%) beside 111 and 211(M3) and 162 (9.5%) beside other teeth. 607 horses were examined, 81(13.4%) showed scars in the tongue and 71(11.7%) showed wounds or hematoma in the bars.

Discussion and Conclusions: The high incidence of desorders in the Incisors (44.97%) is a consequence when horses are confined to stall. Easley (1996) wrote that the function of the Incisor is to cut the forage during the grazing. Confined animals do not use the Incisors to shearing, and woul lead to Incisor overgrowth from back of attrition.This would make possibile a higher incidence of Incisors disorders. The incidence of 8% of blind Wolf teeth from all PM1 discovered suggests a special care at this region during the clinic dental exam. The high concentration of oclusion disorders, fractures and infundibular caries at PM4, M1 e M2 teeth suggests that prematurity and oclusal trauma in these sites occur (Pimentel 2004), problably because this is a transition region between diphyodont and heterodont teeth Easley (1996), and there is the Spee curve in M1 and M2 (La Flure, 2003). With this datums, we can conclue that the prophilactic dental procedures(Alves 2004), with the subject to obtain the ideal functional oclusion (Pimentel 2004) is fundamental to dental arcade and oral cavity of horses sanity and not only float sharp emanel points.

References: Alves G.E.S. 2004. Odontologia como parte da gastroenterologia, sanidade dentária e digestibilidade. In: 6º Congresso Brasileiro de Cirurgia e Anestesiologia Veterinária, Indaiatuba, SP. - Mini-Curso Odontologia Eqüina 2004. Editora Faculdade de Jaguariúna (FAJ), SP, p.7-22. - Anon L. 1965. British Equine Veterinary Association Survey of Equine. Disease. Vet. Rec. 77:528-538. - Dixon P.M., Treamine W.H., Pickles K. et al. 1999. Equine dental disease. Part 1. A long-term study of 400 cases: disorders of incisor, canine and first premolar teeth. Equine Vet. J. 31:369-377. - Easley J. 1996. Equine dental development and anatomy. Proc. Am. Assoc. Equine Pract. 42:1-10. - Easley, J. 2005. Dental and oral examination, p.151-169. In: Backer G.J. & Easley J. (ed.), Equine Dentistry. W.B. Saunders, London. - Kirkiland K.D., Mareta S.M. & Inoue O.J. 1994. Am. Assoc. Equine Pract. 40:119-120. - La Flure S. 2003. Natural horse dentistry: What´s the point? Horse and Biting J. 4:15. - Lowder M.Q. 1997. Who is teaching equine dentistry? Comp. Cont. Educ. Pract. Vet. 19:624-627. - Traub-Dargatz J.L., Salman M.D. & Voss J.L. 1991. Medical problems of horses as ranked by equine practitioners. J. Am. Vet. Med. Assoc. 189:1745-1747. – Uhlinger C. 1987. Survey of selected dental abnormalities in 233 horses. Proc. Am. Assoc. Equine Pract. 33:577-583. - Pimentel L.F.R.O. 2004. Distúrbios decorrentes de correções odontológicas inadequadas. In: 6º Congr. Bras. Cirur. Anestesiol. Vet., Indaiatuba, SP. - Mini-Curso Odontologia Eqüina 2004. Editora Faculdade de Jaguariúna (FAJ), p.23-36. - Pimentel L.F.R.O. 2006. Determinação da oclusão funcional ideal em eqüinos. 9º Congr. Bras Cirur. Anestesiol. Vet., Santos, SP. - II Mini-Curso de Odontologia Eqüina 2006. Editora Centro Universitário de Maringá (Cesumar), p.29-36.

INDEX TERMS: Equine dentistry, equine dental desoders, equine dental diseases.

027. Prado A.M.B[1], Bacchi R[2], Macedo T.R[3], Tasqueti U.I.[4] & Werner J.[5] 2007. **Dental agenesis: case report.** *Pesquisa Veterinária Brasileira 27(Supl.).* [1]Anatomia Veterinária Geral e Comparada e Odontologia Veterinária, Pontifícia Universidade Católica do Paraná, E-mail: antonia.prado@pucpr.br; [2]Clínica Médica e Cirúrgica de Animais de Companhia, Pontifícia Universidade Católica do Paraná, Curitiba, PR. E-mail: rebeca_bacchi@hotmail.com; [3]Médica Veterinária Autônoma, E-mail: thamedvet@yahoo.com.br; [4]Estudo Anatômico de Imagem e Diagnóstico por Imagem, E-mail: ubirajara.tasqueti@pucpr.br; 5 Médica Veterinária Autônoma. E-mail: juliana@werner.vet.br

Introduction: The dental anomalies result in shunting lines of the normal process of development and cellular differentiation (Silva et al. 2004), so that many oral riots of development of teeth and structures had been identified in

dogs and cats (Verstraete 1998). The dental riots can have deep genetic or ambient factors, which interfere with the fetal or neonatal development (Verstraete 1998, Silva 2004). In human beings hereditary factors and pathological ambient factors represent each one about 10% of the development anomalies, while the others 80% are of unknown etiology (Verstraete 1998, Silva 2004). One is unaware of if these aspects also apply in veterinary medicine (Verstraete 1998). The teeth are formations of two embryonic leaves, the ectoderm and the mesoderm. The first one will constitute the enamel (Whyte et al. 1999). The formation and the development of the dental agencies respect a definite histological standard, obeying the following stages: initiation, histodifferentiation, morphodifferentiation, apposition, calcification and eruption. Each one of these periods of training is sensible the inductions of modifiers agent, that affect the physiology and the morphology of the fabrics = tissues (Silva et al. 2004). The anomalies of the dental development can in accordance with be classified the number, size, form and structure of the teeth (Whyte et al. 1999). The hypodontia is a numerical anomaly, that expresses the lack of development of one or more teeth, already the anadontia is the complete tooth absence, that can involve deciduous teeth in such a way, how much the permanent one, being a sufficiently rare affection in dogs and cats (Verstraete 1998). The dental agenesis term is used to assign the congenital absence of one or more teeth had the alterations suffered in plates dental during the embryonic life, taking not the formation or incomplete formation of the dental germ (Bastidas 2004, Guerisoli et al. 2002). This is the anomaly form most frequent human being, affecting about 20% of the population (Silva et al. 2004). Alterations in the dental occlusion had the lack of one or more dental units, leading to oclusional disequilibrium, with consequent maxillofacial and functional implications, are the main consequences of the dental agenesis (Loaiza 2001). It enters the causes that can explain the sprouting of this condition, are ambient factors, as traumas and infections, that they take the alterations of them you plate dental during the embryonic phase and genetic mutations, these take the alterations in the cellular production and of proteins that participate of the formation of the dental germ (Bastidas 2004, Guerisoli et al. 2002). In human beings this anomaly is studied still under the anthropological and filogenic point of view (Mozo 1996). The objective of this work is to tell a case of dental agenesis in a dog of the Labrador race.

Case Report: A dog of the Labrador race, female of 4 months of age, was taken care of in the Hospital Unit for Animals of Company of the PUCPR with description of gingival ulceration in right jaw in the region of daily pay-molar teeth with presence of light hemorrhagic episodes with evolution of two weeks. The proprietor related, still, tooth absence in the place of the injury. To the clinical examination any systemic alterations had not been evidenced. To the oral examination increase of gingival volume in right jaw was evidenced, with presence of necrotic points and granulation fabric, had not been observed teeth in the place. In the radiographic evaluation, carried through in the incidences oblique right and left soft fabric increase was observed in the region of daily pay-molar teeth, being that these were absent, had not been observed lytic alterations or proliferations in jaw and the dental alveolus were preserved and in its interior the presence of radiopacity material could be observed. Daily topic cleanness with clorhexydine and administration of spiramycin (75.000UI/Kg/SID) and metronidazole had been prescribed (12.5mg/Kg/SID). One week after was carried through curettage of the tissue inflammatory and the cartilaginous material contained in the interior of the alveoli of 1º, 2º and 3º tooth pay-molar and extraction of 4° tooth pay-molar upper right. The gotten material was sent for histopathological evaluation. The animal remained under antibiotictherapy per more 30 days. After the procedure was carried through new radiographic examination, that evidenced absence of the radiopacity structures in the alveolus, corroborating with the possibility of the animal to present only the dental sprouts of daily pay-molar teeth superior rights, being characterized agenesis dental. The oral injuries treatment involution and the animal meet in good condition. The finding of the histopathological examination disclosed to an inflammatory reaction chronic active with granulation fabric and fibrosis, the fabric observed in the intra-alveolar material was compatible with enamel and dentine, being the compatible finding with the suspicion of dental agenesis.

Discussion: The anomalies of development of plate dental, as the agenesis, are rare in dogs and cats (Verstraete 1998), being little registered. The consequence of this alteration of development is the congenital absence of all the teeth, anadontia, or only of some dental parts, that are the case of the hypodontia or oligodontia (Verstraete 1998, Whyte 1999). The animal of the present story presented a hypodontia picture, where only 1º, 2º and 3º daily pay-molar right superiors were absent. The numerical dental alterations can have as cause the genetic inheritance, a time that if observes this problem in different individuals of one same family, as much in animals, as in human beings (Mozo 1996, Aksenovich 2006). In the told case, this relation cannot be established, a time that the proprietor was unaware of the antecedents of the patient. In a study carried through for Aksenovich et al. (2006), the lack of one or more teeth in a family of Kerry Blue Terrier was observed. The standard of dental absence was presented of two distinct forms in the population, showing that the characteristic is transmitted in different ways depending it gene that controls it. In dogs the affected teeth more are 1º daily pay-molar and 3º molar (Verstraete 1998, Whyte 2006), while in the men the agenesis of the third molar ones is more common (Silva et al. 2004). The diagnosis of dental agenesis if gives through the familiar description and radiographic evaluation (Loaiza 2001), in the present story the oblique incidences make possible a good visualization of the compromised alveoli, but the definitive diagnosis was only obtained through the histopathological evaluation, a time that the material contained in the interior of the alveolus sufficiently was modified disabling the macroscopic identification of dental structures. The treatment of the dental agenesis consists of the correction of the oclusionais alterations (Bastidas 2004), in the present study the curettage if it made necessary due to the great inflammatory reaction generated by the dental sprouts. Later the correction of the bad occlusion will be necessary, in case that the lack of teeth light the severe alterations in the chew and face deformity, a time that the treatment through the use of orthodontic

devices, many times is impracticable in veterinary medicine, being only destined for sufficiently serious cases of bad occlusion. The dental agenesis is an affection of low incidence in veterinary medicine what it makes it difficult the determination of its etiology and the understanding of its hereditary succession, being necessary thus bigger studies in the area.

References: Aksenovich T.I., Kulikova A.V., Kniazev S.P. 2006. Polymorphism of dental formula and segregation of its varients in a pedigree of kerry blue terrier dogs. Genetika. 42(3):414-20. - Bastidas M.A. & Rodríguez A.M. 2004. Agenesia dental em pacientes jóvenes. Revta Estomatología 12(2):34-43. - Guerisoli D.M.Z., Balestrin E.A., Soares M.R., Spano J.C.E., Barbin E.L. & Pécora J.D. 2002. Oligodontia de elementos permanentes: Relato de caso. J.O.F.A. 2(1). Loaiza Y.J. & Cárdenas G. 2001. Prevalência e interpretación radiogáfica de la agenesia dentaria em el área de influencia del servicio de ortopedia dentofacial de la Facultad de Odontologia de la Universidad de Carabobo. Revta Facult. Odontologia Univ. Carabobo 2(2). - Mozo B.C. & Geres M.C. 1996. Agenesia dentaria: estudo familiar. Ver. Cubana Ortod. 11(1). - Silva D.N., Cancini C.M.H., Batista P.S. & Robinson W.M. 2004. Prevalência de hypodontia na faixa etária de 6 a 16 anos: um estudo radiográfico. Revta Ciênc. Méd. Biol. Salvador 3(1):69-75. - Verstraete F.J.M. 1998. Patologia e microbiologia dentária, p.617-618. In: Slatter D. (ed.), Manual de Cirurgia de Pequenos Animais. Saunders Company, São Paulo. - Whyte A., Whyte J. & Sopena J. 1999. Embriologia e desenvolvimento dental: erupção, p.21-26. In: Ascaso F.S.R. (ed.), Atlas de Odontologia de Pequenos Animais**.** Manole, São Paulo.

INDEX TERMS: Dental anomalies, agenesis, dog.

028. Prado A.M.B[1], Bacchi R[2], Tasqueti U.I[3] & Macedo T.R[4] 2007. **Oral canine transmissible veneral tumor: case report.** *Pesquisa Veterinária Brasileira 27(Supl.).* [1]Anatomia Veterinária Geral e Comparada e Odontologia Veterinária, Pontifícia Universidade Católica do Paraná, Curitiba, PR, E-mail: antonia.prado@pucpr.br; [2]Clínica Médica e Cirúrgica de Animais de Companhia, Pontifícia Universidade Católica do Paraná, E-mail: rebeca_bacchi@hotmail.com; [3]Estudo Anatômico de Imagem e Diagnóstico por Imagem, E-mail: ubirajara.tasqueti@pucpr.br; [4]Médica Veterinária Autônoma, E-mail: thamedvet@yahoo.com.br

Introduction: Well known as Sticker Tumour, the Transmissible Venereal Tumour (TVT) is a round-cell neoplasia, of the young dogs genitalia mainly, both sexes and sexualy active, with a tendency to spontaneous returning (Kitchell & Marretta 1998). Rarely it may occur in region as the oral and nasal cavities, rectum, skin e inguinal limph nodes. It's possible to find it less frequently in organs as intestine, spleen, liver, lungs, eyes, kidneys and brain (Oliveira et al. 2004). The presence of the neoplasia in these organs is due to metastasis, wich rarely occur. The transmission is made by transfer of viable cells from the primary tumour, that happens on coitus, licking and on the smelling act, it has been seen most in hight density places, where there are many street dogs, promiscuous and bad feeded (Brandão et al. 2002). The genital TVT incidence is not related to sex or race (Roger et al. 1998). The best choice treatment is chemoterapy using vincristine, as it has been giving cure in the largest cases treated with the drug (Costa 1999). This work objective is to report an oral TVT case without affecting genital region.

Case Report: An animal of the canine specie, female, Rottweiler, with 12 years of age was taken care of in the Unit Hospital for Animals of Company of the PUCPR, with hyporexia description it has two days and increase of gradual volume in right jaw with evolution of two weeks. In the clinical evaluation a tumor in right jaw was proven, leading to the face asymmetry. To the examination of the oral socket an erythematous irregular formation in right jaw with two centimeters of diameter was observed approximately that if extended since the tooth (104) until the third daily pay-molar one (107). In the oblique extra-verbal x-ray it was possible to visualize areas of osteolysis in bone to maxillary right, suggesting neoplastic invasion. It was still observed resorption to root in right superior tooth (104) and in first daily pay-molar right superior (105). The citology had shown many round cells caracteristic from TVT. It was made ampicilina, metronidazol, meloxicam and chemoterapic treatment with vincristine. Actually the animal is very well presenting no one neoplasic injury.

Discussion: According to Rogers (1997), oral TVT rarely occurs when there is no evidence of transmissible venereal tumour, the nasal cavity and the inguinal limph nodes are the places most attacked by TVT localized in no genital region, by the other hand on the case reported, the neoplasia was situated in the oral cavity, wich is most rare. The tumor genital absence may be explained by Varaschin et al (2001) who relates a possible spontaneous returning, that may happens with TVT or, probably, cause it didn't happen the tumor cels establishment in genitalia, but in the oral cavity, during the licking, therefore, this pacient oral TVT could be a primary focus or a metastasis. The chemoterapic drug of chose was efficient for the pacient's healing, to sustain with Oliveira et al. (2004) reporting that the chemoterapy using vincristine is efficient in extra-genital cases of this neoplasia. When TVT presents on genital region, the clinic diagnostic may be concluded, but when it occurs in extra-genital region, it's necessary a cytologic study or histopatologic to confirm (Moutinho et al. 1995). Due to the diversity on presentation form of this neoplasia**,** TVT must be considered as differential diagnoses for masses including oral cavity and elementos dentais (Kroger et al. 1991), mainly in Brazil, that according to Costa (1999) the TVT frequency is very high.

References: Brandão C.V.S., Borges A.G., Ranzani J.J.T., Rahal S.C., Teixeira C.R. & Rocha N.S. 2002. Tumor Venéreo transmissível: estudo retrospectivo de 127 casos (1998-2000). Educ. Contin. CRMV/SP 5(1):25-31. - Kitchell B.E. & Marretta S.M. 1998. Oral tumors in dogs and cats. Part I. Diagnosis and clinical signs. Compedium 20(9):1011-1021. - Kroger D., Grey R.M. & Boyd J.W. 1991. An unusual presentation of canine transmissible venereal tumor. Canine Practice 16(6):17-21. - Moutinho F.Q., Sampaio G.R., Teixeira C.R., Sequeira J.L. & Laufer R. 1995. Tumor venéreo transmissível com metástases cutâneas em um cão. Ciência Rural, Santa Maria, 25(3):469-471. - Costa M.T. 1999. O tumor venéreo transmissível canino. Educ. Contin. CRMV/SP. 2(3):46-52. - Oliveira E.C., Machado M.L.S., Seitz A.L., Mello F.P.S.,

Stedile R., Cardoso D.P. & Oliveira R.T. 2004. Tumor venéreo transmissível extragenital sistêmico em um cão: relato de caso. Medvep 2(8):261-265. - Rogers K.S. 1997. Transmissible venereal tumor. Compedium 19(9):1036-1045. - Rogers K.S., Waler M.A. & Dilon H.B. 1998. Transmissible venereal tumor: a retrospective study of 29 cases. J. Am. Anim. Hosp. Assoc. 34:463-470. - Varaschin M.S., Wouters F., Bernis V.M.O., Soares T.M.P., Tokura V.N. & Dias M.P.L. 2001. Tumor venéreo transmissível canino na região de Alfenas, Minas Gerais; formas de apresentação clínico-patológicas. Clín. Vet. 32:32-38.

INDEX TERMS: Tumor, oral, transmissible, dog.

029. Prado A.M.B.[1], Bacchi R.[2], Tasqueti U.I.[3], Macedo T.R.[4] & Werner J.[5] 2007. **Adenocarcinoma of salivary gland: case report.** *Pesquisa Veterinária Brasileira 27(Supl.).* [1]Anatomia Veterinária Geral e Comparada e Odontologia Veterinária, Pontifícia Universidade Católica do Paraná, Curitiba, PR, E-mail: antonia.prado@pucpr.br; [2]Clínica Médica e Cirúrgica de Animais de Companhia, Pontifícia Universidade Católica do Paraná, E-mail: rebeca_bacchi@hotmail.com; [3]Estudo Anatômico de Imagem e Diagnóstico por Imagem, E-mail: ubirajara.tasqueti@pucpr.br; [4]Médica Veterinária Autônoma, E-mail: thamedvet@yahoo.com.br; [5]Médica Veterinária Autônoma, E-mail: juliana@werner.vet.br

Introduction: Neoplasias of salivary glands in dogs and cats are uncommon, being its majority adenocarcinomas (Koestner & Buerger 1965). Parotid can affect the glands salivary, mandible, sublingual and zygomatic or the accessory glands salivary that they be situated in the oral mucosa, the palate, the buccal wooden floor, the tongue, pharynx, in the larynx and the paranasal sinus, of all they mandible it is more the attack. It does not have racial predilection or sexual and the average age of the patients is of ten years.

The clinical signals are unspecific and generally they include halitosis, dysphasia, exophthalmia unilateral or bilateral and increase of volume in regions related to the localization of the tumor (Withrow 2001). Mucocele, abscesses, infarct of salivary gland, sialodenitis, lymphoma and lymphadenopathy are the main distinguishing diagnostic to be considered (Spangler & Culberton 1991). The definitive diagnosis is carried through the histopathological evaluation, being the useful cytology to define the degree of malignity of the neoplasia (Withrow 2001).

Case Report: The objective of this work is to tell the case of an animal of the canine species, male, Husky Siberian, with six years that apathy description presented, hyporexia, gradual emaciation and increase of volume in the oral socket with evolution of 20 days. To the clinical examination light dehydration was evidenced, tachypnea and enlarged lymphnodes to submandibular bilateral. Additionally, to the oral examination, a firm mass of red coloration was observed involving the right superior tooth (104) and part of the hard palate. The skull x-ray demonstrated increase of volume of soft fabrics in region to maxillary right with areas of calcifications and absence of adjacent osseo destruction. To the thoracic x-ray suggestive images of pulmonary metastasis had been observed. Therapy with metronidazol associated to the amoxicilina with acid clavulônico was instituted and meloxicam. Incisional biopsy incisional of the tumor was become fulfilled, being breaks up it directed for histopathological examination, which diagnoses adenocarcinoma of gland to salivary in ductal standard. The recommended treatment was tumoral resection, but due to pulmonary metastasis presence, the proprietor opted to not the accomplishment of the surgical intervention. The patient evolved for death.

Discussion: The neoplasias of glands salivary constitute heterogeneous group of injuries, whose clinical aspects in its majority they are similar, contrasting with the ample variety of histopathological aspects (Silva et al. 1998). Costa et al. (2006) they affirm that the evolution of these tumors depends mainly on the histological classification, being that the adenocarcinoma is a neoplasia of high degree of high malignity and with being able metastatic. As Alves (2004) e Withrow (2001) metastasis in regional linfonodos and other agencies is common, the lung is the small farm more affected, followed of bones, liver and brain, as observed in the presented case, where the thoracic x-ray demonstrated compatible images with metastasis pulmonary. Cantisano (1998) e Silva (1998), had told that the presence of ulcers, hyperemia, pain, osseo invasion and paralysis in the face nerve signal for the diagnosis of malignant neoplasia, however in the presented case, only volume increase was observed to maxillary and hyperemia of the tumor. The therapy includes resection surgical complete of the tumor with good x-ray and safety margin in the postoperative period, this increases the supervened one of the patient according to Evans & Thrall (1983), however if it does not find available easily for the medical veterinarians. Alves et al. (2004) in study epidemiologist they affirm that the evolutional period of training of the illness, the surgical localization of the tumor, edges and the invaded anatomical area are factors of important value prognostic, however Withrow (2001) says that he is generally shady. Considering the ample variety of biological behaviors and histological types that these tumors present, added low the prevalence of these neoplasias in dogs and cats the boarding of this subject becomes a challenge (Santos et al. 2003, Brown et al. 1997).

References: Alves A.T.N.N., Soares F.D., Silva Jr A., Medeiros N. & Milagres A. 2004. Carcinoma adenóide cístico: revisão da literatura e relato de caso clínico. J. Bras. Patol. Med. Laborat. 40(6). - Brown P.J., Lucke V.M. & Sozmen M. 1997. Lipomatous infiltration of the canine salivary gland. J. Small Anim. Pract. 28:234-236. - Cantisano M.H. 1998. Prevalência, parâmetros clínicos e revisão diagnóstica das neoplasias de glândulas salivares na Faculdade de Odontologia de Araçatuba-Unesp. Tese de Doutorado em Estomatologia. - Costa C.M.M.S., Bonilha F.J.C., Bagnato N.J. & Pimentel P.A.G. 2005. Caso clínico de adenocarcinoma de células acinares em região de parótida. Revta Bras. Patol. Oral 4(3): 66-74 - Evans S.M. & Thrall D.E. 1983. Postoperative orthovoltage radiation therapy of parotid salivary gland adenocarcinoma in three dogs. J. Am. Vet. Med. Assoc. 182:993-994. - Koestner A. & Buerger L. 1965. Primary neoplasms of the

salivary glands in animals compared to similar tumors in man. Vet. Pathol. 2:201-226. - Santos G.C., Martins M.R., Pellacani L.B., Vieira A.C.T., Nascimento L.A. & Abrahão M. 2003. Neoplasias de glândulas salivares: estudo de 119 casos. J. Bras. Patol. Med. Laborat. 39(4). - Silva S.J., Morais D.M., Aguiar A.S.F., Lemos V.C.T., Fabiano P. & Loyola A.M. 1998. Revta Bras. Otorrinolaringol. 64(4):387-394. - Spangler W.L. & Culbertson M.R. 1991. Salivary gland disease in dogs and cats: 245 cases (1985-1988). J. Am. Vet. Med. Assoc. 198:465-469. - Withrow S.J. 2001. Cancer of the salivary glands, p.318-319. In: Withrow S.J. & MacEwen E.G. (ed.), Small Animal Clinical Oncology. 3rd ed. Saunders Company, Philadelphia.

INDEX TERMS: Neoplasias, salivary gland, adenocarcinoma, dog.

030. Radighieri R., Quinzani, M. & Medeiros F.P. 2007. **Craniomandibular osteopathy in a West Highland White Terrier.** *Pesquisa Veterinária Brasileira 27(Supl.).* Petcare Hospital Veterinário, São Paulo, SP, Brazil. E-mail: radighieri07@yahoo.com.br

Introduction: The cranimandibular osteopathy (CMO) is a nonneoplastic condition of periosteal proliferation of the bones of skull (Huchkowsky 2002). All the skull bones can be envolved, but it is most frequently observed in the horizontal ramus of jaw, tympanic bullae, temporomandibular joints and calvarium (Pastor KF, Boulay JP, Schelling SH, et al 2000). Also called lions´s jaw, the CMO has unknown etiology and occurs along the development of subcondral bones and ossification (Johnson & Hulse 2005). This condition usually regresses at 11-13 months of age, but depending of the severity of the lesions at temporomandibular joints, regression may not mean total recovering of the pacient (Wiggs & Lobprise 1997). Either gender can be affected by this condition, and the most frequently breeds affected are West White Highland Terrier, Scotish Terrier, Boston Terrier and other terriers. CMO in Shetland Sheperd, Doberman pinscher, Bull Terrier, Bullmastuf, Boxer and Bulldog was also reported (Huchkowsky 2002; Taylor et al. 1995, Hathcock 1982). Clinically the pacient shows pain in mouth openning, salivation, disconfort, inappetence, inability to open the mouth fully and enlargement of bilateral mandibular rami (Watson et al. 1995). Differential diagnoses include osteomielitis, traumas, neoplasia and systemic disorders. The conclude diagnoses is based on age, breed, historical and phisical finds, radiographic exam and bone biopsy. Serum biochemistry is usually within normal references (Huchkowsky 2002). The treatment of CMO consists in pain and disconfort relief. Non steroids anti-inflamatory agentsque may help disconfort but will not change the disease development. The prognosis is reserved and depends on the affected region, the extension and the pacient abillity of adaptation (Wiggs & Lobprise 1997).

Case Report: The present paper presents a case of a West Highland White Terrier, male, 5 months old, reffered to the Petcare Veterinary Hospital, São paulo, Brazil, wich the owner reported inabillity in mastigation of dry food and inappetence. The physical avaluation presented bilateral enlargement of horizontal mandibular rami, pain and dificults to open the mouth. The pacient was anesthetized (acepromazine and propofol) and radiograph exam of skull was proceeded besides blood counting and serun biochemistry. The radiographs revealed severe periosteal proliferation in mandibular rami and bone proliferation in the tympanic bullae and temporomandibular joints. Other exams were within normal reference range. Treatment involved dipirona (25mg/kg/twice a day) and meloxican (0.1mg/kg/once a day) at most painfull moments. The patient showed good clinical evolution. On 8 months age the patient showed sign of pain or disconfort and the medications were suspended. A new radiography presented greater periosteal proliferation, besides cortical proliferation in frontal and parietal bones. New blood counting and serum biochemistry showed normal references. On 13 months age the patient was pain free and comfortable with no medication. The last radiograph evaluation presented signs of regression of periosteal proliferation. Till now, on 15 months old the patient presents good evolution.

References: Huchkowsky S.L. 2002. Craniomandibular osteopathy in a bullmastiff. Can. Vet. J. 43:883-885. - Watson A.D.J., Adams W.M. & Thomas C.B. 1995. Craniomandibular osteopathy in dogs. Compend. Contin. Educ. Pract. Vet. 17:911-922. - Taylor S.M., Remedios A. & Myers S. 1995. Craniomandibular osteopathy in a Shetland sheepdog. Can. Vet. J. 36:437-439. - Hathcock J.T. 1982. Craniomandibular osteopathy in an English Bulldog. J. Am. Vet. Med. Assoc. 181:389. - Pastor K.F., Boulay J.P., Schelling S.H., et al. 2000. Idiopathic hyperostosis of the calvaria in five young Bullmastiffs. J. Am. Anim. Hosp. Assoc. 36:439-445. - Wiggs R.B. & Lobprise H.B. Veterinary Dentistry: principles and practice. Clin. Oral Pathol. 5:111. - Johnson A.L. & Hulse D.A. 2005. Other diseases of bones and joints. In: Fossum T. (ed.), Small Animal Surgery. 2nd ed. 37:1170.

INDEX TERMS: Craniomandibular osteophaty, dog, periosteal proliferation.

031. Rezende A. P.C., Rocha M.S.T. & Galera P.D. 2007. **Making of intra-radicular nucleus and dental crown with acrylic resins reinforced by ribbond® tape on boxer bitch: case report.** *Pesquisa Vewterinária Brasileira 27(Supl.).* Hospital Veterinário de Pequenos Animais da Universidade de Brasília, FAV-UnB, Brasília, DF 70910-900, Brazil. E-mail: protevet@hotmail.com

Introduction: Traditional root channel treatment is an alternative for teeth whose endodontic system is endangered due to pulpitis or fractures with or without pulp exposure (Gioso 2001, Leon-Roman et al. 2002). Extensive coronary destruction after endodontic treatment usually needs intra-radicular preparation prior to the setting of pins or cast nuclei which will serve as a support base for retention and fixation of coronary prostheses (Gomes et al. 1999, Leon-Roman et al. 2002, Leirião et al. 2003, Wanderley 2003). Both teeth that have undergone endodontical treatment and teeth prepared for nuclei formation may remain in the mouth cavity for varied periods until they are prosthetically restored, being their post-restoration durability long and effective (Gomes et al. 1999, Ribeiro et al. 2000). This report aims to assess the workability

of an intra radicular nucleus and dental crown built on a Boxer bitch, making use of acrylic resins reinforced by heavy-duty interwoven polyethylene fibers.

Materials and Methods: The experiment was made on an adult Boxer bitch that had suffered total fracture of the left lower canine tooth due to biting trauma. The fracture being located in the cervical region of the dental crown, with the presence of intense painless scarring reaction of clinic assessment and record, chronicity of a dental lesion was found.

Results and Discussion: In virtue of a worsening clinic situation, endodontic treatment was carried out. The animal was laid in right lateral decubitus and the region of the fracture was exposed through gengivoctomy. The remaining root was endodontically treated. Twenty days after the treatment, the animal was sent back to surgery to get an intra radicular pin, a nucleus with autopolymerizable acrylic material, methylmethachrylate, chemically activated acrylic resin and a dental crown with photopolymerizable acrylic. Inlay material of the radicular canal was removed up to the depth necessary to the making of the intra radicular pin and removal of angles at the opening of the canal. Soon afterwards, a cut of the Ribbond® was made, longer than the depth of the canal and as high as the nucleus to be restored and acid conditioning of the canal walls with its rinsing and drying. After drying, autopolymerizable acrylic resin was injected into the canal. The Ribbond® tape was applied on it for compression to assure dense concentration. The animal was examined on a weekly basis for one month after 12 months from surgery. The prosthesis had been preserved with proper dental occlusion, to demonstrate the effectiveness of the technique.Among different alternatives to endodontic therapy and the choice for the most proper procedure, the peculiarities of the patient, duration of affection and clinical signs should be taken into consideration (Gomes et al. 1999, Leon-Roman et al. 2002, Ribeiro et al. 2000, Valle et al. 2003). In the above case a disinfectant penetration treatment or conventional canal treatment was used. This procedure is often employed to treat irreversible injury to the endodontic system in case of pulpar necrosis, usually together with endangerment of the periapical part of permanent teeth (Vasconcelos et al. 2001, Leon-Roman et al. 2002).The Ribbond® tape is produced from high molecular weight polyethylene and has as its main features inertia and biocompatibility (Simamoto et al. 2003, Ribbond® THM 2004). The combination of fiber and weave makes this tape ductile, no memory, and very useful in dental treatment on human beings (Gomes et al.1999, Ribbond® THM 2004). The tips of the Ribbond® tape that were left out of the radicular canal on purpose were used with the help of the photopolymerizable acrylic resin for reconstruction of both the nucleus and a small dental crown to make better tape adherence to the resin after fixation in order to avoid its weakening. Aiming to reduce prosthesis fracture and prolong its maintenance a dental crown smaller than the original one was made.

Conclusions: Results from experimental conditions described above have led to the conclusion that the use of endodontic prosthesis through the technique of making intra radicular nuclei and dental crown is effective and feasible in veterinarian dental treatment.

References: Gioso M.A., Vianna R.S., Venturini M.A.F.A., Correa H.L., Venceslau A. & Araújo V.C. 2001. Análise clínica e histológica da utilização da resina acrílica autopolimerizável nas fraturas de mandíbula e maxila e separação da sínfise mentoniana em cães e gatos. Ciência Rural, Santa Maria, 31:291-298. - Gomes A.P.M., Oliveira L.C., Camargo C.H. & Balducci I. 1999. Avaliação da infiltração marginal por corante em obturações de canais radiculares preparados para núcleo, em virtude do material de preenchimento ou impermeabilização do remanescente radicular. Revta Odontol.Unesp 28:147-160. - Leirião F.P., Brito L., Mory L. & Gioso M.A. 2003. Histological study of the periodontal structures, comparing gingival displacement by use of copper band and by cotton string, in dogs. Braz. J. Vet. Res. Anim. Sci. 40:382-388. - Leon-Roman M.A. & Gioso M.A. 2002. Tratamento de canal convencional: opção à extração de dentes afetados endodonticamente: revisão. Clín. Vet. 40:32-44. - Ribeiro R.A., Myaki S.I., Gioso M.A. & Araújo N.S. 2000. Pulpal response of dogs primary teeth to an adhesive system or to a calcium hydroxide cement. Pesq. Odontol. Bras. 14:47-52. - Ribbond® THM 2004. About us Ribbond®? http://www.ribbond.com. Acess in 19.11.2006. - Simamoto Junior P.C., Silva M.R., Mota A.S., Fernandes Neto A.J. & Martinez T.S. 2003. Avaliação da técnica ultra-sônica na remoção de pinos intrarradiculares em canais previamente estandardizados, p.238. In: Resumos dos trabalhos apresentados na XVI Jornada Odontológica de Bauru, SP. - Valle C.V.M., Pinzan A. & Valle-Corotti K.M. 2003. O tratamento ortodôntico e o paciente periodontal: relato de um caso clínico, p.235. In: Resumos dos trabalhos apresentados na XVI Jornada Odontológica de Bauru, São Paulo. - Vasconcelos B.C.E, Filho J.R.L., Fernandes B.C. & Aguiar E.R.B. 2001. Dental Reimplantation. Revta Cirur. Traumatol. Buco-Maxilo-Facial 1:45-51. - Wanderley M.T. 2003. Como tratar dentes traumatizados ou perdidos traumatismo em dentes decíduos e suas repercussões para as dentições, p. 142. In: Anais do 15º Conclave Odontológico Internacional de Campinas, São Paulo.

INDEX TERMS: Odontology, ribbond®, root canal therapy.

032. Rezende A.P.C., Rocha M.S.T. & Galera P.D. 2007. **Direct technic of periodontal contention in mixed breed dog male: case report.** *Pesquisa Veterinária Brasileira 27(Supl.).*Hospital Veterinário de Pequenos Animais, FAV, Universidade de Brasília (UnB), Brasília, DF 70910-900, Brazil. E-mail: protevet@hotmail.com

Introduction: The technique of periodontal contention is the main procedure utilized as a treatment for dental mobility - a consequence for periodontal illness where occurs the loss of sustainability and bone height, being connected or not to an oclusal trauma (Soares et al. 2003). This technique has a temporary meaning when utilized before or during conventional periodontal treatment, thus providing stability and comfort to patients (Wanderley 2003). Nevertheless, the technique may represent definite and lasting functionality when performed at the final faze of the rehabilitating treatment, allowing - besides the already mentioned characthteristics - adequate functionality of mastigatory process. In humans, periodontal contention is made on palatine or lingual tooth face due to patient's esthetical preservation need. In pets it is possible to choose the vestibu

Fig.1. Severe gingival retraction exposing tooth roots and reduction of dental stability.

lar face, once this presents greater areas for surgical access allowing better visualization of the several phase procedures (Soares et al. 2003). The objective of this work was to utilize the direct periodontal contention technique with the cross link-loss lock stitch in dog male mixed breed.

Materials and Methods: The animal was sent to the Surgical Clinic Sector where enhanced on an adult male mixed breed dog, witch presented severe gingival retraction exposing tooth roots and reduction of dental stability as a consequence of advanced periodontal illness on vestibular surface of all superior incisors, left and right (101, 102, 103, 201, 202, 203) associated to gingivitis and severe dental calculus not only on above described teeth but also in all remaining elements of the oral cavity.

Results and Discussion: The animal was sent to the Surgical Clinic Sector where - as a first proceeding - conventional periodontal treatment was performed (Frost et al. 1993, Gioso 1994). After that, periodontal contention was initialized with reinforcement enhanced bondability polietilen interlaced fibers (Ribbond®) and adopting dental stabilization direct technique, since this exiges shorter surgical time and allows the proceedings to be made in a sole surgical operation. Ribbond® string is made of polietilen fiber of very high molecular weight. The ribbon is biocompatible, inert, colorless and translucent. The combination of fiber and weft turns ribbon malleable and virtually with no shape memory (Soares et al. 2003). The ribbon has several odontological uses and it is utilized with success on human odontology (Soares 2003).

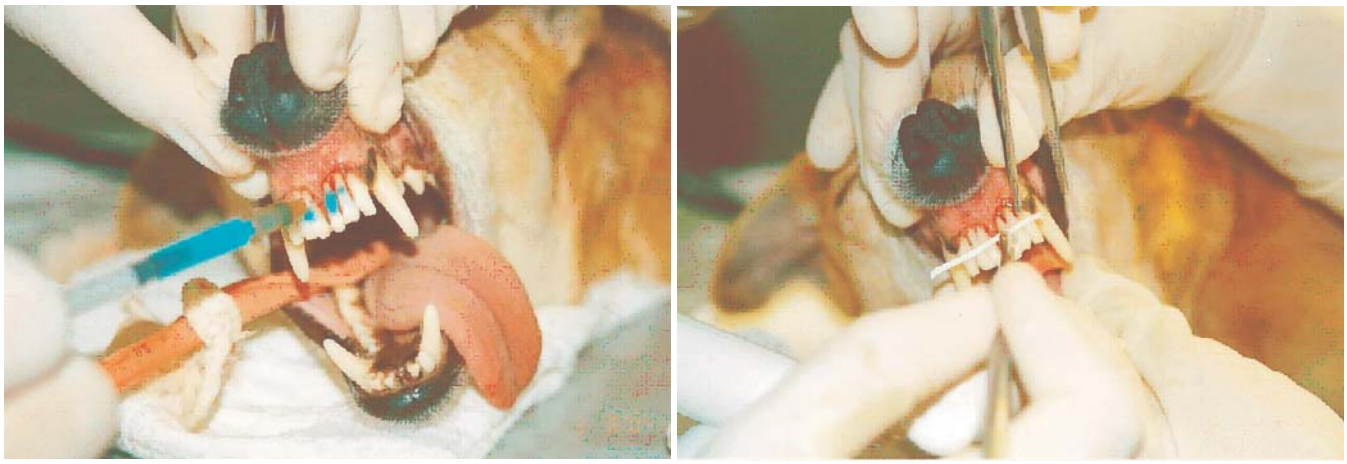

Fig.2 and 3. Incisors regions conditioned on phosphoric sour and periodontal contention initialized with reinforcement Ribbond®.

Fig.4 and Fig.5. A fine layer of photopolimerible resin was deposited and, on top of this, Ribbond®.

Initially, at incisors region, teeth were conditioned on phosphoric sour during 30 seconds, washed with filtrated water and dried (commonly utilized acid attack on odontological praxis). Further, a fine layer of photopolimerible resin was deposited and, on top of this, Ribbond® tape was adapted after being cut in adequate size in order to allow contention of the six affected teeth on a single stabilization block (Vasconcelos et al. 2001, Wanderley 2003). Later, a new layer of resin was applied on top of Ribbond® for modeling and photopolimerization of composed solution. This last layer provided better local finishing and enhanced thickness of stabilization material (Leirião et al. 2003).

It is remarkable that Ribbond® was infused on the same resin adopted during all surgical procedure before being adapted to contention site in order to avoid contamination by other substances that could have altered its functionality. The animal was reanalyzed during weekly post-surgical procedures.

Conclusions: After 14 months observation of periodontal contention stability efficacy of applied technique was confirmed.

References: Frost P. 1985. Canine Dentistry. Edit Hardcover, New York, p.26-31. - Gioso M.A.1994. Odontologia Veterinária para o Clínico de Pequenos Animais. 3ª ed. FMVZ-USP, São Paulo, p.3-10. - Soares P.V., Pfeifer J.M.G.A., Soares C.J. & Quagliatto P.S. 2003. Associação de fechamento de diastema e contenção periodontal com fibra na recuperação estética do sorriso. Resumos dos trabalhos apresentados na jornada odontológica de Bauru, Faculdade de Odontologia, Universidade Federal Uberlândia, Minas Gerais, p.91. - Vasconcelos B.C.E., Laureano Filho J.R.L., Fernandes B.C. & Aguiar E.R.B. 2001. In: Dental reimplantation. Revta Cirurg. Traumat. Buco-Maxilo-Facial 1(2):45-51. - Leirião F.P., Brito L., Mory M. & Gioso M.A. 2003. Histological study of the periodontal structures, comparing gingival displacement by use of copper band and by cotton string, in dogs. Braz. J. Vet. Res. Anim. Sci. 40:382-388. - Wanderley M.T. 2003. Como tratar dentes traumatizados ou perdidos traumatismo em dentes decíduos e suas repercussões para as dentições. Anais 15º Conclave Odontol. Int., Campinas, São Paulo, p. 01-09. - Gioso M.A., Vianna R.S., Venturini M.A.F.A., Correa H.L., Venceslau H.L. & Araújo V.C. 2001. Cinical and histological evaluation of acrylic resin in the fracture of the mandible and maxilla and separation of mandibular symphysis in dogs and cats. Ciência Rural, Santa Maria, 31(2):291-298.

INDEX TERMS: Dental stability, periodontal contention, ribbond®.

033. Rossi Jr J.L.[1], Guião-Leite F.L.[2], Gioso M.A.[1] 2007. **Oral myiasis in hippopotamus kept in captivity: case report.** *Pesquisa Veterinária Brasileira 27(Supl.).* [1]Departamento de Cirurgia, Faculdade de Medicina Veterinária e Zootecnia, Universidade de São Paulo, São Paulo; [2]Faculdade de Medicina Veterinária, Centro Universitário Vila Velha, Espírito Santo, Brazil. E-mail: vetjrossi@gmail.com

Introduction: The illnesses of the mouth in wild beasts are not usually well understood or registered by professionals who work with such species (Kazimiroff 1938, Robinson 1979). The infections of the mouth can be directly related primary to the dental diseases as: deficient dental eruption, imperfect occlusion, wearing or abrasion, fractures with or without exposition of the dental pulp and periodontal disease. The hippopotamus (*Hippopotamus amphibius*) belongs to the Artiodactila order, suborder not-ruminant, Hippopotamide family. They are found in the African continent, southern to the Sahara. They possess amphibious habits and live most of the time inside of the water, emerging during the night to graze in the edges of rivers and lakes (Klingel et al. 1993). This behavior also is observed in the animals in captivity and all condition must be kept so that the homeostasis can be maintained. They approximately have 540 cm of body length, 165 cm of height and 3200 kg of weight. The life expectancy in nature is of approximately 40 years and in captivity they can be over 50 years (Klingel et al. 1993). The diet is composed of grass and some other plants. In captivity these animals still receive commercial food for horses, fruits (papaya, banana, watermelon), vegetables (cauliflower, cabbage), vegetables (beetroot, carrot, string bean) and hay. They are found in the biggest zoos, due the adaptation of easiness to captivity, evidenced by the reproductive success and hardly get sick. The dental formula, according to Kertesz (1993), Wiggs & Lobprise (1997) and Amand & Tinkelman (1985), follows the following division: 2/2: 1/1: 4/4: 3/3 = 40, or either, for each dental hemiarch, upper/lower, possess 2 incisior teeth, 1 canine tooth, 4 pre-molars and 3 molars. The lower incisor teeth are strong, long and they are separate by diastemas. The upper incisors are much weaker, with constant growth, following the classification according to Kertesz (1993), as Elodonts. Both canine teeth (upper and lower) are large teeth, can have more than 50 cm of length, coated with a fine enamel layer. These teeth can suffer discoloration (black) according to aging. Due to the constant growth, with the natural wearing and the contact with the antagonist teeth, when the teeth are in normal occlusion, enamel cusps become sharpened, representing important tools for the adult males during combats for defense of their territory or the simple intimidation caused by the exposure of teeth when threatened (male and female). In the past, the teeth of animals hunted in Africa were bleached by acid treatment and from them, human dental prosthesis were done, additionally these teeth were attractive for collectors of trophies, who decimated whole populations of this megavertebrates in some regions of the continent (Klingel et al. 1993). The pre-molar teeth possess large and single cuspids. The molar teeth possess four high cuspids, so that each pair of cuspids meets each other in the infundibulum. Reports of myiasis in these megavertebrates kept in captivity are scarce, perhaps in function of the difficulty of handling of such species, which depends highly on the animal behavior conditioning to allow approach and manipulation during specialized physical examination, without the necessity of chemical constraint.

Materials and Methods: An oral case of myiasis in hippopotamus is reported in a male adult, estimated age of 8 years, weighing 2.500 kg, kept in captivity. The injury was in the region of gingival and alveolar mucosa of the left lower canine. The animal when entering in reproductive period disputed a female with another male and suffered some skin injuries and probably a wound in the mouth, which served as substratum for fly egg deposition. When separating this reported from its animal group, it could be observed

the injury filled with larvae, which concentrated abundantly in the oral mucosa close to the lower canine. With minimum behavioral conditioning taken by the handler, the constraint of the animal was taken in an improvised cage, allowing a brief examination of the oral injury. It was opted for a surgical debridement of necrotic tissues and removal by means of forceps of the larvae (approx. 50), under continuous water flow, that was in part ingested for the animal, that remained calm with this procedure. The remaining live larvae were removed manually using ether directly under the lesioned area and later the wound was flushed with water in abundance. The wound was washed daily with approximately 60 ml of clorexidine 0.12% (Periogard®). As measure of support therapy and preventing sistemic complications, Pentabiótico Reforçado® was used (Fort Dodge), in dose 12.000 UI/kg during 10 days, every 48 hours, injected in the lateral region to the anus, being this the only point in the animal where the thickness of the skin allows the entrance of a hypodermic needle, without the necessity of use of remote projectors of darts.

Results: The great volumes of medication applied in this point caused an abscess in the place (after the third application). It was opted then to make the application of the medicine through the mouth, throwing the antibiotic diluted deep into the mouth of the animal. Nine days after these procedures it was observed formation of granulation tissue around the oral lesion. During the period of treatment the animal was confined in a restricted caring space in order to tusk the surface of the body with use of water hose. It was not necessary to modify the diet of the animal.

Discussion and Conclusion: The animal did not show difficulty in the food apprehension. After the total recovery (20 days), the animal was released from the enclosure, however it was taken the care of separating it from fights for the dispute for the female. After two years after treatment, the animal was normal, without injuries in the place of the oral lesion.

References: Klingel H., Lang E.M., Hentschel K., Bülow W. 1990. Family Hippotamuses, p.58-79. In: Grzimek´s Encyclopedia of Mammals. Vol.5. MacGraw-Hill, London. - Robinson P.T. 1979. A literature review of dental pathology and aging by dental means in non-domestic animals. Zoo Anim Med. 10:57-65 (Pt.1) and 81-91 (Pt.2). – Kertesz P. 1993. A Colour Atlas of Veterinary Dentistry and Oral Surgery. Wolfe Publ., Aylesbury, p.39, 50. - Amand W.B. & Tinkelman C.L. 1985. Oral Disease in Captive Wild Animals, p.291. In: Harvey, C.E. (ed.), Veterinary Dentistry. W.B. Saunders, Philadelphia. - Wiggs R.B. & Lobprise H.B. 1997. Exotic Animal Oral Disease and Dentistry, p.543. In: Idem (ed.), Veterinary Dentistry: principles and practice Lippincott-Raven, New York.

INDEX TERMS: Gingival, tusk, myiasis, hippopotamus, captivity.

034. Roza M.R.[1], Januário A.L.[2] & Silva L.A.F.[3] 2007. **Individual dental implant placement in dogs: a proposal for a single stage surgery.** *Pesquisa Veterinária Brasileira 27(Supl.).* [1]Médico Veterinário, Doutorando em Ciências Médicas, UFG, Goiânia, GO; [2]Departamento de Periodontia da UCB; [3]Departamento de Medicina Veterinária, UFG. E-mail: marcelloroza@gmail.com

Introduction: With the development of veterinary dentistry, implantodontics and prosthesis became, esthetic and functional oral rehabilitation tools; justifying the need for a standardized protocol for the choice and placement of those implants, taking into consideration functional, anatomical and biological differences between dogs and humans, for witch the different implant systems are developed. For choosing an implant system, factors such as site of implant, adjacent anatomy, the need for grafts, bone quality and the design of the implant component, should be considered (Lee et al. 2005). The purpose of this article is to establish a dental implant protocol for dogs, on a single stage surgery, based on the authors' experience.

Materials and Methods: The established protocol starts with gingival incision of the bone height, and soft tissue clearance. The drilling sequence is done, always with abundant water, and at max speed of 1500rpm (Lekholm 2005), with spherical bur, and proceeding with the sequential burs, 2mm cylindrical bur, that determines the height and width of the implant, pilot bur, that makes the transition from 2 to 3mm, and 3mm cylindrical bur always with caution regarding deepness reference of the burs in relation to the top of the bone height. Having determined the height and width of the drill the counter sink bur is used, that gives it the format of the top of the implant, followed by the making of the screw (for type 1 bone) and the placement of the implant, connected to the reduction contra angle, at the speed of 15-20rpm, with maximum initial stability. The implant should be locked with a force of 20-25 Newtons (N) for procedures where osseous integration is expected, and 45 N for implants submitted to immediate load (Lorenzoni et al. 2003).

Results: The animals operated with this technique are all without intercurrences.

Discussion and Conclusion: The techniques used to install dental implants in humans can used in dogs, with some modifications. The choice of adequate implant is fundamental in the success of the procedure. The technique described is safe to execute with the proper instruments and equipment and has shown to be effective in implants submitted to immediate load in dogs, therefore being eligible for routine dentistry in dogs.

References: Lee J.H., Frias V., Lee K.W. & Wright R.F. 2005. Effect of implant size and shape on implant success rates: a literature review. J. Prosthet. Dent. 94(4):377-381. - Lekholm U. 2005. O sítio cirúrgico, p.830-842. In: Tratado de Periodontia Clínica e Implantodontia Oral. Guanabara Koogan, São Paulo. - Lorenzoni, M., Perti C., Zhang K. & Wegscheider W.A. 2003. Immediate loading of maxillary single-tooth implants: preliminary result after 1 year. Clin. Oral Impl. Res. 14:180-187.

INDEX TERMS: Dental implant, immediate loading, single stage surgery.

035. Saldanha S.V., Melo L.E.H., Vaz A.P.L. & Souza M. 2007. **Alternative treatment in newborn canine with congenital cleft in the hard palate: case report.** *Pesquisa Veterinária Brasileira 27(Supl.).* Departamento de Medicina Veterinária, UFRPE, Recife, PE 52171-900, Brazil. E-mail: silvia_saldanha@yahoo.com.br

Introduction: An important field of study has been initiated to identify the etiology of the cleft palate, which are relatively rare in dogs and cats, and generally are associated to other malformations (Smith 2004). The oral facial

deformations are characterized by the interruption of the tissue continuity in the upper lips, upper alveolar borders and palates in a partial or total form in each of these structures (Wiggs & Lobprise 1997a). The possible cause of these congenital palates opening in dogs are: inherited factors, nutritious deficiencies, excess of vitamins A and D, medicine ingestions, corticosteroids, teratogenic plants, mechanical interference within the embryo, teratogenic plants, medicine ingestion, hormonal factors, emotional stress factors and *Toxoplasma gondii* agent. Its diagnosis is done by a simple clinical examination. The main clinical signals are: difficulty of suction, cough, oral nasal regurgitation, serous or mucus-purulent nasal discharge, choke, sneezes, pneumonia due to aspiration, tonsillitis, rhinitis and insufficient gain of weight, which can conducted to its death (Warzee et al. 2001, Gioso 2003, Hette & Rahal 2004). A reconstructive surgery of the hard palate is postdated for more advanced ages, being recommended the use of palate plate to obstruct the corresponding area of the hard palate, thus making possible a better development of the animal (Robertson 1993, Hedlund 2002, Roza 2004). It was intended in this study to develop a similar technique used in human, to be applied in veterinary dentistry, aiming to test such treatment in palate cleft cases in newborn dogs. The present work has the objective to relate an alternative treatment proposal for newborn canine with congenital cleft in the hard palate.

Materials and Methods: In a particular clinic a newborn Cocker Spaniel of consanguineous parents was attended presenting an absence of the auricular pavilions, and symptom of corporal respiratory and hypothermic depression. Its received cardiac massage (the puppy arrived with cardiac arrest), aspiration of nasal secretion, ventilation with AMBU (mask) and after that it was laid in a thermal mattress, showing the puppy a positive reaction to the treatment, being later placed to suck. During breast-feeding it was observed difficulty of suction, oral nasal regurgitation and choke with aggravation of the clinical signal leading to death, six hours after the emergency attendance. When examining the oral cavity it was observed the presence of a cleft in the hard palate. After the death of the newborn it was choose to build a palate plate to obstruct the palate cleft, as a proposal of an alternative treatment for patients with fissures, to make breast-feeding possible, and enable a better development of the animal, because the reconstructive surgery of the hard palate must be postdated for more advanced ages.

Results: An intra oral radiography was done for visualization the extension of palate cleft. To obtain the palate plate it was followed this sequence (Hirayama 1996):1. Construction of individual molding: taking as reference the impression of the palate of the patient in paper filter, using a wax plate number seven to obtain an individual molding; 2. Construction of the mold: the molding material (alginate) was placed in the individual molding and was placed in the patient mouth, with a light pressure till complete solidification of the material, when it was removed from the patient mouth; 3. Construction of the work model: after obtaining the mold, it was filled with gypsum to get the work model; 4. Construction of the palate plate: from the work model, previously covered with cel-lac liquid resin and dry with air jets, it was proceeded the construction of the plate with acrylic resin. Completed the polymerization, the palate plate received a finishing and a polishing; 5. Test of the palate plate: after finished and polished the palate plate, was tested, being observed a good adaptation and a perfect obstruction of the palate cleft what would enable a breast-feeding. It is suggested that the palate plate could be placed before each breast-feeding; being removed afterwards. From the moment it is observed an inability of the palate plate as a result of the animal development the plate must be substituted by new palate plate, until the patient offers conditions for submitting to the reconstructive surgical procedure.

Discussion and Conclusions: The historical description for crossing of consanguineous parents suggests that the hereditary factors can be involved in the pathogenesis of associated oral facial malformations in agreement to Jones et al.(2000); Wiggs and Lobprise (1997b) and Robertson (1993). They corroborate with other authors in the sense of not using animals with oral facial malformations for reproductive means. The characteristic clinical signs of patients with defective palate can be identified as soon as it was observed in the Cocker Spaniel puppy first feed by either, difficulty of suction, oral nasal regurgitation and choke revalidating the affirmations of (Griffiths & Sullivan 2001). The initial alternative use of the palate plate, until the patient can be submitted to a reconstructive surgery, favors a better disposition for the correction of tissue manipulation, and also it diminishes the surgical risks accordingly to Gioso (2003) and Hedlund (2002). The palate plate is a promising temporary alternative treatment for newborn canine up to them has a full condition to face reconstructive surgery.

References: Gioso M.A. 2003. Defeitos do palato, p.167-175. In: Gioso M.A. (ed.), Odontologia para Clínicos de Pequenos Animais. 5ª ed. Ieditora, São Paulo. - Griffiths L.G. & Sullivan M. 2001. Bilateral overlapping mucosal single-pedicle flaps for correction of soft palates defects. J. Am. Anim. Hosp. Assoc., Chicago, 32(2):183-186. - Hedlund C.S. 2002. Surgery of the oral cavity and oropharynx, p.274-307. In: Fossum T.W. (ed.), Small Animal Surgery. Mosby, St Louis. - Hette K. & Rahal S.C. 2004. Defeitos congênitos do palato em cães. Revisão de literatura e relato de três casos. Clínica Veterinária, São Paulo, 9(50):30-40. - Hirayama J. 1996. Moldagem e modelos de estudo, p.143-150. In: Ferreira F.V. (ed.), Ortodontia: diagnóstico e planejamento. Artes Médicas, São Paulo. - Jones T.C., Hunt R.D. & King N.W. 2000. Sistema digestivo, p.1063-1130. In: Jones T.C.; Hunt R.D. & King N.W. (ed.), Patologia Veterinária. 6ª ed. Manole, São Paulo. - Robertson J.J. 1993. The palate, p.191-194. In: Bojrab M.J. & Bloomberg M.S. (ed.), Disease Mechanisms in Small Animal Surgery. 2nd ed. Lea and Febiger, Philadelphia. - Roza M.R. 2004. Cirurgia dentária e da cavidade oral, p.167-190. In: Roza M.R. (erd.), Odontologia em Pequenos Animais. L.F. Livros de Veterinária, Rio de Janeiro. - Smith M.M. 2004. Distúrbios da cavidade oral e das glândulas salivares, p.1176-1184. In: Ettinger S.J. & Feldman E.C. (ed.), Tratado de Medicina Interna Veterinária. 5ª ed. Guanabara Koogan, Rio de Janeiro. - Warzee C.C., Bellah J.R. & Richards D. 2001.Congenital unilateral cleft of the soft palate in six dogs. J. Small Anim. Pract., Oxford, 42:338-440. - Wiggs R.B. & Lobprise H.B. 1997a. Oral anatomy and physiology, p.58-62. In: Wiggs R.B. & Lobprise H.B. (ed.), Veterinary Dentistry: principles & practice. Lippincott, Philadelphia. - Wiggs R. B. & Lobprise H. B. 1997b. Pedodontics, p.175-176. In: Wiggs R.B. & Lobprise H.B. (ed.), Veterinary Dentistry: principles & practice. Lippincott, Philadelphia.

INDEX TERMS: Palatine cleft, oral facial malformation, dogs.

036. Saldanha S.V., Melo L.E.H., Vaz A.P.L. & Souza M. 2007. **Incidence of bucco-dental alterations in goats.** *Pesquisa Veterinária Brasileira 27(Supl.).* Departamento de Medicina Veterinária, UFRPE, Recife, PE 52171-900, Brazil. E-mail: silvia_saldanha@yahoo.com.br

Introduction: Only recently studies in dental veterinary has been gaining a certain importance in Brazil and important procedures were made in the areas of periodontia, endodontia, ortodontia, restorations, prosthesis, oral surgery and odontological radiographies in small animals, equines and occasionally in wild animals being the studies in small ruminants in an early stage of development in the Northeastern Region. There are very few works in multiple dental abnormalities in small ruminants. In early studies in relation to clinic epidemiological aspects of bucco-dental alterations in goats raised in different regions of Pernambuco State, it was demonstrated that the dental wear was the most important odontological alteration occurring (Saldanha et al. 2005, Saldanha 2006). Based in the fundamental knowledge of the medical clinic of ruminants, and in the search to introduce an epidemiological clinic vision in an animal environment, for the welfare of the individual in connection with its reproductive function and consequently preservation of original healthy of the entire herd, this study was made with the objective to establish the incidence of buco dental alterations in goats in Pernambuco State.

Materials and Methods: For this study 211 female goats were selected from five herds located in the Recife Metropolitan Region, Pernambuco Forest Region and Pernambuco Sertão Region. The animals had a nutritional state that vary from regular to bad and were under a semi extensive general management, being located in the field during day light and maintained indoor at night. In accordance with the location and management submitted the 211 female goats were distributed as following: Recife Metropolitan Region (R1): integrated by 79 female goats being mainly from the Saanen, Toggenburg and Alpine races and were fed with native pasture (algarroba, native grass, white malva) and cultivated pasture (Brachiaria , Cameron, Buffalo grass) in the bay in the morning before going to the field and received a supplementation of 2kg/animal/day in the evening of manioc peel with barley mixed in a forage machine, together with a mixture of cotton meal, algarroba with corn meal, biscuit, corn flour and nuts, besides elephant grass and mineral salt. Water was freely given in the field by utilizing ponds and tanks while indoor, well water was available. Pernambuco Forest Region (R2): integrated by 21 female Saanen goats fed with native pasture (composed by guava, cashew and banana leaves and cashew, caja, macaiba and mango fruits). They received in the evening in the bay after coming from the field, a supply (1kg/animal/day) of barley, manioc peel and mineral. Water was supplied in tanks in the field and with water well indoor. Pernambuco Sertao Region (R3, R4, R5) integrated by 111 female goats from SRD, Moxotó and Saanen races being fed with native vegetation (caatinga vegetation) and mineral supplementation. Water was supllied by pond in the rain season and by tanks with water well, spread in the field in the dry season. The intra-oral examination was made by using an adjustable mouth opener (specially designed for goats) and head focus light to better visualize the backside teeth. The exam was made tooth by tooth inspecting in a tactile and visually manner to detect an alteration or discomfort by pressing. It was utilized lateral movement to evaluate the degree of dental mobility (Baker & Easley 1999). The odontoclinical data was noted in specific developed sheet (odontogram).

Results: The female goats from the different regions presented a high frequency of oral dental disturb such as: wear of dental crown (99.5%, 210/211) periodontal disease (9.5%, 20/211), dental losses (6.2%, 13/211), abscesses (6.2%, 13/211) and dental extrusion (8.5%, 18/211).

Discussion and Conclusions: Among buco dental abnormalities identified the most frequent were dental wear (99.5%, 210/211) and periodontal disease (9.5%, 20/211) independent from the region studied. The elevated frequency of dental wear in the animals studied was already expected and is in agreement with several researchers (Cutress & Ludwig 1969, Richardson et al. 1979, Bruère et al. 1979). These clinical odontological find are important because the excessive dental wear observed in some female goats may predispose them to a low productive performance because this wear compromise the apprehension and mastication of solid food as well as the ingestion of water (Andrews 1981, Spence & Aitchison 1986, Baber & Waterhouse 1988). The genesis of dental wear is related to many factors such as teeth grind against food, dental hypomineralization or hypoplasia of dental smalt (Pugh 2004), the type of food and how it is ingested with sand (Andriguetto et al. 1984, Pugh 2004) and dental occlusion (Dukes 1986, Greene 2001).Probably the mainly factor that has influenced these finds, in accordance with Andriguetto et al. (1984) and Pugh (2004), was the nutritional management which in Recife Metropolitan Region and in Pernambuco Forest Region include good pasture formation and food supplementation with concentrated differently from the Sertao Region where the animals were feed only by native pasture of great hardiness. The periodontal disease (9.5%, 20/211) that predominated over dental loss (6.2%, 6/211), abscess (6.2%, 6/211), and dental extrusion (8.5%, 18/211), was greater in Recife Metropolitan Region (13.9%) in comparison to Sertao Region (8.1%) and mainly to Pernambuco Forest Region. There are a close correlation between periodontal disease, dental loss and dental extrusion mentioned in the literature, due mainly to the commitment of the periodonto that promotes the abnormal mobility that precedes dental loss (Shanks & Donald 1955, Benzie & Cresswel 1962, Cutress & Ludwig 1969, Nisbet et al. 1970, Lascala & Moussalli 1999). In this study it is to point out that the majority of the animals examined had a regular or bad nutritional stage what can interfere in the animal immunity state, conferring a predisposition to infectious disease including periodontopathies as stated by Cutress & Ludwig (1969). Among the female goats examined in this study it was detected 6.2% of oral abscesses in the buccal vestibule in the mandible anterior region. These suppurative lesions may be related to important clinic epidemiological diseases such as Goat Caseous Lymphadenitis and Goat Tuberculosis (Melo et al. 2005). The high frequency of buco-dental abnormalities in the female goats examined mainly the dental wear may suggest that the nutritional management plays a relevant role in the

oral health of goats. The clinical odotonlogical knowledge is very strategic for the implementation of an adequate nutritional management because the productive performance being multifunctional depends also on the goat oral healthy.

References: Andrews A.H. 1981. Clinical signs and treatment of aged sheep with loose mandibular or maxillary cheek teeth. Vet. Rec. 108:331-333. - Andriguetto J.M., Gemael A., Souza G.A., Minardi I., Flemming J.S., Perly L., Flemming R. & Vinne J.U. van der 1984. Normas e Padrões de Nutrição e Alimentação Animal. Nutrição Editora e Publicitária, Curitiba. 140p. - Baker J.G. & Easley J. 1999. Equine Dentistry. W.B. Saunders, Philadelphia. 277p. - Barber D.M.L. & Waterhouse A. 1988. An evaluation of cutting of incisor teeth of ewes in an attempt to control premature tooth loss. Vet. Rec. 123:598-599. - Benzie D. & Cresswell E. 1962. Studies of the dentition of sheep. II. Radiographic illustrations of stages in the development and shedding of the permanent dentition of the Scottish Black-Face sheep. Res. Vet. Sci. 3:231-235. - Bruère A.N., West D.M., Orr B.M. & O'callaghan M.W. 1979. A syndrome of dental abnormalities of sheep. I. Clinical aspects on a commercial sheep farm in the Wairarapa. N. Z. Vet. J. 27:152-158. - Cutress T.W. & Ludwig T.G. 1969. Periodontal Disease in Sheep. 1. Review of the literarure. J. Periodontol. 40:529-534. - Dukes H. . 1996. Fisiologia dos Animais Domésticos. 11th ed. Guanabara Koogan, Rio de Janeiro. 856p. - Greene S.K. 2001. Equine dental advances. Vet. Clin. North Am. Equine Pract. 17(2):319-333. - Lascala N.T. & Moussalli N.H. 1999. Compêndio Terapêutico Periodontal. 3ª.ed. Artes Médicas, São Paulo. 539p. - Melo L. E.H., Melo M.T., Almeida A.V., Saldanha S.V., Evêncio-Neto J., Tenório T.G.S., Wanderley E.K., Nascimento E.T.S., Fernades A.C. C., Sá L.M., Barbosa D.F.A. & Souto R.J.C. 2005. Ocorrência da tuberculose caprina no Estado de Pernambuco. 1º Congr. Nac. Saúde Públ. Vet., Guarapari, ES. (Resumo 012) - Nisbet D.I., Butler E.J., Robertson J.M. & Bannatyne C.C. 1970. Osteodystrophic diseases of sheep. IV. Osteomalacia and osteoporosis in lactating ewes on West Scotland hill farms. J. Comp. Pathol. 80:535-542. - Pugh D. . 2004. Clínica de ovinos e caprinos. Roca, São Paulo. 513p. - Richardson C., Richards M., Terlecki S., Miller W.M. 1979. Jaws and culled ewes. J. Agric. Sci. 93:521-529. - Saldanha S.V., Evêncio-Neto J., Melo L.E.H., Melo M.T., Tenório T.G.S. & Fernandes A.C.C. 2005. Caracterização das alterações buco-dentais de caprinos criados no Sertão e Zona da Mata do Estado de Pernambuco. In: 18ª Reunião Anual do Instituto Biológico, São Paulo. (Resumo 027) Arqs Inst. Biológico, São Paulo, 72(2):32. - Saldanha S.V. 2006. Aspectos clínico-epidemiológicos das alterações buco-dentais em caprinos criados nas mesorregiões Metropolitana de Recife, Mata Pernambucana e Sertão Pernambucano. Dissertação de Mestrado em Ciência Veterinária, Universidade Federal Rural de Pernambuco, Recife. 63p. - Spence J. & Aitchison G. 1986. Clinical aspects of dental disease in sheep. Practice, London, 8:128-135. - Shanks P.L. & Donald L.G. 1955. An unsusual mouth condition in sheep. Vet. Rec. 67:312-313.

INDEX TERMS: Dental abnormalities, goat, Pernambuco.

037. Senhorinho G.N.A.[1], Nishiyama S.A.B.[1], Gioso M.A.[2] & Avila-Campos M.J.[1] 2007. **Identification of human periodontal pathogens in dogs with periodontitis by using a PCR method**. *Pesquisa Veterinária Brasileira 27(Supl.).* [1]Laboratório de Anaeróbios, Departamento de Microbiologia, Instituto de Ciências Biomédicas; [2]Faculdade de Medicina Veterinária e Zootecnia, USP, São Paulo, SP 05508-900, Brazil. E-mail: gneyla@usp.br

Introduction: The periodontal disease is an inflammatory condition of the periodontal tissues and it is often observed in small domestic animals, such as dogs (Hennet & Harvey 1991, Allaker et al. 1997). These processes are caused by accumulation of the subgingival biofilm and the severity is mediated by the presence of specific microorganisms and the host immunity status (Genco 1998). Polymerase chain reaction (PCR) has been used in the direct identification of periodontal pathogens from subgingival specimens and also to elucidate the role of specific bacteria in the periodontal disease because of the ability to accurately detect species in mixed populations (Ashimoto et al. 1996, Avila-Campos et al. 1999). The goal of this study was to detect the presence of *Porphyromonas gingivalis*, *Prevotella intermedia, Tannerella forsythensis, Fusobacterium nucleatum*, *Dialister pneumosintes*, *Actinobacillus actinomycetemcomitans*, *Campylobacter rectus*, *Eikenella corrodens* and *Treponema denticola* by using a PCR assay.

Material and Methods: Twenty-five dogs with periodontitis and 15 healthy dogs were selected and subgingival samples were collected and DNA was obtained. Animals from different breeds were used. The DNA amplifications were performed by using 16S rRNA specific primers for bacterial detection.

Results: Dogs with periodontitis harbored *P. gingivalis* (64%), *C. rectus* (36%), *A. actinomycetemcomitans* (24%), *P. intermedia* and *T. forsythensis* (20%), *F. nucleatum* (16%) and *E. corrodens* (12%). Moreover, only a dog German Shepherd with periodontitis did not harbor any organism. In addition, of the two Crossbred dogs without periodontitis, one (6.66%) harbored *P. gingivalis.* The other 13 healthy dogs: 1 Poodle, 2 Yorkshire, 2 Lhasa Apso, 1 Golden, 2 Maltese, 2 Rottweiller, 1 West Highland and 2 Dachshund did not harbor any periodontopathogen. Interestingly, none of the periodontal or healthy dogs harbored *T. denticola* or *D. pneumosintes.*

Discussion and Conclusions: Periodontal bacteria such as *E. corrodens, A. actinomycetemcomitans, P. gingivalis, P. intermedia* and *F. nucleatum* are recognized as important opportunistic pathogens in the development of periodontal and non-oral diseases of humans and dogs (Harvey et al. 1995, Genco 1998). In our study, we detected putative periodontal organisms from dogs with naturally occurring periodontitis. *P. gingivalis* was detected in 64 % of the evaluated periodontal dogs in accordance with Allaker et al. (1997) who identified this organism in 68% of the dogs. In conclusion, our results show the need to determine the role of these putative periodontal organisms in the periodontal disease in household pets, particularly dogs in ecologic and therapeutic terms, since these animals can acquire these periodontopahogens from their respective owners.

References: Allaker R.P., Langlois T. & Hardie J.M. 1994. Prevalence of *Eikenella corrodens* and *Actinobacillus actinomycetemcomitans* in the dental plaque of dogs. Vet. Rec. 14:519-520. - Allaker R.P., Young K.A., Langlois T., Rosayro R. & Hardie J.M. 1997. Dental plaque flora of the dog with reference to fastidious and anaerobic bacteria associated with bites. J. Vet. Dent. 14:127-130. - Ashimoto A., Chen C., Bakker I. & Slots J. 1996. Polymerase chain reaction detection of 8 putative periodontal pathogens in subgingival plaque of gingivitis and advanced periodontitis lesions. Oral Microbiol. Immunol. 11:266-273. - Avila-Campos M.J., Sacchi C.T., Whitney A.M., Steigerwalt A.G. & Mayer L.W. 1999. Arbitrarily primed-polymerase chain reaction for identification and epidemiologic subtyping of oral isolates of *Fusobacterium nucleatum*. J. Periodontol. 70:1202-1208. - Fives-Taylor P., Meyer D. & Mintz K. 1996. Virulence factors of the periodontopathogen *Actinobacillus actinomycetemcomitans*. J. Periodontol. 96:291-297. - Genco C.A. 1998. Animal models for *Porphyromonas gingivalis*-mediated periodontal disease. Trends Microbiol. 6:445-449. - Harvey C.E.,

Thornsberry C. & Miller B.R. 1995. Subgingival bacteria-comparison of culture results in dogs and cats with gingivitis. J. Vent. Dent. 12:147-150. - Harvey C.E. 1998. Periodontal disease in dogs: etiopathogenesis, prevalence, and significance. Vet. Clin. North Am. Small Anim. Pract. 28:1111-1128. - 17. Hennet P.R. & Harvey C.E. 1991. Anaerobes in periodontal disease in the dog: a review. J. Vet. Dent. 8:18-21. - Mättö J., Saarela M., Toil-Lindén B.von, Alaluusua S., Jousimies-Somer H. & Asikainen S. 1996. Similarity of salivary and subgingival *Prevotella intermedia* and *Prevotella nigrescens* isolates by arbitrarily primed polymerase chain reaction. Oral Microbiol Immunol. 11:395-401. - Moore W.E.C. & Moore L.V.H. 1994. The bacteria of periodontal diseases. Periodontol. 5:66-77. - Valdez M., Haines R., Riviere K.H., Riviere, G.R. & Thomas D. 2000. Isolation of oral spirochetes from dogs and cats and provisional identification using a polymerase chain reaction (PCR) analysis specific for human plaque *Treponema* spp. J. Vet. Dent. 17:23-26.

INDEX TERMS: Periodontal pathogens, periodontitis, dogs.

038. Valduga M.I.R.2007. **Study of incidency and prevalency of odontologic treatment in dogs and cats in a veterinary dental clinic**. *Pesquisa Veterinária Brasileira 27(Supl.).*

Brigadeiro Franco Street 419, Curitiba, PR 80430-210, Brazil. E- mail: atendimento@odontocao.com.br

Introduction: With the human urbanization (along with their pets) new necessities arose. Years ago dogs and cats lived outside the house in the backyard. Now it's common seeing pets living inside the houses with the approval of their owners. With this new reality, and with the new levels of services demanded by dog and cat owners, Veterinary Dentistry does a lot more than dental cleaning and extraction, using different techniques and discovering new specialties (Roman 1999). Trying to enhance the development of Veterinary Dentistry, the present work aimed to study the incidence of odontological procedures in dogs and cats and evaluate the prevalence of them at Odontocão - Veterinary Dentistry Center, Curitiba, PR, Brazil.

Materials and Methods: 1,291 dental cases that attended at Odontocão, from September, 1996 to February, 2004, were analyzed. All the cases were analyzed individually and a spreadsheet was filled with the kind of intervention was realized in which one. The total number of procedures were 1,852 (more than one procedure in the same pet in some cases). The classification is as follow:

- Preventive Orientation (good health pet; did not need any intervention, just physical exam and orientation about prevention and oral health.
- Profilatic procedure (oral cavity exam with the patient on monitored inhalatory anesthesia) ultra-sonic scaling, periodontal probing, polishing and application of a fluoride treatment.
- Exodontia (related to the periodontal treatment, deciduous persistent teeth or previously trauma).
- Periodontal treatment
- Endodontic treatment
- Dental restoration
- Caries
- Neck lesion in cats
- Feline Gingivitis stomatitis
- Cancer
- Orthodontia
- Acrylic resin - osteosynthesis

After estimating the prevalence of the less usual procedures they were arranged in a group named "other procedures". The data recovered with the studied material were analyzed according with the annual prevalence in the whole period (seven years and a half). It was extracted the average and the percentiles of incidence of each one of the treatments in the studied periods.

Results: It was found that periodonty had the greater prevalence (31.26%), followed by prophylaxis treatment (26.99%), exodontias (22.72%), preventive XXX (8.37%), endodontic therapy (2.21%), restoration (3.99%). Caries, neck lesion in cats, feline gingivitis stomatitis, cancer, orthodontia, acrylic resin-osteosynthesis, all together having 5.5% of the total.

Discussion and Conclusions: The study showed that the greater prevalency was in the periodontal cases. This result follows other studies of national (Gioso 1993, Valduga 1996, Valduga 1997, Apollo 2002) and international authors (Bojhab & Tholen 1989, Emily & Penman 1990, Harvey & Emily 1993, Tholen, Court et al. 1993, Thompson 1998, Debowes 1998, Román 1999). They all say that periodontal disease has the greater prevalence in adult dogs and cats. It is noted that after preventive orientation became to occur more frequently (after 2001), the prophylactic cases rose also. From 2002 on, prophylactic cases were greater than periodontal treatments. After 2002 periodontal treatments starts to slow down. It is supposed that could occurs an inter-relation between these data. A possibility is that clients that receive preventive instructions became aware of the situation and look for help in earlier phases of the diseases. Following this supposition could occur a rise in prophylactic cases and a reduction in periodontal ones. From 2001 on, preventive orientation rose significantly and stayed in that trend in the following years. It is supposed that the search for preventive orientation by clients were connected with some factors: better reasoning and pet life quality rising. In that context, Odontocão developed since its inception an oral health campaign with its clients connecting ir with pets life quality. The vets from Odontocão give orientation and diagnosis, demonstrating preventives treatments. Through quality products related to the pet problem, the client can take care of their pet at home, maximizing the treatment. A focused and specialized appointment and regular visits to the clinic allows better treatments and helping the ones that could only be controlled (as the periodontal disease). All these is reforced with speeches, talks to vets, pet shop owners and their staff and marketing materials. All the above actions follow Niemiec and Fiorito's direction on marketing in the 2002 Savannah Dental Veterinary Forum. Related to exodontia, the study shows that the majority of cases was due to periodontal disease progression, as other Brazilian studies also show (Valduga 1996, Valduga 1997, Appollo 2002). Caries, neck lesion in cats, feline gingivitis stomatitis, cancer, orthodontia and acrylic resin-osteosynthesis had lower prevalence in the study. It is supposed that they could occur at a higher level if the diagnosis had intense clinic signals

or by a routine exam of the oral cavity of pets every time they went to the vet. The majority of clients just shows, that the pet has a bad odor in the mouth, what means periodontitis. Unfortunately, if the patient had persistent deciduous teeth with bad occlusion it could be reversed if the diagnosis was done before. Exception to that are the caries case because they occurs in small scale due to anatomic and other reasons that is different from the human species (Román 1999).

References: Appollo F.H. 2002. Relatório de estágio curricular apresentado para conclusão de curso. Faculdade de Veterinária, UFRGS, Porto Alegre. - Bojhrab M.J. & Tholen M. 1989. Small Animal Oral Medicine and Surgery. Lea and Febiger, Philadelphia. - Debowes L.J. 1998. The effects of dental disease on systemis disease. Vet. Clin. North Am. Small Anim Pract. 28:1057-1062. - Emily P. & Penman S. 1990. Handbook of Small Animal Dentistry. 2nd ed. Pergamon Press, Oxford. - Gisoso, M.A. 1994. Odontologia Veterinária para o Clínico de Pequenos Animais. 3ª ed. I Editora, São Paulo. - Harvey C.E. & Emily P.P. 1993. Small Animal Dentristy. Mosby, St Louis. - Niemiec B.A. 2002. Extraction Techniques: AVDS foundation series. Proc.16th Annu. Vet. Dental Forum, Savannah, Georgia. - Román F.S. et al. 1999. Exodontia e cirurgia maxilofacial II, p.217-241. In: Román F.S. (ed.), Atlas de Odontologia de Pequenos Animais. Manole, São Paulo. – Valduga M.I.R. 1996. Relatório de estágio curricular apresentado para a conclusão de curso. Faculdade de Medicina Veterinária, UFPR, Curitiba, PR. - Valduga M.I.R. 1997. Casuística de um consultório odontológico na cidade de Curitiba, PR, no período de 13.6.96-18.9.97. Anais XIX Congr. Bras. Clín. Vet. Peq. Animais, Curitiba, Paraná.

INDEX TERMS: Veterinary dentistry, prevalence, incidence, dog.

039. Veiga G.A.L., D'Oliveira K.S., Barbosa A., Frignani J.F., Gumiero K., Vannucchi C.I. 2007.
Evaluation of the survival time of the dogs with oral neoplasms presented at Santo Amaro Veterinary University Hospital (UNISA) in the period of 2003-2006. *Pesquisa Veterinária Brasileira 27(Supl.*
Departamento de Cirurgia de Pequenos Animais, UNISA, São Paulo, SP 04829-320, Brazil. E-mail: gigveiga@ig.com.br

Introduction: The oral neoplasms represent about 6% of all tumors in dogs, being the oral cavity the fourth local of biggest incidence (Oakes et al. 1993). The biological behavior of the oral tumor depends on the species where it occurs, the localization in the oral cavity, the clinical period of training and the histopathologic nature of the tumor. The knowledge about the biological behavior of the tumor enables the physician selecting the best method of treatment and informing the owner correctly (Withrow 2001). The choice of the treatment is established being based on the clinical period of training and histopathologic nature of the tumor (Verstraet 2005). The surgical excision is the method most frequently indicated and more practical even for benign neoplasms as for the malignant ones (Oakes et al. 1993). The tumors of the oral cavity initially were treated by means of the surgical resection of the compromised soft tissue, remaining the bone unbroked. The fact that many tumors of the gengival or palatine surface are locally invasive, causing bone injury, resulted in many returns of the local treatment. Because of these results some tumors, as fibrosarcoma and the epulis that present invasive behavior but low incidence of metastasis, are ideal candidates for aggressive local therapy. Other tumors as the squamous cells carcinoma and the malignant melanoma, that present high incidence of metastasis, besides the aggressive local therapy must also be submitted to the local or systemic therapy for the control of metastasis (Harvey 1986). The surgical excision is the most effective and common treatment for the benign and malignant oral neoplasms in dogs (Salisbury et al. 1985, Penwick et al. 1986). In many cases the surgical aim is the cure of the patient, by means of the adjusted excision, free edges of tumor and absence of metastasis disease. If the extension of the disease makes this impossible, the palliative surgery can be carried through. The aim of the palliative surgery is not the cure of the patient but improve the quality of life by making local control. The third aim of the surgery is the removal of the tumor before other therapeutical modalities, as the radioactive therapy (Verstraet 2005). So, the aims of this study was to evaluate, retrospectively, the cases of oral neoplasms presented in Santo Amaro University (UNISA) Veterinary Hospital, determining the most frequent histopathological types of oral neoplasms, correlating the type of treatment used and the survival time in this population.

Materials and Methods: Fifty-four (54) animals with main diagnosis of neoplasia in the oral cavity had been presented during the period of January 2003 to January 2006. All animals were carried through general and specific anamnese. The aim of this anamnese was to obtain the clinical description, mainly the time of evolution and the main symptoms. The animals were also submitted to a complete clinical examination, being necessary in some cases the accomplishment of anaesthetics procedures for better evaluation of the oral cavity as well as for the accomplishment of complementary examinations as intra-oral, thoracic x-rays and incisional or excisional biopsy. The localization, size and aspect of the tumor in the oral cavity and the implication of regional lymph nodes as well as the results of the exams were registered in odontograms. The choice of the treatment was based on the evaluation of the radiographic images of the skull and lung, being a way to research the degree of the bone invasion as osteolysis or proliferation and the presence of metastasis, and in the histopathologic result. All the owners were contacted by telephone and were informed about their animals survival time (submitted or not under surgery).

Results: Fifty-four (54) animals had been taken care presenting oral neoplasms, but the accomplishment of the biopsy was only possible in 29 of the taken care patients, being 15 dogs submitted to the incisional biopsy and 14 dogs submitted to excisional biopsy. In the lasting animal (25 dogs) this procedure was not carried through because of the disagreement of the owners or in order to the evolution of the disease to pulmonary metastasis observed in the radiographic exam, and the option for euthanasia. The tumors of higher incidence were melanoma (26%), epulis (20%), fibrosarcoma (17%), papilloma (17%), squamous cell carcinoma (3%) and others (11%). From the 54 patients taken care only 11 were submitted under surgical procedure. The main reasons for not treating the animals by surgery were: evolution of the neoplasm for

non-operative (n=6), pulmonary occurrence of metastasis (n=3) and not agreement of the owner for the surgery because of financial reasons or his/her concern about the postoperative condition of the dogs (n=31). Referring to the adopted surgical procedure, the bilateral rostral mandibulectomy was chosen in two cases, total unilateral mandibulectomy in four cases, unilateral maxillectomy in one case, gingivectomy in two cases, glosectomy in one case and criosurgery in one case. The survival time of the animals (submitted or not under surgery) was of 1-12 months for the melanoma, of 8-22 months for fibrosarcoma and of 3-9 months for carcinoma. The improvement of quality of life and the increase of survival time for the animals, that had not operated malignant oral neoplasm and had had been submitted to the surgical procedure, when compared to the not operated ones, was up to 2 months for melanoma, up to 12 months for fibrosarcoma and up to 6 months for carcinoma. All animals with the diagnosis of benign neoplasm presented complete resolution of the affection, without the story of returns when surgically treated.

Discussion and Conclusions: The prognostic determines the survival time of the animal and is an important factor for the decision of the owner in realizing or not the treatment. The incidence of return for the malignant tumors after the surgical excision is frequent being, in these cases, indicated the euthanasia in 90% of the dogs with melanoma, 80% of the dogs with fibrosarcoma and 68% of the dogs with squamous cell carcinoma (Todoroff et al. 1979). The prognostic for the resolution of the epulis acanthomatosus with surgery and/or rhadiotherapy is excellent. The incidence of return of this tumor after aggressive ressection is 5% (Withrow 2001). In the same way, in the present study all the animals compromised by the excessively neoplasms epulis and benign ones had presented good prognostic after surgical resection, with no reincidence. On the other hand, the prognostic for the squamous cell carcinoma depends on the compromised area. Rostral tumors in dogs are curable through surgery or radiotherapy, while the carcinomas of tonsils or of the base of the tongue are highly metastasis and it has a local or regionally return (MacMillan et al., 1982). Melanoma is the tumor that presents the poorest prognostic (Todoroff et al. 1979). Bostock (1979), when analyzing the factors that potentially affect the prognostic of surgically treated dogs for the melanoma in several areas, including the mouth, demonstrated that the survival time can not have a correlation to the microscopical appearance or to the volume of the oral formation or the time of surgery. Harvey et al. (1981), in a retrospective study with surgically treated dogs for the melanoma, had concluded that the survival average time of the treated dogs was of 65 days, while the dogs submitted to the surgical resection survived in average 245 days. Those data are compatible to this study, which demonstrated that the survival time of the dogs with melanoma varied from 1 to 12 months, having the surgically treated dogs presented an increase of up to 2 months of life in relation to the not treated ones. Fibrosarcoma is locally invasive, so it must be treated with the combination of surgical excision with the radiotherapy for the increase of the animals‘ surviving time because the recurrence after the surgery is common and the tumor answers very little to the radiotherapy or even to the chemotherapy. The survival is inferior to one year, being some animals able to survive up to 2 years (Dhaliwal et al. 1998). The isolated surgical procedure of the other therapeutical modalities used in this study provided to the dogs with fibrosarcoma an excellent time of survival, up to 22 months, a similar result to the one described in literature. The surgical excision is still considered the therapeutical modality of choice even for benign neoplasms as for malignant ones, offering satisfactory results for the local and distant control of the tumor, besides improving the quality of life and increasing the survival time of the patient (Oakes 1993). In the present study, the dogs submitted to the surgical treatment for the malignant neoplasm cases presented increase of survival time and an acceptable quality life for their owners. On the other hand, the reluctance of the therapy of resection of the tumoral formation resulted on a low life expectancy, a fact that can be explained by the low degree of awareness of the owners of the taken care animals by UNISA Veterinary Hospital in relation to the importance of affections of the oral cavity and, therefore, not having awareness regarding oral neoplasms. The majority of the cases already demonstrated advanced signs of the disease presenting, many times, non-operative conditions (n = 6), pulmonary metastasis (n = 3), or the owners were opposed to the surgical treatment because of financial reasons or aversion against the deformity caused by the aggressive treatment (n = 31). So, the cure prognostic can be modified in agreement to the option for the surgical treatment. It can be concluded that the surgical excision is the praised and elected procedure for cases in which is not observed metastasis disease, because it provides the definitive resolution for the patients with benign neoplasms and greater survival time and better quality of life for patients with malignant neoplasms. It becomes more important that the owner must be known about the need of periodic evaluation of the oral cavity, so that oral neoplasm affections can be previously detected and, thus, provide the therapeutical success and preserve the buccal and general health of the dogs.

References: Bostock D.E. 1979. Prognosis after surgical excision of canine melanomas. Vet. Pathol. 16:32-40. - Dhaliwal R.S., Kitchell B.E. & Marreta S.M. 1998. Oral tumors in dogs and cats. Part II. Diagnosis and clinic signs. Comp. Cont. Educ. Pract. Vet. 20(10):1109-1120. - Harvey H.J., MacEwen E.G., Braun D. et al. 1981. Prognostic criteria for dogs with oral melanoma. J. Am. Vet. Med. Assoc.178:580. - Harvey C.E. 1986. Radical resection of maxillary and mandibular lesions. Vet. Clin. North Am. Small Anim. Pract. 16(5):983-993. - MacMillan R., Withrow S. J. & Gillete E.L. 1982. Surgery and regional irradiation for treatment of canine tonsilar squamous cell carcinoma: retrospective review of eight cases. J. Am. Anim. Hosp. Assoc. 18:311-314. - Oakes G.M., Lewis D.D., Hedlund C.S. et al. 1993. Canine oral neoplasia. Compend. Contin. Educ. Pract. Vet. 15(1):17-31. - Penwick R.C. & Nunamaker D.M. 1986. Rostral mandibulectomy: a treatment for oral neoplasia in the dog and cat. J. Am. Anim. Hosp. Assoc. 23:19-25. - Salisbury K.S., Thacker L. & Pantzer E.E. 1985. Partial maxillectomy in the dog comparison of suture materials and closure techniques. Vet. Surgery 14(4):265-276. - Todoroff R.J. & Brodey R.S.1979. Oral and pharyngeal neoplasia in the dog: a retrospective survey of 361 cases. J. Am. Vet. Med. Assoc. 175:567-571. - Verstraet F.J.M. 2005. Mandibulectomy and maxillectomy. Vet. Clin. Small Anim. Pract. 35:1009-1039. - Withrow S.J. 2001. Cancer of the oral cavity, p.305-17. In: Withrow S.J. & MacEwen E.G. (ed.), Small Animal Oncology. 3rd ed. W.B. Sauders Company LTDA.,Pensylvania, Philadelphia.

INDEX TERMS: Neoplasm, oral, surgery.

040. Veiga G.A.L., Barbosa A., D'Oliveira K.S., Frignani J.F., Gumiero K. & Vannucchi C.I. 2007. **Retrospective study of the oral neoplasms in dogs presented at Santo Amaro Veterinary University Hospital (UNISA) from 2003 to 2006.** *Pesquisa Veterinária Brasileira 27(Supl.).* Departamento de Cirurgia de Pequenos Animais, UNISA, São Paulo, SP 04829-320, Brazil. E-mail: gigveiga@ig.com.br

Introduction: The oral neoplasms represent about 6% of all tumors in dogs, being the oral cavity the 4th most common local of incidence (OAKES et al., 1993). A variety of neoplasms can occur in the oral cavity, such as odontogenics and non-odontogenics types of tumor (Verstraet 2005). The malignant melanoma, squamous cells carcinoma and fibrossarcoma are the most common malignant tumors of the oral cavity (Brodey 1970), which approximately represent 50% of the oral neoplasms in dogs (Richardson et al. 1983). Epulis is the most common benign oral neoplasm and represent about 25% of the oral neoplasms in dogs (Oakes et al., 1993). Those tumors arise in the oral mucosa, tongue, periodontum, jaw, odontogenic tissue, maxila and lip (Oakes et al. 1993). The caudal tumors are rarely noticed, however the patient will present signs and symptoms like weight loss, halitosis, sialorrhea (with or without blood), dysphasia and occasionally cervical lymphadenopaty (Withrow 2001). The diagnosis can be made by a minucious clinical examination of the oral cavity in a way that the tumor characteristics can be observed, such as: size, color, consistency, localization and extension of the injury (Dhaliwal 1998). But other diagnostic modalities are important to choose the best treatment and determine the patient's neoplasm prognostic. The radiographic exam is made to evaluate the extension of the neoplastic lesion and to search for metastatic disease. Aspiratory fine needle cytological exam can determine possible malignancy but only histopathological examination carried through incisional or excisional biopsy can confirm the diagnosis (Griffiths et al. 1984, Morrison et al. 1998, Verstraet 2005). The surgical treatment by techniques as mandibulectomy or maxilectomy is most commonly indicated to treat malign or benign oral tumors with local invasive injuries (Verstraet 2005). Although oral tumors represent a small portion of the many types of masses found in dogs, it is frequently observed that they present a fast clinical evolution, which limits the treatment plan of the veterinarian. When it is possible, surgical intervention is sometimes aggressive. Therefore, the aim of this study was evaluate, retrospectively, cases of oral neoplasms presented at Santo Amaro Veterinary University Hospital during the period of 2003-2006. A epidemiological profile of the patients was made including the most frequent histopathological types of oral neoplasms.

Materials and Methods: Fifty-four (54) animals with oral cavity neoplasm were studied from January 2003 to January 2006. These animals were from different sex, ages and breeds. All animals had been carried through general and specific anamneses, which included clinical description, highlighting the time of evolution and the main symptoms. The animals had been submitted to a complete clinical exam, which, in some cases, was performed under anesthesia to better evaluate the oral cavity, as well as accomplish complementary exams like intra-oral and thoracic radiographic studies and incisional or excisional biopsy. The location, size, aspect of oral tumor and regional lymph nodes, as well as the results of exams, were registered in odontograms. The treatment was based on histopathological results and on evaluation of radiographic images of the skull and lungs, which search for osteolysis or proliferative lesion of the compromised bone and presence of metastasis.

Results: Fifty-four (54) animals presented oral neoplasms being 35% of females and 65% of males. The dogs' age varied from 6 to 12 years old (51%), 13 to 20 years old (33%), 1 to 5 years old (9%) and dogs inferior to 1 year old (7%). The dogs of this study were mix breed dogs (n=21), Poodle breed dogs (n=6) and Cocker Spaniel breed dogs (n=5). The main owner's complain were: sialorrhea with or without blood, respiratory distress, halitosis, increase in jaw volume, anorexia and apathy, sneezing, nasal discharge, masticatory difficulty and weight loss. Only thirteen (13) animals did not present any of the symptoms cited above. Regarding topographical location of oral neoplasm, the mandible tumors had high incidence (41%), followed by maxillary tumors (22%), palate (15%), lip's mucosa (15%) and tongue (7%). Only twenty-nine (29) of the total patients had biopsy of lesion, being fifteen (15) dogs submitted to incisional biopsy and fourteen (14) dogs submitted to excisional biopsy, the remaining animals (25 dogs) did not have biopsy exams due to the owners' disagreement, option for euthanasia or because of pulmonary evolution to metastatic disease certified on radiographic exam. The higher incident tumors were melanoma (26%), epulis (20%), fibrosarcoma (17%), papiloma (17%), squamous cell carcinoma (3%) and others (11%). From the 54 presented patients only 11 were submitted to surgical procedure. The main reasons for not making surgery in some cases were: evolution of the neoplasia to inoperative stages (n=6), occurrence of pulmonary metastasis (n=3) and not agreement of the owner for the accomplishment of the surgery because of financial reasons or concern about the postoperative condition of the dogs (n=31). Prior to the surgical procedure, the animal was submitted to pre-operative laboratory exams and the owner was oriented to maintain the animal on food and water fasting before surgery. After pre-anesthetic medication, the animal was induced and intubated to propitiate inhalant maintenance during the procedure. The adopted surgical procedure was the accomplishment of bilateral rostral mandibulectomy in 2 cases, total unilateral mandibulectomy in 4 cases, unilateral maxillectomy in 1 case, gengivectomy in 2 cases, glosectomy in 1 case and criosurgery in 1 case. On postoperative care a broad range of antibiotic and analgesic medication (chloridrate of tramadol in the dose of 2mg/kg) were prescribed. Comissurorrhaphy was performed in the animals submitted to total unilateral mandibulectomy, being recommended the use of muzzle to prevent dehiscence of surgical wound. The use of anti-septic was also recommended in all animals, to perform oral hygiene on the first day after surgery. The first post-operative appointment was requested in 24 hours after the surgical procedure. All animals' appetite was normalized after the procedure and canned food was

offered. Complications as intense sialorrhea and tongue protrusion had been observed in animals submitted to mandibulectomy, however these alterations were normalized in a period of up to 8 days. Only one animal presented dehiscence at the surgical wound.

Discussion and Conclusions: Retrospective studies in oncology field allow the identification of some tumors characteristics as well as its biological behavior and factors that could potentially affect several treatments response, consisting in therapeutical challenge. The present study reports a variety of informations related to age, sex and breed predisposition of dogs with distinct neoplasms of the oral cavity associated to the histopathological type, which information was similar to other authors' data. The oral cavity is a complex structure, formed by different tissues; each one of them is able to originate various types of neoplasms, for this reason oral neoplasm presents different incidence and prognostics, according to its origin (HEAD, 1990). Among all malignant tumors the melanoma is the one of higher occurrence (30-40%), followed by squamous cell carcinoma (20-30%) and fibrosarcoma (10-20%) (Withrow 2001). On this study, the melanoma also was the malignant neoplasm of higher incidence (26%), however fibrosarcoma was the second most common malignant tumor (17%), followed by the squamous cells carcinoma (9%), in opposition to the data reported by other authors. This particular result can be explained because the aim of this study was the occurrence of oral neoplasm in dogs, and the squamous cells carcinoma has its highest occurrence in the feline specie. The males with age up to 6 years old are most affected than the females and some breeds like Poodle, Cocker, Boxer and Weimaraner seems to be predisposed (Cohen 1964), however some reports include other breeds such as the German Dogue, Pinscher and Rotweiler, besides the high incidence in mix breed dogs. The few incidence of pure breed dogs presented on this study can be explained by the location of the Veterinarian Hospital where this study was developed, a low income neighborhood, in which the mix breed dogs predominate. The neoplasms of the oral cavity depend on location, when they are located in a not viewable place they are rarely observed by owners on the initial stages of the disease. The patient presents signs and symptoms such as sialorrhea, pain or masticatory difficult, nasal discharge, weight loss, halitosis, oral bleed and lymphadenopaty of unknown cause (Oakes et al. 1993, Withrow 2001). It is important to mention that when the clinical signs become clear to the owners the mass has already have important physician-surgical evolution. For this reason, besides the signs and symptoms already cited on this study, some patients had been presented with metastatic disease, especially pulmonary (n = 3). The diagnostic suspicion depends on the general clinical examination of the patient and minucious exam of the oral formation (Dhaliwal et al. 1998). The intra-oral and extra-oral radiographic studies are important to determine the grade of bone invasion caused by invasive neoplasms (Verstraet 2005). The diagnostic confirmation is mainly carried through incisional or excisional biopsies, which offer subsidies for the histopathology exam (Morrison 1998). All animals on this study had been submitted to minucious clinical exam, however only 42 performed radiographic evaluation, and 29 allowed collection of samples to determine a definitive diagnosis. However, the importance of biopsy and methods of diagnostic image are standing out, so that it is possible to establish and adjust the treatment plan to each type of neoplasm in particular. So, the establishment of clinical behavior must include the accomplishment of the cited procedures of diagnosis. The treatment plan must be based on the alterations observed during the clinical evaluation of the oral cavity, joined with the results obtained after intra-oral and thoracic radiographic exams of metastasis research and on the histopathologic, determinative examination for the type of tumor and its prognostic. It has described in literature distinct therapeutical procedures, which can be carried through in association, depending on the histopathologic type of the tumor. The surgical excision is still chosen as a therapeutical modality even for benign neoplasms or for malignant neoplasma, offering satisfactory results for the local and distant control of the tumor, besides improving the quality of life and increasing the survival time of the patient (Oakes 1993). From the 54 animals taken care, only 11 had been submitted to the surgical treatment. This particularity can be attributed to the fact that most owners of the UNISA taken care animals present low degree of awareness in relation to the importance of the afections of oral cavity, therefore, not having concernment in relation to the oral neoplasms. In most cases dogs already demonstrated signs of advanced stages of the disease, not presenting conditions of being under a surgery (n = 6), metastasis pulmonary (n = 3), or the owners were opposed to the surgical treatment, for financial reasons or aversion to the deformity caused for the aggressive treatment (n = 31). Only three animals affected by oral papillomatosis had not been submitted to surgery, however they presented spontaneous resolution. The results of this study demonstrate that the most common oral neoplasms in dogs are the melanoma, epulis, fibrosarcoma and the squamous cell carcinoma. The mean age of the affected animals varies from 6 to 12 years old, being male dogs more predisposed and mix breed dogs the most compromised.

References: Brodey R.S. 1970. The biologica behavior of canine oral and pharyngeal neoplasm. J. Small. Anim. Pract. 11:45-53. - Cohen D.; Brodey R.S. & Chen S.M. 1964. Epidemiologic aspects of oral and pharyngeal neoplasms of the dog. Am. J. Vet. Res. 25:1776. - Dhaliwal R.S., Kitchell B.E. & Marreta S.M. 1998. Oral tumors in dogs and cats. Part I. Diagnosis and clinic signs. Comp. Cont. Educ. Pract. Vet. 20(9):1001-1024. - Griffiths G.L. et al. 1984. Fine needle aspiration cytology and histologic correlation in canine tumors. Vet. Clin. Pathol. 13(1): 13-7 - Head, K.W. 1990. Tumors of the alimentary tract, p.364-370. In: Moulton J.E. (ed.), Tumors in Domestic Animals. University of California Press, Berkeley. - Morison W.B., Hamilton T.A. & Hahn K.A. 1998. Diagnóstico de neoplasia. In: Slatter, D. (ed.), Manual de Cirurgia Veterinária. Manual de Cirurgia de Pequenos Animais. Vol.2. 1ª ed. 2830p. - Oakes G.M., Lewis D.D., Hedlund C.S. et al. 1993. Canine Oral Neoplasia. Compend. Contin. Educ. Pract. Vet. 15(1):17-31. - Richardson R.C., Jones M.H. & Elliot G.S. 1983. Oral neoplasm in the dog: a diagnostic and therapeutic dilemma. Compend. Contin. Educ. Pract. Vet. 5(6):441-446. - Verstraet F.J.M. 2005. Mandibulectomy and maxillectomy. Vet. Clin. Small Anim. Pract. 35:1009-1039. - Withrow S.J. 2001. Cancer of the oral cavity, p.718. In: Withrow,S.J., MacEwen E.G. 2001. Small Animal Oncology. 3rd ed.

INDEX TERMS: Neoplasm, oral, surgery.

041. Veiga G.A.L., D'Oliveira K.S., Barbosa A., Vannucchi C.I. 2007. **Squamous cell carcinoma of the tongue.** *Pesquisa Veterinária Brasileira 27(Supl.).* Departamento de Cirurgia de Pequenos Animais, UNISA, São Paulo, SP 04829-320, Brazil. E-mail: gigveiga@ig.com.br

Introduction: The squamous cell carcinoma of the tongue (SCC) is the second most common malignus tumor in dogs, like the melanoma and the fibrossarcoma, the prognostic is regarded to poor when it comes to survival time or lesion control (Todoroff et al. 1979). Sexual pre-disposition is not reported, however old age dogs of large breeds are most commonly affected. Many SCC arise from the gum, especially on the rostral mandible bone (Vestraet 2005). The SCC can be classified according to its origin as lingual, non-tonsil, and tonsil. The non-tonsil type is locally invasive, but has low rates of metastasis. The tonsil types are locally invasive, with fast progression and frequently metastasize to regional lymph nodes and lungs. Despite of being rare the lingual carcinoma is much more aggressive than the non-tonsil type having higher risk of metastases (Dhaliwal et al. 1998). The SCC may appear as a broad based, ulcerated mass, with slow growing rate and local bone invasion (Gioso 2003). The lesion could be found around apparently healthy teeth, causing dental mobility or pathologic fractures on the affected bone by direct contact, or it develops after dental loss or extraction (Dhaliwal et al. 1998). The aiming of the present study is to report 1 case of SCC of the tongue in one dog, because it is an oral tumor of rare incidence in small animals.

Case report: One 6 years old female cocker spaniel dog, was presented to the small animal surgery department of Santo Amaro Veterinary University Hospital (UNISA) with clinical history of weight loss, masticatory and deglutition difficulty, fetid oral cavity odor and sialorrhea with blood stripes. The physical exam showed an ulcerated, broad based formation on the rostral and middle portions of tongue, with no evident alterations on palpation of regional lymphnodes. A radiographic study of the thorax didn't show signs of metastatic lesions. The diagnostic of SCC was made by histophatological exam of the fragment collected by incisional biopsy of the lesion. After diagnostic, surgical procedure was suggested. Prior to surgery, the animal was submitted to pre-operative laboratory exams and the owner was oriented to maintain the animal on food and water fasting. After pre-anesthetic medication, the animal was induced and intubated to propitiate inhalant maintenance during the procedure.

Results: A partial glossectomy was made including the rostral and middle portion of the compromised tongue. The defect correction was made with absorptive suture wire by separated suture pattern. At the post-operative care antibiotics (cefalexin 30mg/kg/7days) and analgesics (sodic dipirone 25mg/kg/5 days and tramadol chloridate 2mg/kg/5days) were prescribed besides oral cleaning with anti-septic product (chlorexidine gluconate). The next day after surgery the animal received liquid diet with the owner's help. The recovery of masticatory and food prehension movements occurred in a progressive way. On the 5th day after surgery the patient was eating by himself. After 5 months of survival the patient presented recidivation of the lesion at the excision site associated to lung metastatic disease. Therefore euthanasia was indicated.

Discussion and Conclusion: The surgical excision is the most common and more effective treatment for benign and malign oral neoplasia in dogs (Salisbury et al. 1985, Penwick et al. 1986). Tumors like squamous cell carcinoma and malign melanoma, that present high rate of metastasis, must be submitted to regional or systemic therapy besides local aggressive treatment, aiming to control metastatic disease (Harvey 1986). The study reported by Carpenter et al. (1993) including 10 dogs which presented squamous cell carcinoma of the tongue, demonstrates that surgical resection of 40 to 60% of tongue extension is well tolerated by the animals. The surgical procedure propitiates a survival time of 16 months, and when associated to radiotherapy or chemotherapy the survival time increases to 27 to months. In the present study the surgical resection improved the quality of life from patients, propitiating masticatory, deglutition and life improvement. Other therapeutic modalities were not instituted due to the owner's aversion of procedures like chemotherapy for example. In conclusion surgical excision is the gold standard treatment to cases with no metastatic disease, because increases life quality and survival time for patients with malign neoplasia.

References: Carpenter L.G., Withrow S.J., Powers B.E. et al. 1993. Squamous cell carcinoma of the tongue in 10 dogs. J. Am. Anim. Hospital Assoc.29:17-23. - Dhaliwal R.S., Kitchell B.E. & Marreta S.M. 1998. Oral tumors in dogs and cats. Part I. Diagnosis and clinic signs. Comp. Cont. Educ. Pract. Vet. 20(9):1001-1024. - Gioso M.A. 2003. Odontologia para o Clínico de Pequenos Animais. 5ª ed. Editora I, SãoPaulo. 202p. - Todoroff R.J. & Brodey R.S. 1979. Oral and pharyngeal neoplasia in the dog: a retrospective survey of 361 cases. J. Am. Vet. Med. Assoc. 175:567-571. - Verstraet F.J.M. 2005. Mandibulectomy and maxillectomy. Vet. Clin. Small Anim. Pract. 35:1009-1039.

INDEX TERMS: Carcinoma, tongue, oral.

042. Veiga G.A.L., D'Oliveira K.S., Barbosa A. & Sanchez C. 2007. **Primary cleft palate**. *Pesquisa Veterinária Brasileira 27(Supl.):00-00.* Departamento de Cirurgia de Pequenos Animais, UNISA, São Paulo, SP 04829-320, Brazil. E-mail: gigveiga@ig.com.br

Introduction: The cleft palate is a congenital or aquired affection that attacks dogs and cats. The aquired cleft palate occurs mainly by traumatic lesions like bites laceration, fire guns, eletrict wire, severe cronic infeccions, surgery therapy, radiation, as like neoplasm process (Harvey 1987, Withrow 1996). The congenital cleft palate can be hereditary or can occur by alterations of embrionary development like hormonal and nutrition factor, toxic agents and viral infeccions intra-uterine (Nelson 1998). Different kinds of palate deffects was described as soft palate hypoplasia, the secondary cleft palate which is most common occurs in hard and/or soft palate, and the primary palate cleft which occurs on the lips and pre-

maxillary has a rare incidence (Harvey 1987, Sager 1998). The primary brachicephalics breeds are the most predisposed. The cleft diagnosis can be realized as birth through lips fissure evident, however, the secundary cleft palate could be missed until the neonate starts to show growing defincy signs. During the breast feeding, the milk drenage by neonate nostrils could be saw, cough, sneeze, choke and respiratory affections which could be observed in primary cleft palate (Nelson 1998). The surgery correction is the indicate treatment and a different technique has been described for this affection. The purpose of the present study is to describe the case of primary complete cleft palate for treating rare affection in small animals.

Case Report: A three years old male dog, Lhasa Apso, was presented to the small animal surgery department of Santo Amaro University Veterinary Hospital (UNISA) with a clinical history including anorexy and mastigatory dificulty, oral bleeding and nasal secretion. The physical exam showed an evidence of primary cleft palate associated with mucosa lip ulcer, a decorrent trauma caused by malloclusion inferior canine tooth in the cleft region. The surgery treatment correction and inferior canine dental section followed endodontic treatment was proposed, however due to financial problems the owner option was cleft correction and inferior canine exodontic. The animal was submited to pre-operative laboratory exams and the owner was oriented to maintain the animal on food and water fasting before surgical procedure. After pre-anaesthesic medication the animal was induced and intubated to propritiate inhalant maintenance during the procedure.

Results: First, it was realized in nasal floor mucoperiosteal flap elevation for the pre-maxillary cleft corretion. It was made nostril and lip incisions for flap obtations and lips cleft occlusion. The skin suture was realized with unabsorbable wire by separated pattern and the mucoses suture with absorptive wire separated. The inferior thooth canine exodontic was realized by the extra-alveolar technique. In the postoperative care it was prescribed antibiotic (cefalexine 30mg/kg), analgesic (chloridate tramadol 2mg/kg), bucal antiseptic and canned food. Ten days after surgery it was observed total oral mucosa and nostril scarred and absence of complications like secondary infections or deiscence stitches.

Discussion and Conclusions: Cleft palate surgery has been reported previously to be associated with a high rate of surgical failure, occurs mainly tension suture line (Griffiths 2001). The choice of the adjusted surgical technique, associate the factors as the type of wire of suture used in the procedure, the postoperative handling and the age of the animal at the moment of the defect correction are of extreme importance in the attainment of the therapeutical success (Harvey 1997). The use of lips remnants of relaxation had been essential to prevent the tension in the line suture and the perfect occlusion of cleft palate in the present report. The prognostic is good in the case of animals with primary palate cleft, however the accomplishment of some surgeries can be necessary, so that the defect is completely obliterated preventing the permanence of the symptoms (Kirby 1990). It is concluded that primary palate cleft presents favorable prognostic when treated exactly delayed, since the surgical correction is made in appropriate way.

References: Griffths L.G. & Sullivan M. 2001. Bilateal overlapping mucosal single-pedicle flaps for correction of soft palate defects. J. Am. Anim. Hosp. Assoc.37:183-186. - Harvey C.E. 1987. Palate defects in dogs and cats. Comp. Cont. Educ. Pract. Vet.9:404-418. - Kirby B.M. 1990. Oral flaps: principles, problem, and complications of flaps for reconstruction of the oral cavity. Problems in Veterinary Medicine: Reconstructive Surgery 2:494. - Neslon, A.W. 1998. Sistema respiratório superior, p.884-935. In: Slatter D.H. (ed.), Manual de Cirurgia de Pequenos Animais. Vol.1. Manole, São Paulo. - Sager M. & Nefen N. 1998. Use of buccal flaps for the correction of congenital soft palate defects in three dogs. Vet. Surgery, Davis, 27(4):358-363. - Withrow S.J. 1996. Tumors of the gastrointestinal system: cancer of the oral cavity, p.227-267. In: Withrow S.J. & MacEwen E.G. (ed.), Small Animal Clinical Oncology. Saunders, Philadelphia.

INDEX TERMS: Palate, cleft, surgery.

043. Witz M.I., Maia J.Z., Gonzáles R.R., Malschitzky E. & Alves LC. 2007. **Maxillary fracture with avulsion of incisors.** *Pesquia Veterinária Brasileira 27(Supl.).* Departamento de Clínica e Cirurgia, ULBRA, Canoas, RS 92425-900, Brazil. E-mail: witzmi@gmail.com

Introduction: Fractures of maxillary incisive bone or avulsion of incisors may not be visible without opening the mouth unless the teeth are drastically displaced (Pence 2002). The most obvious sign of maxillary fracture is malalignment of the incisors (Turner 1984).

Other signs of pre maxilla fracture are painful mouth behavior, difficulty in prehending and masticating food, excessive salivation and halitosis (Hague & Honnas 1998). These fractures can be difficult to stabilize because of limited space on the rostral fragment for placement of pins, or screws to lag fragments, or apply plates (Colahan & Pascoe 1983). After careful cleansing and debridement of food material and other debris, primary closure may be carried out if the surrounding tissue can be closed easily and has suitable strength for suture holding (Greet 1999). Inadequate fracture stabilization or alignment may lead to severe malocclusion and temporomandibular joint problems (Pence 2002). The type of restraint required to repair these fractures depends on the temperament of the horse (Hague & Honnas 1998).

Materials and Methods: An 8-month-old thoroughbred foal, weigthing 330 kg arrived at the hospital with a history of oral trauma. A dental exam was performed and a maxillary fracture with avulsion of incisors was observed. Xylazine (0.5 mg/kg) was used for sedation and after a mental nerve block was done with lidocaine 2%. The oral speculum for anterior teeth and dental healther were used for the procedure. The fracture area was rinsed with chlorexidine (0.12%) before reduction. The main objective was to achieve normal occlusion. Orthopedic wire of 1.0mm was utilized on the avulsion area. The same wire was passed below the contact point, brought to the buccal face and twisted. The buccal mucosa was sutured with simple interrupted suture with synthetic absorbablematerial. An intraoral methyl methacrylate was used to stabilize maxillary fracture and this material contured the cervical area. Flunexin meglumine was used and soft food was recommended. Pacient was to return after 60 days. After that the acrylic splint was removed. The animal had a normal occlusion and was able to eat.

Results: As a result of the maxillary reduction and acrylic splint the animal was able to eat and had a normal occlusion.

Discussion and Conclusions: It is important to detect this kind of fracture to enable the animal to feed normally therefore to improve his score condition and have a normal occlusion. Klug (2004) report the subsequent soft tissue injury that can result in a significant complications for the patient related to infections agents gaining access to the periodontium. The treatmnet employed in this case was realtively simple and non invasive.

References: Colahan P.T., Pascoe J.R. 1983. Stabilization of equine and bovine mandibular and maxillary fractures, using an acrylic splint. J. Am. Vet. Med. Assoc. 182:1117-1119. - Greet T.R.C. 1999. Oral and dental trauma, p.60-69. In: Baker G.J. & Easley J. (ed.), Equine Dentistry. Elsevier Saunders, Philadelphia. - Hague B.A.& Honnas C.H. 1998. Traumatic dental disease and soft tissue injuries of the oral cavity. Vet Clin. North Am. 14:333-347. - Klug D.O. 2004. Acrylic bite plane for treatment of malocclusion in a young horse. J. Vet. Dent. 21(2):84-87. - Pence P. 2002. Dental infections: pathology and treatment, p.209-230. In: Pence P. (ed.), Equine Dentistry: a practical guide. Lippincott, Philadelphia. - Turner A.S. 1984. Large animal orthopedics, p.893-897. In: Jennings P.B. (ed.), Practice of Large Animal Surgery. I. Saunders, Philadelphia.

INDEX TERMS: Equine dentistry, maxillary fracture, acrylic splint.